



## Case Report – Lipoma Arborescences

Authors

**Dr Abhay Agarwal, Dr Rohan Gala, Dr Siddhartha Yadav, Dr Prasad Chaudhari  
Dr Sanjay Dhar**

Dept of Orthopaedics, DY Patil School of Medicine, Navi Mumbai

Lipoma arborescens is a rare intra-articular lesion, characterised by diffuse replacement of the subsynovial tissue by mature fat cells, producing prominent villous transformation of the synovium. The aetiology of this benign condition is unknown.

A 19yr old male patient presented to us with 3 years history of swelling and pain in both knee joint with terminal restriction of flexion, aggravated on standing for long and relief on rest. He has no history of trauma, underlying joint disorder. Patient has been taking NSAIDS for symptomatic relief for past 6 months.

Physical examination revealed a swelling in the right and left supra patellar region, diffuse, soft in consistence, non adherent to the underlying bone, non pulsatile with tenderness over medial joint line on both knees (FIG-1). The range of motion was 0-120 in right knee and left knee full range of motion, with no evidence of ligament laxity. Blood test showed normal values and other lab reports were unremarkable. HLA B27 was negative, Anti nuclear antibodies by ELISA and

Anti Ds DNA antibody were in normal limits. Radiography showed normal joint line space and no degenerative changes (FIG-2). USG of swelling showed gross fluid collection with echogenic content through its lining. MRI was done which showed -Bilateral Suprapatellar bursal effusion with bilateral lipoma arborescences (FIG-3).

Diagnostic Arthroscopy was done for right knee with subtotal synovectomy. Sample was sent for histopathology which showed -Synovial lined with polypoidal tissue bits comprising of mature adipocytes separated by fibro vascular septae, fluid cytology showed predominant lymphocytes and few polymorphs, culture showed no growth for organisms.

Patient was immediately started on full range of motion and weight bearing as per pain tolerance. Recovery was uneventful and received NSAIDS and was relieved of his symptoms.

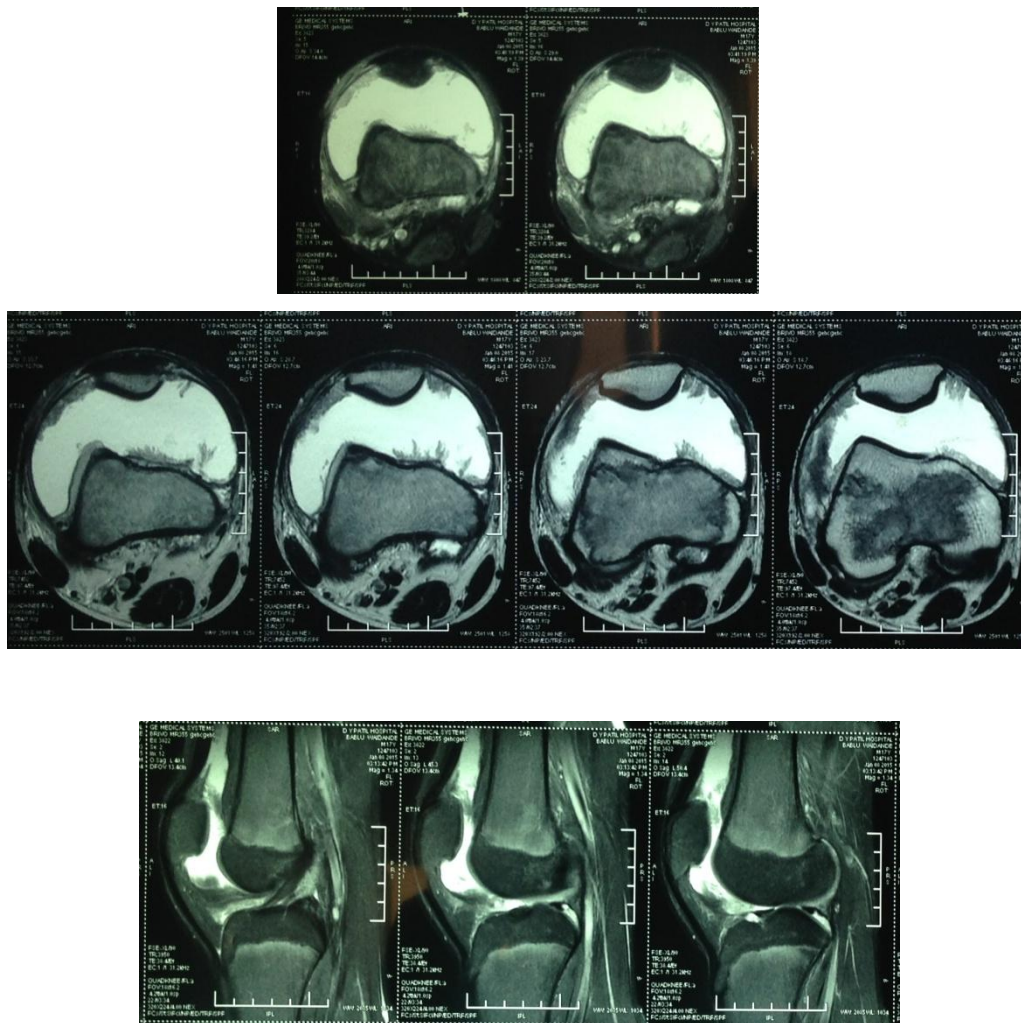
We are presenting this case as it is a very rare entity and it accounts for only 1% of all lipomatous lesions.

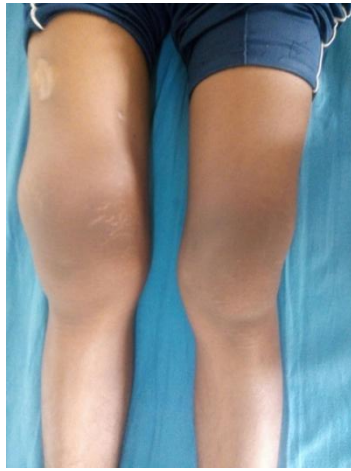

Fig-1

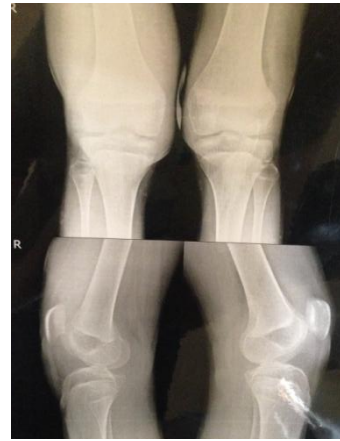

Fig-2



(Fig-3)

## References

1. Coventry, M.B., Harrison, E.G., Martin, J.F. Benign synovial tumors of the knee: a diagnostic problem. *J Bone Joint Surg.* 1966;48:1350–1466

2. Jaffe, H.L. Tumors and tumor condition of the bones and joints. Lea & Febiger, Philadelphia; 1958:574–575

3. Teusink, M., El-Khoury, G., Buckwalter, J. Lipoma arborescens of the subdeltoid

bursa: a case report. *The IOWA Orthop J.* 2010;30:177–178

4. Hubscher, O., Costanza, E., Elsner, B. Chronic monoarthritis due to lipoma arborescens. *J Rheumatol.* 1990;17:861–86
5. Martin, S., Hernández, L., Romero, J. et al, Diagnostic imaging of lipoma arborescens. *Skeletal Radiol.* 1998;27:325–329
6. Ikushima, K. Lipoma arborescens of the knee as a possible cause of osteoarthritis. *Orthopedics.* 2001;24:603–605
7. Blais, R.E., LaPrade, R.F., Chaljub, G. et al, The arthroscopic appearance of lipoma arborescens of the knee. *Arthroscopy.* 1995;11:623–627
8. Patil, P.B., Kamalapur, M.G., Joshi, S.K. et al, Lipoma arborescens of knee joint: role of imaging. *J Radiol Case Rep.* 2011; 5:17–25
9. Sung Yee Lee Sin Chuen YipWai Hong Yuen Department of Orthopaedics and Traumatology, Queen Elizabeth Hospital, Kowloon, Hong KongReceived: March 13, 2013; Received in revised form: August 21, 2013; Accepted: August 23, 2013; Published Online: October 31, 2014