

www.jmscr.igmpublication.org

Impact Factor 3.79

ISSN (e)-2347-176x



Journal Of Medical Science And Clinical Research

An Official Publication Of IGM Publication

Non traumatic Massive Subcutaneous Emphysema in a Baby (Case Report)

Authors

Dr. Nirmal Bhaskar¹, Dr. K.Sudha Bhanu², Dr. Nandakumaran.T.K³

Department of Paediatric Surgery, Government Medical College Thrissur, Kerala -680596

Corresponding Author

Dr. Nirmal Bhaskar

Nirmallya House, Gayathri Avenue, Koorkenchery.P.O, Thrissur, Kerala-680007

Email: unni321@gmail.com

ABSTRACT

Subcutaneous emphysema is a condition in which air is trapped in the layer under the skin. A 1½ year old boy presented in our casualty with history of violent cough followed by bloating up of baby. The whole baby was covered by massive subcutaneous emphysema from scalp to foot. No respiratory distress. X ray/ Babygram showed massive subcutaneous emphysema extending from scalp to foot. But no pneumothorax or pneumomediastinum. Baby was managed conservatively with oxygen inhalation without ICD tube. Extensive subcutaneous emphysema can be managed conservatively without intercostal drainage tube, if there is no respiratory distress. Administering oxygen may help the body to absorb the subcutaneous air more quickly.

Keywords- *Subcutaneous Emphysema, Pneumothorax, intercostal drainage, respiratory distress, breathing oxygen.*

INTRODUCTION

Subcutaneous emphysema is a condition in which air is trapped in the layer under the skin. Since the air generally comes from the chest cavity, subcutaneous emphysema usually occurs on the

chest, neck and face, where it is able to travel from the chest cavity along the fascia.^[1] Subcutaneous emphysema has a characteristic crackling feel to the touch, a sensation known as subcutaneous crepitation.

Subcutaneous emphysema usually results from puncture of parts of the respiratory or gastrointestinal systems.

Particularly in the chest and neck, air may become trapped as a result of penetrating trauma.

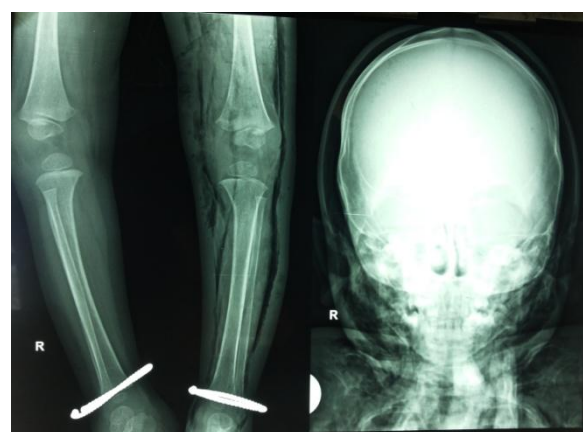
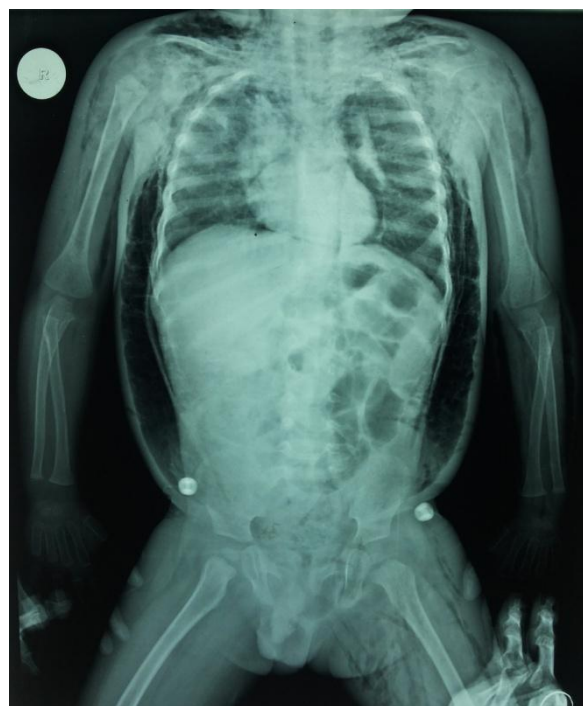Subcutaneous emphysema can be caused by medical procedures and medical conditions that cause the pressure in the alveoli of the lung to be higher than that in the tissues outside.^[2] It can also occur spontaneously due to rupture of the alveoli with a dramatic presentation.^[3]

Subcutaneous emphysema is not typically dangerous by itself; however it can be a symptom of very dangerous underlying conditions, such as pneumothorax.^[4] Usually subcutaneous emphysema does not need treatment; however, if the amount of air is large, it can interfere with breathing and be uncomfortable.^[5] In severe cases of subcutaneous emphysema, catheters can be placed in the subcutaneous tissue to release the air.^[1] Small cuts, or "blow holes", may be made in the skin to release the gas.^[6] When subcutaneous emphysema occurs due to pneumothorax, a chest tube is frequently used. Breathing oxygen may help the body to absorb the subcutaneous air more quickly.^[7]

CASE REPORT

A 1½ year old boy presented in our casualty with history of violent cough followed by bloating up of baby. History of asthma present. On examination the whole baby was covered by massive subcutaneous emphysema from scalp to foot. As if baby is kept in a AIR FILLED BALLOON. No respiratory distress. X ray/ Baby gram showed massive subcutaneous emphysema extending from

scalp to foot. But no pnuemothorax or pneumomediastinum. Baby was managed conservatively with oxygen inhalation without intercostals drainage tube. Baby was better and discharged within a week.



DISCUSSION

Usually extensive subcutaneous emphysema is produced by traumatic cause. In our case extensive surgical emphysema was produced without a trauma. Regarding management, even though

extensive subcutaneous emphysema present, the baby can be managed conservatively without intercostal drainage tube, if there is no respiratory distress. Intercostal drainage tube is needed only when there is presence of pneumothorax. Breathing oxygen may help the body to absorb the subcutaneous air more quickly.

REFERENCES

1. Papiris SA, Roussos C (2004). "Pleural disease in the intensive care unit". In Bouros D. Pleural Disease (Lung Biology in Health and Disease). New York, N.Y: Marcel Dekker. pp. 771–777. ISBN 0-8247-4027-0. Retrieved 2008-05-16.
2. Maunder RJ, Pierson DJ, Hudson LD (July 1984). "Subcutaneous and mediastinal emphysema. Pathophysiology, diagnosis, and management". *Arch. Intern. Med.* 144 (7): 1447–53. doi:10.1001/archinte.144.7.1447. PMID 6375617.
3. Parker GS, Mosborg DA, Foley RW, Stiernberg CM (September 1990). "Spontaneous cervical and mediastinal emphysema". *Laryngoscope* 100(9): 938–940. doi:10.1288/00005537-199009000-00005. PMID 2395401.
4. Brooks DR (1998). *Current Review of Minimally Invasive Surgery*. Philadelphia: Current Medicine. p. 36. ISBN 0-387-983384.
5. Abu-Omar Y, Catarino PA (February 2002) "Progressive subcutaneous emphysema and respiratory arrest". *Journal of the Royal Society of Medicine* 95(2): 90–91. doi:10.1258/jrsm.95.2.90. PMC 1279319 .PMID 11823553.
6. Grathwohl KW, Miller S (2004). "Anesthetic implications of minimally invasive urological surgery". In Bonnett R, Moore RG, Bishoff JT, Loenig S, Docimo SG. *Minimally Invasive Urological Surgery*. London: Taylor & Francis Group. p. 105. ISBN 1-84184-170-6. Retrieved 2008-05-11.
7. NOAA (1991). *NOAA Diving Manual*. US Dept. of Commerce – National Oceanic and Atmospheric Administration. p. 3.15 ISBN 0-16-035939-2. Retrieved 2008-05-09.