www.jmscr.igmpublication.org

Impact Factor 3.79
Index Copernicus Value: 5.88
ISSN (e)-2347-176x ISSN (p) 2455-0450
crossref DOI: http://dx.doi.org/10.18535/jmscr/v3i12.09

IGM Publication
Journal Of Medical Science And Clinical Research
An Official Publication Of IGM Publication

Comparative Analysis on the Functional Outcome Following Internal Fixation of Midshaft Clavicle Fractures with Plate against Titanium Elastic Nail

Authors

M.Chandrasekaran[1], Ravichandran Subbaraj[2], Vineet T A[3]

[1,2,3]Consultant Orthopaedic Surgeons, Department of Orthopaedics
Mahatma Gandhi Medical College and Research Institute, Pondicherry, India 607402

Corresponding Author

M.Chandrasekaran

Consultant Orthopaedic Surgeon, Department of Orthopaedics, Mahatma Gandhi Medical College and Research Institute, Pondicherry, India 607402

Email ID: *chandruortho@yahoo.com, chandrasekaranm@mgmcri.ac.in*

Abstract:

Introduction: *Injuries around the shoulder resulting in clavicle fractures accounts for about 5% to 10% of all the fractures. When we consider the shoulder girdle injuries alone, clavicle fractures accounts for about 50% of all the shoulder injuries. It still is a debate whether to treat conservatively or by means of internal fixation.*

Objectives: *Our objective was to compare the functional outcome of internal fixation of displaced midclavicular fractures treated by plating and titanium elastic nailing technique by retrospective analysis.*

Materials and method: *72 patients who had displaced midclavicular fractures and undergone internal fixation with either by plating or TENS at our institute (Mahatma Gandhi Medical College and research institute) from 2012 January to 2015 January were included and divided into two groups and the results were compared.*

Results: *Analysis was done comparing the functional outcome based on age, type of fracture, fracture healing time, implant related complications and ASES, Quick DASH. Both groups had good union at the fracture with no delayed or non-union. TENs group had the advantage of shorter operative time, less blood loss, minimal scar, very few implant related complications. Long term results were comparable in both the groups.*

Conclusion: *Our retrospective comparative analysis of internal fixation of displaced mid-third clavicle fractures by plating and TENs shows that long term results are comparable in both the groups though TENs group had the advantage of shorter operative time, less blood loss, minimal scar, very few implant related complications.*

Keywords: *clavicle fractures, titanium elastic nail system (TENs), plating, American shoulder and elbow surgeon score (ASES), Quick DASH (Disabilities of the Arm Shoulder and Hand)*

Introduction

Injuries around the shoulder resulting in clavicle fractures accounts for about 5% to 10% of all the fractures.[1] When we consider the shoulder girdle injuries alone, clavicle fractures accounts for about 50% of all the shoulder injuries.[2] This means that clavicle fractures are the commonest shoulder girdle injury. The most common site for the fracture is the mid third or the junction of mid third to lateral third of clavicle.[3]It still is a debate whether to treat conservatively or by means of internal fixation, though the literature is more in favor of non operative treatment for the majority of the midshaft clavicle fractures. With ever demanding patients need to return to work at the earliest, patients demand internal fixation. When we decide to go for internal fixation, various surgical options are available and can broadly be classified into intramedullary and extramedullary fixation. Here we had analyzed the results of plate osteosynthesis in comparison with titanium elastic stable nail (TENS).

Materials and Method

Retrospective study involving 72 patients who had displaced midclavicular fractures and undergone internal fixation with either by plating or TENS at our institute from 2012 January to 2015 January were included. They were divided into two groups with group A involving plate osteosynthesis and group B involving TENS osteosynthesis. The inclusion criteria were as follows: age between 20 to 50 years, displaced midclavicular fractures with significant displacement (overriding or superior displacement of >2 cm) at the fracture site, acute fractures presenting within a week period following trauma. The exclusion criteria were all undisplaced fractures, medial and lateral end clavicle fractures, pathological fractures, fractures presenting more than 3 weeks following trauma, associated ipsilateral bony injuries (e.g. Scapula fracture, floating shoulder, humerus or forearm bone fractures). Of the 72 patients who fulfilled the above criteria and had follow up till the fracture union were included and 4o patients had undergone plate osteosynthesis and 32 patients had TENS fixation. Patients had undergone internal fixation according to the surgeons preferred method of fixation.

Results

Results were analyzed in terms of age, sex, mode of injury, type of clavicle fracture and side of involvement, radiological union and ASES and Quick DASH scores.

In the plate osteosynthesis group (A) the average age was 28 years with the range of 22 to 48 years, and in group B the average age was 26 years with the range of 20 to 46 years. There were no significant differences among the age in both the groups. Men were dominating in both the group accounting for 85% (61 patients) and remaining 11 patients were female.

Most common mechanism of injury was found to be road traffic accidents accounting for 85% (61 patients) suggesting direct injury in these patients. Remaining 11 patients had fall on outstretched hand and sustained facture. Of the 72 patients 47 had comminution of more than one third circumference (Robinson Type II B2) and remaining 25patients had less than one third comminution (Robinson Type II B1). Of the 42 comminuted fractures 29 patients had more than one fragment at the fracture site.

Radiological union was assessed with serial follow up x-rays in both the groups at 6 weeks, 12 weeks, 18weeks and 24 weeks. Any visible facture line with minimal or no callus at the end of 24 months with or without implant failure was considered as non union. All the 72 fractures had union at the end of 24 weeks follow up. In the TENS group one The average time for fracture healing was about 12 weeks with the range between 10 and 16 weeks in the TENS group and the average time of fracture healing in the plate group was 18 weeks with the range between 12 to 22 weeks. ASES and Quick DASH scoring was done at the time of 12 weeks postop was found to be lower than plating group the reason being adventitious bursitis due to prominent nail at the

medial end of clavicle. After nail removal at the time of 4 to 6 months both the groups had similar ASES and Quick DASH scores. The advantage of TENS over plating was shorter operating time range being 30 to 45 minute compared to plating technique which required an average of 70 minutes with the range being 60 minutes to 90 minutes almost double the duration of TENS group. In 18 out of 32 patients in the TENS group underwent closed reduction and the remaining patients had mini open reduction to pass the nail across the fracture site by which the operative duration was very much shortened with less soft tissue dissection which probably another reason for shorter healing time.

Table: 1 Summarizes details of two groups

S.NO	characteristics		Group A (PLATING)	Group B (TENS)
1	Number of Pts		40	32
	Age - range		22-48	20 - 46
	Mechanism of injury		RTA – 36 patients	RTA - 25 patients
	Fracture type	Robinson Type II B1	13	12
		Robinson Type II B2	25	22
	ASES	12 weeks - average	85	80
		24 weeks - average	98.3	98.3
	Quick DASH	12 weeks - average	10.2	12.3
		24 weeks - average	0	0
	Fracture Healing time in weeks		12 to 22	10 to 14
	Operative time		60 to 90 minutes	30 to 45 minutes

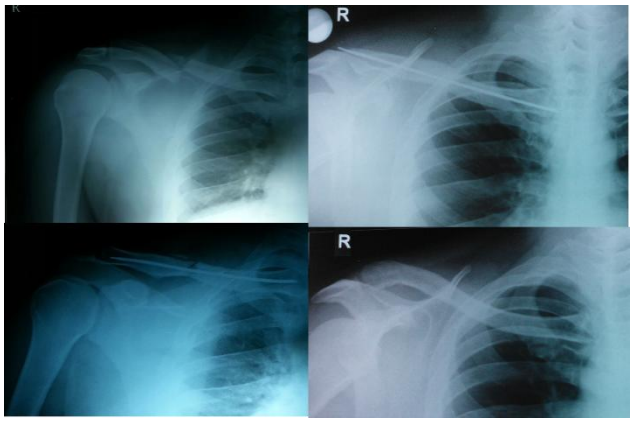

Figure 1 showing fracture clavicle treated with TENs healed well and implant removed

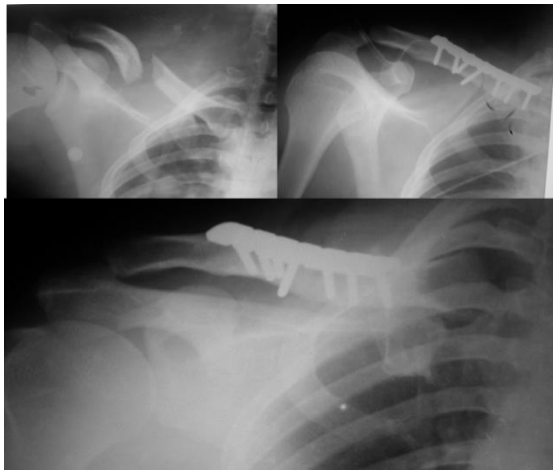

Figure 2 showing fracture clavicle treated with plating and healed well

Complications

In group A one patient had plate bending which was seen at 6 weeks postoperatively and was within acceptable limit; hence it was managed conservatively by the treating surgeon. One patient had early surgical site infection which required wound irrigation and antibiotics for four weeks with which infection settled uneventfully. In group B one female patient had nail breakage at 6 weeks postop following repeated trauma and reported at around 10 weeks by the time fracture was uniting satisfactorily with minimal angulation at the fracture site. Another patient had deep wound infection at 6 weeks postoperatively for which patient had undergone wound debridement with early implant removal at 10 weeks as the fracture showed union at that point despite of wound infection. Patient was treated with antibiotics for a period of 6 weeks (two weeks parenteral and four weeks oral) following which wound healed uneventfully. 8 out of 32 patients in group B had superficial adventitious bursitis at the Medial end of clavicle where the TENS nail was left prominent subcutaneously which was causing irritation and local inflammatory changes. This bursitis was managed with non-steroidal anti-inflammatory drugs and ice fomentation in all the cases. This also caused night pain in 6 patients in group B resulting in reduced ASES and Quick DASH scores.

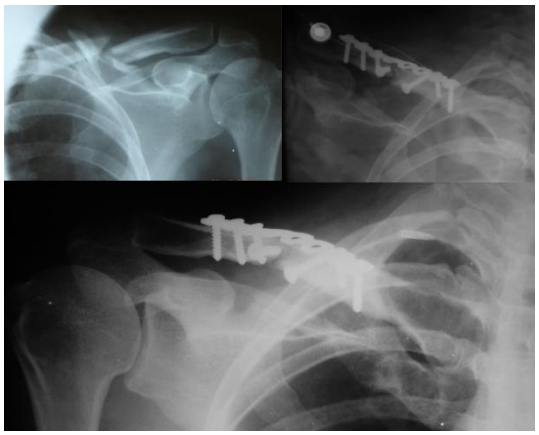

Figure 3 showing healed fracture despite of bent plate postoperatively

Discussion

In a multicentric randomized clinical trial conducted by the Canadian orthopaedic trauma society comparing non operative treatment with plate fixation for displaced midshaft clavicular fractures concluded that operative treatment gives better results in displaced midshaft clavicle fractures.[4] In a review article written in the year 2009 by Kashif khan et al about the fractures of the clavicle concluded that non operative treatment of displaced clavicle fractures may be associated with a higher rate of non union and functional deficits than previously reported.[5] A meta analysis by Zhang et al comparing plate fixation versus intramedullary fixation for the treatment of mid-shaft clavicle fractures concluded that intramedullary fixation had the advantage over plate fixation by reduced operative time, blood loss, scar, infection and better functional outcome at 6 months though long term results were equal.[6]In another systematic review by Houwert, concluded that there is evidence that functional outcomes are not influenced by the method of surgical treatment of displaced midshaft clavicle fractures, plate fixation or intramedullary fixation.[7] In our series all our patients had uneventful healing of fracture though in group B healing was earlier than group A. This may be due to less soft tissue dissection, less rigid fixation in group B. Though there was better ASES, Quick DASH in group A at 12 weeks it became equal in both the groups suggesting no significance during the long term followup. Regarding the post op rehabilitation, patients in group B had faster recovery than group A, though at 24 weeks no significant difference interms of range of movements between the two groups. One significant point to consider is that whenever comminution at the fracture site was severe (no cortical continuity) all these patients were treated by plating rather than TENS. This could be a weakness in our study as the outcome of TENs in severe comminuted clavicle fractures could not be assessed. Another issue is that in group B (TENs) all patients underwent nail removal approximately

at around 4 to 6 months period and there were no refractures reported whereas in group A (Plating) we did not have any implant removal, hence we could not assess the risk of refractures which is one of the well known complication in the plating technique.[8] Our results are comparable to that of Liu et al[9] except for the significant difference in operative duration and Nidhi Narsaria et al.[10]

Conclusion

Our retrospective comparative analysis of internal fixation of displaced mid-third clavicle fractures by plating and TENs shows that long term results are comparable in both the groups though TENs group had the advantage of shorter operative time, less blood loss, minimal scar, very few implant related complications.

References

1. Pope R. Clavicle fracture management onservative versus operative. J Bone Joint Surg(Br) 2002:84-B Suppl III: 214.
2. Postacchini F, Gumina S, De Santis P, Albo F Epidemiology of clavicle fractures. J Shoulder Elbow Surg (2002) 11:452 – 456
3. Van der Meijden OA, Gaskill TR, Millett PJ. Treatment of clavicle fractures: current concepts review. J Shoulder Elbow Surg. 2012;21(3):423-9
4. Michael D. McKee, Hans J. Kreder, Scott Mandel, Nonoperative Treatment Compared with Plate Fixation of Displaced Midshaft Clavicular Fractures. A Multicenter, Randomized Clinical Trial J Bone Joint Surg Am, 2007 Jan; 89 (1): 1 -10 . http://dx.doi.org/10.2106/JBJS.F.00020
5. L.A. Kashif Khan, Timothy J. Bradnock, Caroline Scott and C. Michael Robinson Fractures of the Clavicle J Bone Joint Surg Am. 2009;91:447-460. doi:10.2106/JBJS.H.00034.
6. Bing Zhang, Yanbin Zhu, Fei Zhang, Wei Chen, Ye Tian and Yingze Zhang, Meta-analysis of plate fixation versus intramedullary fixation for the treatment of mid-shaft clavicle fractures, Scandinavian Journal of Trauma, Resuscitation and Emergency Medicine (2015) 23:27 DOI 10.1186/s13049-015-0108-0.
7. R. Marijn Houwert, Frans-Jasper Wijdicks, Charlotte Steins Bisschop, Egbert-Jan Verleisdonk, MoyoKruyt. Plate fixation versus intramedullary fixation for displaced mid-shaft clavicle fractures: a systematic review; International Orthopaedics (SICOT) (2012) 36:579–585 DOI 10.1007/s00264-011-1422-4
8. Frans-Jasper G. Wijdicks, Olivier A. J. Van der Meijden, Peter J. Millett, Egbert J. M. M. Verleisdonk, R. Marijn Houwert Systematic review of the complications of plate fixation of clavicle fractures. Arch Orthop Trauma Surg. 2012 May; 132(5): 617–625.
9. Liu HH, Chang CH, Chia WT, Chen CH, Tarng YW, Wong CY. Comparison of plates versus intramedullary nails for fixation of displaced midshaft clavicular fractures. J Trauma. 2010;69(6):E82–E87.
10. Nidhi Narsaria, Ashutosh K. Singh, G. R. Arun, R. R. S. Seth Surgical fixation of displaced midshaft clavicle fractures: elastic intramedullary nailing versus precontoured plating. J OrthopTraumatol. 2014 Sep; 15(3): 165–171.