

www.jmscr.igmpublication.org

Impact Factor 3.79  
ISSN (e)-2347-176x



**Journal Of Medical Science And Clinical Research**

An Official Publication Of IGM Publication

## **Malignant Ascites as the First Sign of Breast Cancer – Two Case Reports and Review of Literature**

Authors

**Sanghamitra Jena<sup>1</sup>, Arnab Gupta<sup>2</sup>**

<sup>1</sup>DNB Trainee, Department of Surgical Oncology, Saroj Gupta Cancer Centre and Research Institute, MG Road, Thakurpukur, Kolkata, India – 700063.

<sup>2</sup>Consultant, Department of Surgical Oncology, Saroj Gupta Cancer Centre and Research Institute, MG Road, Thakurpukur, Kolkata, India – 700063.

Email: arnabgupta1@hotmail.com

Corresponding Author

**Sanghamitra Jena**

DNB Trainee, Department of Surgical Oncology, Saroj Gupta Cancer Centre and Research Institute, MG Road, Thakurpukur, Kolkata, India – 700063.

Email: docsalu@gmail.com

### **ABSTRACT**

*Breast cancer is the most commonly occurring female cancer in the world. It usually presents as a painless lump in the breast or axilla, change in the position or shape of the nipple or nipple inversion, skin puckering or dimpling, a rash on or around a nipple or discharge from nipple/s. Case of breast cancer presenting as malignant ascites is very rare which usually occurs in ovarian and GI malignancies. Very few cases of lobular carcinoma breast have been reported to present with gastrointestinal and peritoneal metastases. This incidence is even lower in ductal carcinoma breast and the prognosis is very unfavourable. Herein we report two patients who presented with malignant ascites and on investigation were found to have ductal carcinoma of breast as the primary. They were treated with chemotherapy and hormonal therapy. First case died after two years of diagnosis and second case is surviving till date.*

**Keywords-** Breast cancer, malignant ascites.

## INTRODUCTION

Breast cancer is the most commonly occurring female cancer in the world with an age-standardized incidence rate (ASR) of 39.0 per 100,000 [1,2]. Breast cancer accounts for 23% of all newly occurring cancers in women worldwide and represents 13.7% of all cancer deaths [1]. It usually presents as a painless lump in the breast or axilla, change in the position or shape of the nipple or nipple inversion, skin puckering or dimpling, a rash on or around a nipple or discharge from nipple/s. Metastatic breast cancer presents with symptoms that depend on the location of metastasis. Common sites of metastasis include bone, liver, lung and brain [3]. Case of breast cancer presenting as malignant ascites is very rare. Very few cases of lobular carcinoma breast have been reported to present with gastrointestinal and peritoneal metastases. This incidence is even lower in ductal carcinoma breast [4]. Herein we report two patients who presented with malignant ascites and on investigation were found to have ductal carcinoma of breast as the primary. They were treated with chemotherapy and hormonal therapy. First case died after two years and second case is surviving till date.

## CASE REPORTS

### Case 1:

A 55year old woman presented on July 2011 with a four week history of abdominal distension and decreased appetite. She was non-diabetic, non-hypertensive and was not addicted to smoking and

alcohol. On thorough clinical examination, the abdomen was distended with fluid thrill. A hard mass of size 2cm × 2cm was found in the retro-areolar region of left breast with nipple retraction. It was free from deeper structures. No abnormality was detected in per-vaginal or per-rectal examination.

Trucut biopsy of breast lesion showed moderately differentiated ductal carcinoma. ER (estrogen receptor), PR (progesterone receptor) were positive and and her 2-neu was negative. CECT of abdomen and pelvis detected no abnormality other than ascites. Therapeutic and diagnostic paracentesis were performed. Cytology of ascitic fluid was positive for metastatic adenocarcinoma. Laparoscopic assessment did not reveal any peritoneal deposits.

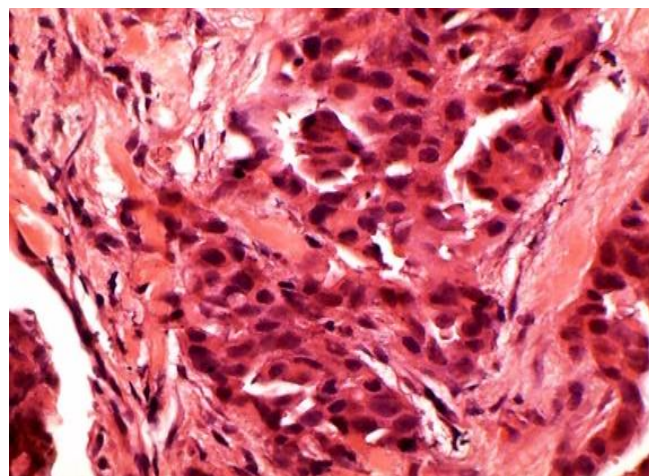
After excluding ovarian and GI malignancies and assuming the breast lesion to be the primary of malignant ascites, treatment was started with chemotherapy (Paclitaxel and Carboplatin). There was no ascites clinically and radiologically and only a residual lesion found in the left breast after six cycles of chemotherapy. After one month of completion of chemotherapy she was prescribed Tamoxifen. For six months she was completely asymptomatic, after which she again presented with ascites. Hormonal therapy was omitted and she was put on second line chemotherapy with Xeloda (capecitabine). She completed six cycles of Xeloda during which breast lesion was static and ascites subsided. After one month she again presented with ascites. She was given Gemcitabine and Cisplatin as next line of

treatment, but she developed nephrotoxicity after first cycle and it was stopped. Then she was switched over to Cyclophosphamide, Mesna and Doxorubicin. She completed six cycles of chemotherapy. Two months later, she again presented with ascites and died.

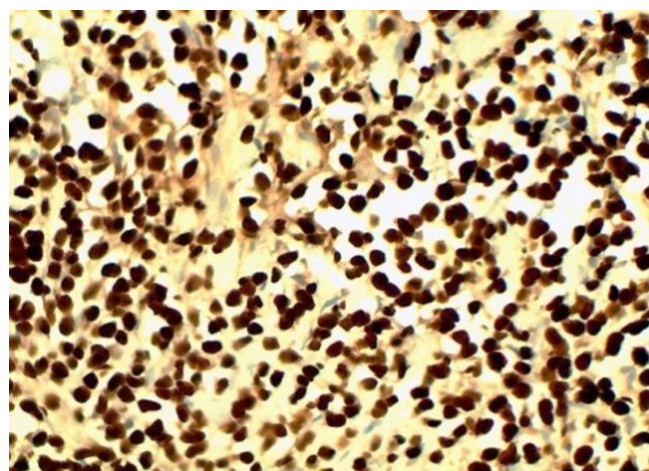
### Case 2:

A 58 year old female presented on March 2012 with six week history of abdominal distension. She was a known diabetic and hypertensive on medications. The abdomen was distended with bulging flanks. There was fluid thrill. On examination of breast, a hard lump of size 1.5cm × 1.5cm was found in lower inner quadrant of left breast. There was no lymphadenopathy in axilla and neck. Gynaecological examination was normal.

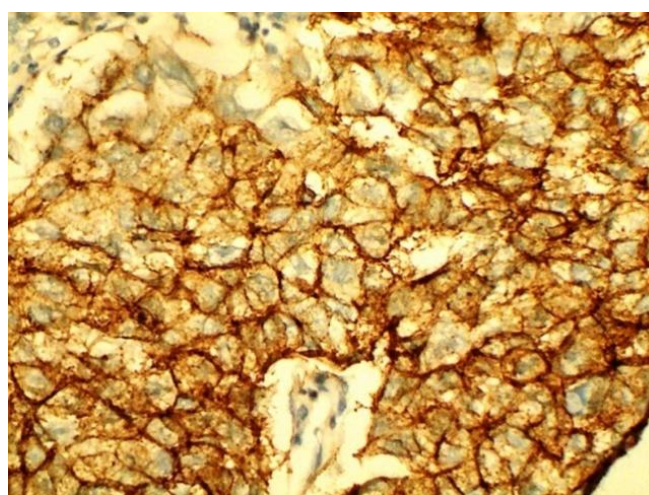
Routine blood examinations were within normal limits. FNAC of breast lesion showed ductal carcinoma. Trucut biopsy of the breast lesion revealed duct carcinoma [Figure 1] and immunohisto chemistry showed that ER was positive [Figure 2a ], PR was negative and Her-2-neu was positive [Figure 2b]. Mammography showed a dense mass in infero-medial quadrant of left breast [Figure 3]. CA 15-3 was 192 U/ml (normal <30). Upper GI endoscopy and colonoscopy were within normal limits. USG and CECT abdomen revealed ascites. Cytology of ascitic fluid was positive for metastatic adenocarcinoma [Figure 4]. Laparoscopy did not reveal any peritoneal deposits.



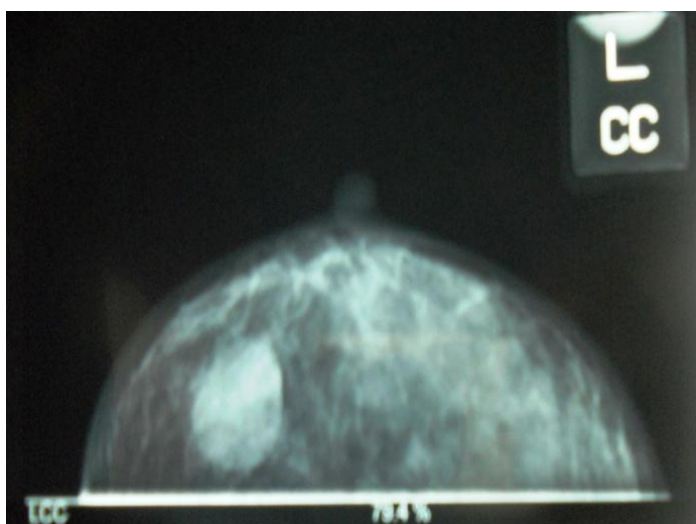
**Figure 1.** Left breast Trucut biopsy sample (haematoxylin-eosin stain 40 x)



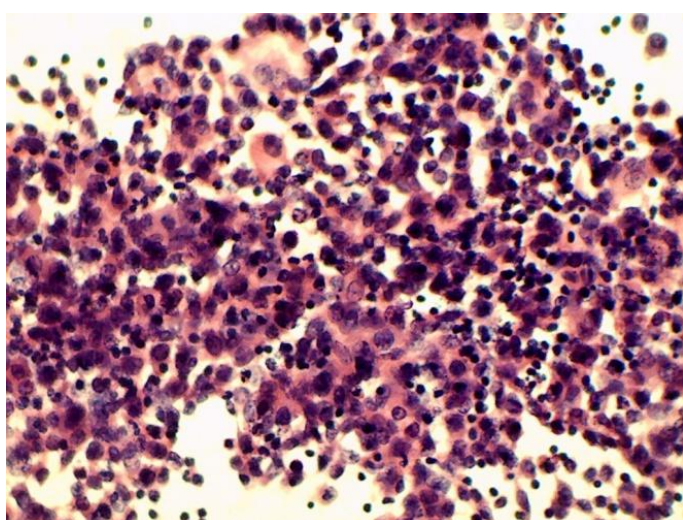
**Figure 2a.** Tumor cells positive for ER



**Figure 2b.** Tumor cells positive for Her-2-neu



**Figure 3.** Mammography of left breast



**Figure 4.** Cytology of ascitic fluid (haematoxylin-eosin stain 40 x)

Chemotherapy with Epirubicin, Cyclophosphamide and 5-FU was started. There was no ascites after 6 cycles of chemotherapy and breast lesion also disappeared. She was put on Anastrozole but Transtuzumab could not be started because of financial constraints. She was asymptomatic for 7 months after which she presented with ascites. Second line chemotherapy with Docetaxel monotherapy was started, but ascites did not subside. She was put on third line

CT with Gemcitabine and Carboplatin to which she responded. After six cycles, there was no ascites and breast lesion was static. She is under regular follow-up and asymptomatic till date.

## DISCUSSION

Breast carcinoma, the most common cancer affecting women, accounts for approximately 32% of cancers in women and carries a lifetime risk of 1 in 10 [5]. Advanced (metastatic) breast cancer includes a cancer that, at first diagnosis, has spread to distant organs from the original site of the tumour (approximately 5-10% of all patients). Most frequently, metastatic breast cancer spreads locally to the lymph nodes, and distant metastases concern the liver, lungs, bones, and more rarely the CNS. There are very few cases reported where malignant ascites is the presenting symptom [6]. Parsons et al. carried out a 2-year retrospective review over a decade ago in which they showed that ovarian cancer was the commonest cause of ascites with far better prognosis than patients with GI cancers. In a 2-year review carried out by AA Ayantunde and SL Parsons at Nottingham University Hospitals, ovarian cancer had the highest proportion of patients who developed ascites at 37.7% followed by pancreaticobiliary cancers 21%, gastric cancer 18.3%, oesophageal cancer 4.0%, colorectal cancer 3.7 and breast cancer 3.0% [7]. In this report we discussed about two patients in which ovarian and GI malignancies were excluded by investigations and breast cancer was found to be the primary of malignant ascites.

Ascites is a non-specific clinical manifestation of breast cancer. Peritoneal metastases of breast cancers are often recognized years after the initial diagnosis, there are few cases in the literature who show the metastases at the time of the initial diagnosis [8]. Also, metastases of breast cancer into the alimentary tract and/or peritoneum are not frequent. In autopsy examinations, metastases to peritoneum or the alimentary tract were observed in 8-32% patients, while in the retrospective study by McLemore et al. their occurrence was rare [9]. Nevertheless, metastases to the peritoneum or the alimentary tract were found in no more than 1% of patients with metastatic breast cancer, as a late symptom of cancerous disease. The most frequent sites of metastases in the alimentary tract were the colon and rectum (45%), followed by the stomach (28%), small intestine (19%), and oesophagus (8%). Lobular carcinoma was the type of cancer which most often metastasized to the above-mentioned organs (64%). Invasive ductal cancers that account for 75% of the breast cancers usually metastasize to the lungs and pleura. However, it has been reported that ductal type and medullary type breast cancers, although rarely, are likely to metastasize to the gastrointestinal system [10]. The presence of peritoneal metastases of breast cancer generally indicates lobular invasive carcinoma, in contrast, our patient were diagnosed with invasive ductal carcinoma.

Tuthill et al. [11] confirmed that in patients with metastases to the peritoneum the prognosis is very unfavourable. The main treatment for peritoneal metastasis of breast cancer involves the

intervention for the ascites and palliative chemotherapy [12]. Usually in such cases, no cure is possible, treatment is palliative, and the median survival time is approximately 18-24 months [13,14]. But in this case report, with chemotherapy and hormonal therapy, one patient survived for two years and the second patient is under follow-up after more than two years of diagnosis.

In conclusion, although breast cancer is a systemic disease that may spread anywhere in the body, peritoneal metastasis develops only in advanced stage. Initial presentation of breast cancer with malignant ascites is very rare. In the patients presenting with the complaints of abdominal pain and ascites, metastasis of the breast cancer should be considered. It often originates from lobular carcinoma, however, invasive ductal carcinoma should also be considered. Even though the prognosis is poor, chemotherapy and hormonal therapy can be treatment options to prolong the survival.

#### **DECLARATION**

The patient has given her informed consent regarding publication of her case.

#### **CONFLICT OF INTEREST**

The authors declare that there is no conflict of interests regarding the publication of this article.

#### **REFERENCES**

1. Ferlay J, Shin HR, Bray F, Forman D, Mathers C and Parkin DM. GLOBOCAN

- 2008 v2.0, Cancer Incidence and Mortality Worldwide: IARC CancerBase No. 10 [Internet]. Lyon, France: International Agency for Research on Cancer; 2010. Available from: <http://globocan.iarc.fr>, accessed on 08/12/2013.
2. IARC World Cancer Report 2008 2008: IARC.
  3. Atalay C, Yilmaz KB, Altınok M. Laryngeal metastases in breast cancer. *Meme Sag Der* 2006; 2: 139- 140.
  4. Winston CB, Hadar O, Teitcher JB, et al. Metastatic lobular carcinoma of the breast: patterns of spread in the chest, abdomen, and pelvis on CT. *AJR Am J Roentgenol* 2000;175:795-800.
  5. Rubin P: Clinical oncology, 7th ed, pp 187-211, WB Saunders Co, Philadelphia, 1993.
  6. Jaros AW Niedzia EK, Pawe Kiciński and et al. Ascites as the first sign of breast cancer –case report. *Journal of Pre-Clinical and Clinical Research*, 2012, Vol 6, No 1, 54-56.
  7. Ayantunde AA and Parsons SL. Pattern and prognostic factors in patients with malignant ascites: a retrospective study. *Ann Oncol*. 2007 May;18(5):945-9.
  8. Law WL, Chu KW. Scirrhus colonic metastasis from ductal carcinoma of the breast: report of a case. *Dis Colon Rectum* 2003; 46:1424-1427.
  9. McLemore E, Pockaj B, Reynolds C, et al. Breast cancer: presentation and intervention in women with gastrointestinal metastasis and carcinomatosis. *Ann Surg Oncol*. 2005; 12(11): 886-894.
  10. Kobayashi T, Adachi S, Matsuda Y, Tominaga S. A Case of Metastatic Lobular Breast Carcinoma with Detection of the Primary Tumor after Ten Years. *Breast Cancer* 2007;14:333-336.
  11. Tuthill M, Guiliani R, Pell R, Lim A, Gudi M, et al. Peritoneal disease in breast cancer: a specific entity with an extremely poor prognosis. *Eur J Cancer*. 2009; 45(12): 2146-2149.
  12. Deraco M, Casali P, Inglese MG, Baratti D, Pennacchioli E, Bertulli R, et al. Peritoneal mesothelioma treated by induction chemotherapy, cytoreductive surgery, and intraperitoneal hyperthermic perfusion. *J Surg Oncol Jul* 2003;3:147-153.
  13. Jassem J, Krzakowski M (ed.). *Rak piersi. Praktyczny przewodnik dla lekarzy. (Breast cancer. A practical guide for physicians)*. Via Medica, Gdańsk 2009; 1-13 (in Polish).
  14. Krzakowski M et al. (Eds.). *Zalecenia postępowania diagnostycznoterapeutycznego w nowotworach złośliwych. (Guidelines for diagnosis and therapy of malignant tumors)*. Vol. I. Via Medica, Gdańsk 2011; pp 197 (in Polish).