



Primary Actinomycotic Mycetoma of the Hand and Wrist- A Case Report

Authors

Meera Balakrishnan¹, Radhika Nalliah², V. Sridevi³, C.S.Vijayalakshmi⁴

^{1,2,3}Assistant Professor in Pathology, Sree Muthukumaran Medical College Hospital & Research Institute, Chikkarayapuram, Mangadu, Chennai-600069

⁴Professor & HOD in Pathology, Sree Muthukumaran Medical College Hospital & Research Institute, Chikkarayapuram, Mangadu, Chennai-600069

Email-drmeerab@yahoo.com, radhika.nalliah@gmail.com, drsridevi78@yahoo.co.in, vijaylux2003@gmail.com

Corresponding Author

Meera Balakrishnan

Assistant Professor in Pathology, Sree Muthukumaran Medical College Hospital & Research Institute, Chikkarayapuram, Mangadu, Chennai-600069

ABSTRACT

Mycetoma is a chronic suppurative granulomatous disorder of subcutaneous tissues characterized by localized swellings with multiple sinus tracts discharging granules. It is a chronic infection, frequently seen in tropical and sub-tropical countries and is considered as an occupational disease. An accurate diagnosis is generally obtained by clinical and histological examination. We report a case of actinomycotic mycetoma of the hand for its rarity.

Keywords- Actinomycosis, Wrist joint, Biopsy.

INTRODUCTION

Mycetoma is a chronic suppurative granulomatous disorder that may be caused by either actinomycetes (actinomycotic mycetoma) or true fungi (eumycetoma). It was initially described by John Gill in 1842 and named it 'Madura foot' after the region of Madurai in India, where it was first

identified [3]. The foot is most commonly affected. It is an indolent, slowly progressive infection that colonizes the mouth, colon and vagina. Mucosal disruption leads to infection and small abscesses and pus filled sinus tracts are formed from which pus containing colonies of organisms called sulphur granules are discharged. Actinomycosis has a peak

incidence in the middle decade with three-fold higher incidence in males¹. The common sites of infection are cervicofacial, thoracic, abdominal, primary cutaneous and pelvic. Wrist joint with hand is a rare site of involvement and is being reported. We report a case of actinomycotic mycetoma of the Wrist joint with hand for its rarity.

CASE REPORT

A previously healthy 50-year-old male patient presented with multiple nodular lesions and swelling of right wrist and hand and of 6 years duration. The lesions started as a single painless nodule over the flexor aspect of right wrist and hand and within a period of 6 months progressed to form multiple nodules with seropurulent discharge. Past history was nothing significant, no history of trauma or injury to the hand, non-diabetic, non-hypertensive and not suffering from tuberculosis. Examination revealed multiple erythematous nodules with discharging sinuses over the flexor aspect of right wrist and hand with induration and swelling (Figure 1). The mobility of the hand was not restricted. The examination of discharge and the scraping of the sinuses did not reveal any granules. Haematological, biochemistry and urine analysis reports were within normal limits. Mantoux test was negative and chest X-ray was normal. X ray of the right hand showed soft tissue swelling around the right wrist joint and no bony involvement (Figure 2). FNAC done on the wrist joint showed scattered histiocytes, occasional multinucleated giant cells in a necrotic background. A biopsy was taken from a representative nodule and sent for histopathological examination. Histopathological examination

revealed bits of fibrous connective tissue with a tract covered by granulation tissue, which focally showed a pale blue colony with surrounding Splendor -Hoepli reaction and numerous acute on chronic inflammatory cells suggestive of mycetoma (Figure 3). Gram stain was performed on tissue section and found positive whereas AFB turned out to be negative.

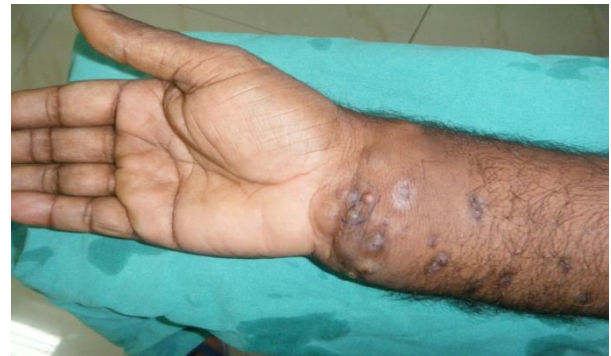

Fig. 1 Photograph of lesion.

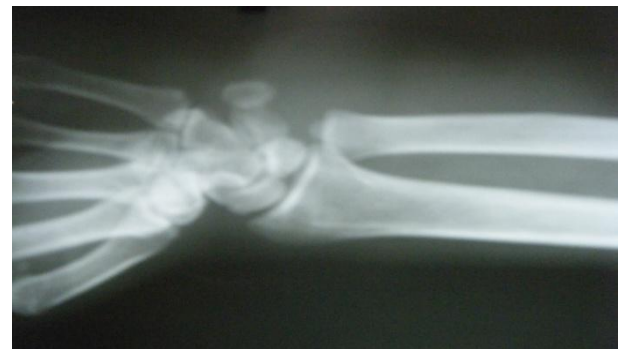

Fig.2 Radiograph of the right wrist joint showing no bony involvement.

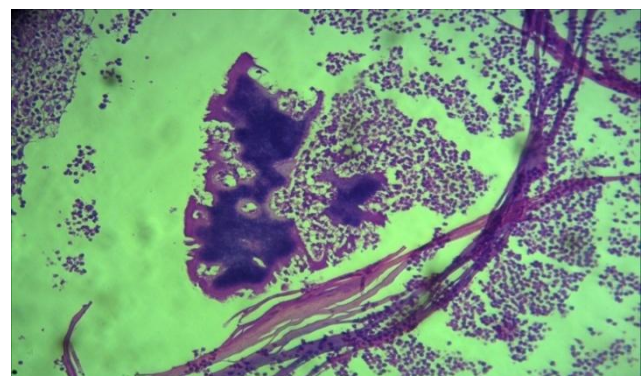


Fig.3. Actinomycetoma neutrophilic infiltrate surrounding the actinomycotic colony. (H&E 40x)

DISCUSSION

Actinomycetomas are caused by aerobic Actinomycetes belonging to the genera *Nocardia*, *Streptomyces* and *Actinomadura*. Mycetoma typically presents in agricultural workers or in individuals who walk barefoot in dry, dusty conditions. Minor trauma allows pathogens to enter the skin from the soil. Although reported from all over the world, they are common in tropical and subtropical regions[3]. In India, actinomycotic mycetoma is more commonly encountered than eumycotic mycetoma. However, the latter account for most of the cases reported from northern India. Nocardiosis is a rare localized or systemic infection caused by several species of the genus *Nocardia*. This genus consists of strictly aerobic, Gram-positive, variably acid-fast, filamentous bacteria with a tendency to fragment into bacillary and coccoid forms. The most common resulting skin lesions are on the lower extremities. Cutaneous manifestations include mycetoma, lymphocutaneous (sporotrichoid) infection, superficial skin infection and disseminated infection with cutaneous involvement [2]. *Nocardia brasiliensis* although rarely implicated in pulmonary and disseminated infections in immunocompromised patients, has been most commonly associated with cutaneous infections [3]. The main differential diagnoses are chronic bacterial osteomyelitis, tuberculosis, or the early phase of Buruli ulcer. Other deep fungal infections such as blastomycosis or coccidioidomycosis and also leishmaniasis, yaws and syphilis should be considered. Differentiation between actinomycetoma and eumycetoma is important because of the different responses to

treatment. Surgical debridement, followed by prolonged appropriate antibiotic therapy for several months is required for actinomycetoma, wherein a combination therapy with trimethoprim-sulfamethoxazole, dapsone and streptomycin has been used along with Rifampicin for resistant cases.[1] Eumycetomas are only partially responsive to anti-fungal therapy but can be treated by surgery due to their normally well circumscribed nature. Surgery in combination with azole treatment is the recommended regime for small eumycetoma lesions in the extremities.[1]

CONCLUSION

Prognostically, actinomycetoma should be distinguished from eumycetoma as the treatment varies. Actinomycetoma can be cured with surgical debridement and appropriate antibiotic therapy while eumycetoma is only partially responsive to antifungal agents, has high rate of recurrence and may require amputation. This emphasizes the need for its correct diagnosis after meticulous clinical examination, assisted by histological studies along with the use of special stains.

REFERENCES

1. Kiran Alam, Veena Maheshwari and Ershad ul Haq Histological Diagnosis of Madura Foot (Mycetoma): A Must for Definitive Treatment . J Glob Infect Dis. 2009 Jan-Jun; 1(1): 64–67.
2. Mert A, Bilir M, Bahar H, Torun M, Tabak F, Ozturk R, Ozaras R, Aktuglu Y. Primary Actinomycosis of the Hand: A Case Report

- and Literature Review. Int J Infect Dis. 2001;5(2):112-4.
3. Sumati Hogade, Metgud S C, Swooroparani. Actinomycetes Mycetoma. Journal of Laboratory Physicians / Jan-Jun 2011 / Vol-3 / Issue-1
 4. Kundu, Zile Singh; Singh, Raj; Rana, Parveen; Bala, Renu; Actinomycosis Of Hand And Wrist: A Case Report. Internet Journal of Orthopedic Surgery;2007, Vol. 5 Issue 1, p1
 5. Sharma N, Mendiratta V, Sharma RC, Hemal U, Verma M. Pulse therapy with amikacin and dapsone for the treatment of actinomycotic foot: A case report. J Dermatol. 2003; 30: 742-7.
 6. Mercur D, Tita C, Ianosi G, Ianosi S, Tita M. Madura's foot (mycetoma) Chirurgia.2003;98:261
4. [[PubMed](#)].