

[www.jmscr.igmpublication.org](http://www.jmscr.igmpublication.org)

Impact Factor 1.1147

ISSN (e)-2347-176x



Journal Of Medical Science And Clinical Research

IGM Publication

An Official Publication Of IGM Publication

## Pelvic Ewing's Sarcoma Presenting with Adnexal Mass in an Adolescent Girl- A Case Report

Authors

**N Biswas<sup>1</sup>, G Mukhopadhyay<sup>2</sup>**

<sup>1</sup>RMO-Clinical Tutor, <sup>2</sup>Associate Professor, Dept. of Gynae & Obs, North Bengal Medical College & Hospital, Darjeeling, West Bengal.

Correspondence Author

**Dr. N. Biswas**

RMO-Clinical Tutor

E-mail: [dr.nandita82@rediffmail.com](mailto:dr.nandita82@rediffmail.com)

### Abstract

*Adnexal masses are frequently observed finding in women attending gynecological OPD. An adnexal mass may be found in females of all ages- infants to elderly. The reported prevalence varies widely depending upon the population studied and criteria employed. Anatomically the adnexa consist of the ovaries, fallopian tubes, broad ligament, and the structures within the broad ligament. The adnexal mass most frequently involves the ovaries. Benign functional cysts of ovaries like follicular cyst, corpus luteal cyst, theca leutin cyst and polycystic ovaries may present with adnexal mass. Endometriomas, benign and malignant ovarian tumors are other ovarian causes of adnexal SOL. The mass may arise from the tubes and the uterus also. In certain instances, the mass is clinically indeterminate and may be due to nongynecological causes when arising from the bladder, bowel abdominal wall or retroperitoneum. Adnexal masses may be symptomatic or discovered incidentally during a routine pelvic examination in an asymptomatic patient. The correct diagnosis of the mass is of immense importance to decide upon the mode of treatment. Here we present a case of pelvic Ewing's Sarcoma presenting with a big adnexal SOL in an adolescent girl where preoperative correct diagnosis could modify the mode of therapy she was given*

**Key words:**-- Adnexal mass, Adolescent, Bone tumor, Pelvis, Ewing's Sarcoma.

## INTRODUCTION

Adnexal mass is one of the common findings we get in women attending the gynaecological OPD. The differential diagnosis varies with age. Age is also the most important factor in determining the potential for malignancy. Adnexal mass most frequently involves the ovary itself because of its propensity for neoplasia[1]. It may also arise from the fallopian tubes, uterus, bowel, abdominal wall or other adjacent structures. It may be the presentation of a tubo-ovarian abscess, hydrosalpinx, paratubal cyst, ectopic pregnancy. Bowel related mass like distended colon with gas or feces, appendicitis, diverticulitis, diverticular abscess, colon cancer may present with adnexal mass. Even distended bladder, abdominal wall haematoma or abscess, pelvic kidney, retroperitoneal neoplasm may be misdiagnosed as arising from the adnexa. The correct diagnosis of adnexal mass is thus complex because of the wide spectrum of disorders that it encompasses and the numerous therapies that may be appropriate.

The majority of patients present with symptoms related to compression of the local pelvic organs due to the adnexal mass. Less commonly, such a mass is discovered during an abdominopelvic examination in an asymptomatic patient or during routine ultrasound. The evaluation of a woman with a

suspected adnexal mass consists of a detailed clinical history and physical examination including abdominal, pelvic and rectovaginal examination. However physical examination is often inaccurate in determining the correct nature of an adnexal mass-whether it is benign or malignant.

Pelvic ultrasound is currently the most useful technique for diagnostic evaluation of the adnexal mass. Transvaginal ultrasound gives better resolution than abdominal ultrasound[2]. In general CT Scan is not indicated routinely for the evaluation of adnexal mass.

However, it is indicated in the evaluation of a patient with a hard fixed lateralized mass, ascites, abnormal liver function tests or where there is strong suspicion of malignancy. CT in these cases can provide important information regarding spread and resectability of the disease. MRI is also useful in further evaluation of adnexal masses detected by ultrasound and characterized as 'indeterminate' in nature. It may rule out pelvic bone involvement by the disease process in suspected cases.

The most useful laboratory studies in the evaluation of adnexal masses are complete blood count with differential count, quantitative  $\beta$ -hCG and in selected cases, tumor markers. Serum tumor markers like Lactate Dehydrogenase,  $\alpha$ -Fetoprotein,  $\beta$ -hCG should be obtained in the young females

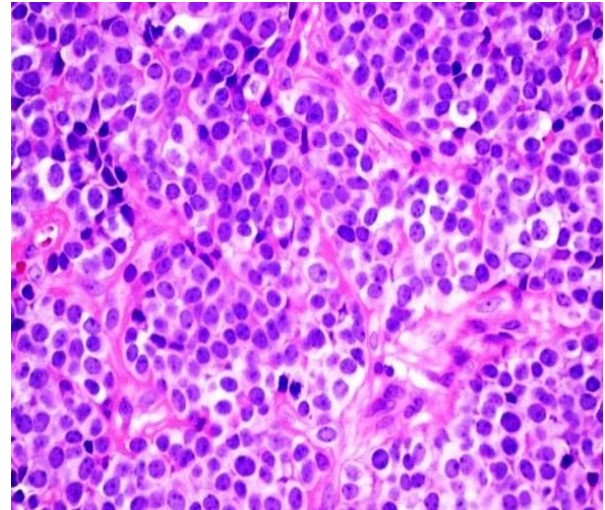
with solid-cystic or solid adnexal mass to evaluate the risk of germ cell tumor. Serum CA-125 and CEA values should also be obtained in patients with suspected gynecological and gastrointestinal tumors, respectively. Lastly FNAC from the mass may be necessary if the probable diagnosis is still uncertain after the common noninvasive investigations.

The crucial decisions regarding management of an adnexal mass therefore has to be taken after deciding upon its site of origin, possibility of malignant nature, patient's age and fertility status and also relative radiation and chemo sensitivity of the disease. Here we present a case of pelvic ewing's sarcoma which presented with adnexal mass in an adolescent girl, misdiagnosed as ovarian tumor and managed accordingly.

## CASE REPORT

A 14 year aged girl presented with pain over right leg since last few months and pain lower abdomen of recent onset. She had menarche 3 years back with regular cycle and average flow. Her bowel and bladder habit was unremarkable with no recent change. On examination she was having lower abdominal tenderness with an ill-defined mass on right iliac fossa and hypogastrium. Per rectal examination confirmed the presence of same pelvic mass. USG lower abdomen showed right adnexal heterogenous solid SOL

measuring 9.6x6.4cm. Right ovary couldn't be viewed separately. Left ovary and uterus was normal. Tumor markers like alpha fetoprotein, beta-hcg, CA-125 were within normal limits.



**Fig. 1** Ewing's Sarcoma illustrating sheets of small round cells with small amounts of clear cytoplasm.

Preoperative Hb was 14gm%, CXR was normal. At laparotomy, a large mass measuring 10x8 cm was found arising from the right lateral pelvic wall extending between leaves of broad ligament pushing the uterus to the left side. Both the ovaries were normal. The firm mass was fixed to pelvic wall. The mass was extremely adherent to the adjacent structures and complete removal was not possible. Representative Biopsy was taken from the mass and the abdomen closed. The girl had postoperative fever with rapid decline in Hb% to 8 gm%. Smear showed microcytic, hypochromic, anisocytosis. With suspicion of bone tumor, pelvic X-Ray was done. It showed no obvious bony pathology and

increased soft tissue density in right side of pelvis. Pelvic MRI showed large pelvic mass lesion with associated expansile lytic right iliac bone lesion and altered marrow signal intensity. A differential diagnosis of ewing's sarcoma and rhabdomyosarcoma was suggested. Histopathology confirmed the lesion as ewing's sarcoma. The girl subsequently received combination chemotherapy with cyclophosphamide, doxorubicin, vincristine, and dacarbazine for 6 cycles. Follow up USG revealed considerable shrinkage of the size of the pelvic SOL to 4x3cm. The girl was lost to follow up thereafter for about a year. After this apparently uneventful period, she again came with complaint of intense radiating right leg pain. This time, pelvic USG showed 12 cm sized solid-cystic SOL in right adnexa. Solid component appeared multilobulated. X-Ray pelvis showed extensive irregular bony destruction in the right iliac bone involving right acetabulum. FNAC suggested ewing's sarcoma/ PNET on histopathology. Confirmation was done by immunohistochemistry with CD99 which stamped it finally as recurrent ewing's sarcoma. The girl was again referred to the Radiotherapy dept. for further management.

## DISCUSSION

Ewing sarcoma is a highly malignant tumor occurring between the age of 10-20 years,

sometimes upto 30 years[3]. Because a common genetic locus is responsible for a large percentage of Ewing's sarcoma and primitive neuroectodermal tumors, these are sometimes grouped together in a category known as the Ewing family of tumors[4]. The diseases are, however, considered to be different: peripheral primitive neuroectodermal tumours are generally not associated with bones, while Ewing sarcomas are most commonly related to bone. The tumor commonly occurs in long bones[5], mainly in femur and tibia. About 1/3<sup>rd</sup> cases occur in flat bones, usually in the pelvis and calcaneum. The tumor characteristically involves a large area, or even the entire medullary cavity. The involved bone may be expanded. The tumor ruptures through the cortex early, and extends into soft tissues. The treatment of ewing's sarcoma includes chemotherapy and surgical excision with or without radiation. It is highly radiosensitive though the prognosis is poor due to bone to bone secondaries and distant metastasis at the time of diagnosis. The same occurred in our case where the pelvic soft tissue involvement was diagnosed as adnexal SOL of ovarian origin. Only MRI could suspect the possibility of a bone tumor. The other feature which went against the diagnosis of an ovarian tumor was radiating right leg pain. Thus, in this adolescent age group any pelvic mass lesion with lower limb pain should have an MRI done followed by FNAC of the lesion if bone tumor is

suspected. This case is an eye opener to the practicing Gynecologists that even a rare case of pelvic ewing's tumour may come as a differential diagnosis among young women with adnexal mass . An unnecessary laparotomy could have been avoided if in the first go an MRI and a guided FNAC would have been done.

## REFERENCES

1. Disasia PJ, Creasman WT. The adnexal mass and early ovarian cancer. In: Clinical gynaecologic oncology, 6th edn. St Louis, MO: Mosby, 1997; 253-281.
2. Kurjak A, Predanic M, Kuresic- Urek S, Jukic S. Transvaginal color and pulsed doppler assessment of adnexal tumor vascularity. Gynecol Oncol 1993;50:3-8.
3. Burt M, Karpeh M, Ukoha O et al. (January 1993). "Medical tumours of the chest wall. Solitary plasmacytoma and Ewing's sarcoma". J. Thorac. Cardiovasc. Surg. 105 (1): 89-96.
4. Iwamoto Y. Diagnosis and treatment of Ewing's Sarcoma. Jpn. J. Clin. Oncol. Feb 2007;37(2):79-89.
5. Rosenberg A E. Bones, Joints, and Soft Tissue Tumors. Robbins and Cotran Pathologic Basis of Disease, 7<sup>th</sup> ed, Saunders Elsevier, Philadelphia, Pennsylvania: 2004; 1301-1302.