

The Effects of Thermally Oxidized Palm Oil on the Kidney of Adult Wistar Rats

Authors

Boniface MN¹, Ejimofor OC², Ezissi AI³

¹Department of Anatomy, College of Health sciences, Nnamdi Azikiwe University
Nnewi Campus, Anambra State,
Nigeria

Corresponding Author

Boniface MN

Email: *miracleboniface22@gmail.com*

Abstract

This study was aimed at the histological changes that might occur following the ingestion of thermally oxidized palm oil. The study was prompted by rising reports of toxicity of thermoxidized palm oil to body tissues and organs following ingestion, and palm oil happens to be the most widely consumed oil especially in Nigeria as it is a core ingredient of many Nigerian diets. Sixteen wistar rats of an average weight of 180g were used for this study and were divided into four groups of four rats in each group. Group A served as the control, receiving normal feed (grower mash), group B received a diet containing 20% fresh palm oil and 80% of normal feed. Group C received a diet containing 15% thermoxidized palm oil and 85% normal feed. Group D received a diet containing 20% thermoxidized palm oil and 80% normal feed. The animals were sacrificed after 28 days (1 month) of administration. The results showed that consumption of thermally oxidized palm oil had a negative effect on the histological appearance of the kidney ranging from vacuolation and degeneration of renal corpuscle, tubular necrosis, patches/diffused denudation of the renal tubular cells with loss of brush border; to accumulation of homogenous substances with eosinophilic debris, suggesting acute renal failure. Excessive ingestion of fresh palm oil was also seen to be unsafe as it induced vacuolation of renal corpuscles and tubular necrosis. From the result of this study, I recommend that ingestion of thermoxidized palm oil should be avoided and also, there should be a controlled ingestion of fresh palm oil in adequate quantity.

Keywords: Thermally Oxidized Oil, Palm Oil, Kidney, Body Weight.

INTRODUCTION

Palm oil is a major source of the world's supply of oil and fats. In Nigeria, it is the most widely used

cooking oil [1]. It is usually consumed fresh but in a bid to increase palatability, it is thermally oxidized. The thermoxidized form is produced

when the fresh palm oil is heated during processing and preparation of food. This generates free radicals that become part of the diet [2] and pose deteriorating effects on the dietary oil [3].

Numerous studies have demonstrated that long-term consumption of oxidized oils and fats cause growth retardation, thrombosis, fatty livers, essential fatty acid deficiency and micronutrient malnutrition leading to deactivation of key metabolic enzymes [4-5]. Its consumption has also been implicated in lowered red blood cell count [1] [6-7] in experimental animals. Igiri et al [9] reported that rat intestinal mucosa was severely damaged by chronic consumption of thermoxidized palm oil diet. Eder et al [8] suggested that dietary oxidized oil suppresses gene expression and lowers the activities of lipogenic enzymes in the liver of rats and leads to reduce concentration of triglycerides in the liver. There is virtually no work on the effect of thermoxidized palm oil on the kidney.

Mesembe et al [10] reported that chronic consumption of thermoxidized palm oil diet affected the morphologic status of the testes of wistar rats and suggested that it could be a factor of infertility in males.

The kidneys are the major renal organ. They produce urine and play a principal role in the maintenance of the internal environment of the body. The kidneys serve several essential regulatory roles in most animals, including vertebrates and some invertebrates. They are essential in the urinary system and also serve

homeostatic important functions, including filtration and excretion of metabolic waste products (urea and ammonium); regulation of necessary electrolytes, fluid, and acid-base balance; and stimulation of red blood cell production. They secrete hormones such as erythropoietin, thrombopoietin, rennin, calcitriol, prostaglandins. They also serve to regulate blood pressure via the renin-angiotensin-aldosterone system, controlling reabsorption of water and maintaining intravascular volume. The kidneys also produce hormones including calcitriol, erythropoietin, and the enzyme rennin [15].

It is therefore hypothesized in this study that kidney functions could be negatively affected by the consumption of thermally oxidized palm oil. Since the effect of thermally oxidized palm oil on the kidney has not been fully investigated, it is found worthwhile in this study to know the effect(s) of the thermally oxidized palm oil on the kidney.

MATERIALS AND METHODS

Experimental Animals

Sixteen (16) young wistar rats of an average weight of 180g were used in this study and were obtained from the animal farm house, Department of Anatomy, Nnamdi Azikiwe University, Nnewi Campus. They were bred and maintained under standard housing conditions and fed with grower mash, a product of Premier Feed Mills Co. Limited (A subsidiary of Flour Mills Nigeria Plc) in Sapele, Delta State, Nigeria for four weeks. The

feed and water were allowed ad libitum. Acclimatization also took place simultaneously.

Preparation of Test substance

Three (3) litres of fresh palm oil was obtained from the produce of a local palm oil dealer in Nnewi, Nnewi South Local Government Area of Anambra State, Nigeria. The oxidized palm oil was obtained by heating 2 litres of the fresh form at 150 degree Celsius in a stainless steel pot intermittently for five sessions at one hour per session with 6 hours cooling interval [10]. No fresh oil was added intermittently. They were stored in a bottle and covered very well.

Experimental Protocol

The rats were divided into four different groups designated A-D; each group having four rats. Group A served as the control while groups B, C and D served as the test groups. The actual administration of test samples to the test animals lasted for four weeks. Group A were fed with normal grower mash throughout the period of the experiment while Group B animals were fed with fresh palm oil diet containing 20% oil and 80% feed. Group C animals received thermoxidized oil diet made of 15% thermoxidized oil and 85% feed. Group D animals received thermoxidized oil diet made of 20% thermoxidized oil and 80% feed. This is regarded as excess consumption following that an average Nigerian diet has about 15% palm oil [11]. The animals were weighed before administration.

Twenty four hours after the last administration, the animals were weighed and recorded. The animals were sacrificed after anaesthetizing with chloroform and the kidney tissues extracted and weighed.

Tissue Processing

For easy study of sections under microscope, the tissues passed through processes of fixation, dehydration, clearing, infiltration, embedding, sectioning and staining. Fixation was carried out in 10% formal saline for 10 hours. After fixation, the tissues were washed in stream tap water. Dehydration of fixed tissues was done using ascending grade of alcohol, 50%, 70%, 90% and absolute. The tissues were cleared in xylene after which infiltration was done in a molten paraffin wax at 60°C for two hours each in two changes. The embedding of the tissues was done in molten paraffin wax and they were sectioned afterwards. Hematoxylin and eosine method was used in staining.

Statistical Analysis

Data were analysed using student's t-test of SPSS version 16 software package and $P < 0.05$ was considered as the level of significance.

Ethical Approval

Ethical approval was obtained from the ethical committee, Faculty of Basic Medical Sciences Nnamdi Azikiwe University, Nnewi Campus.

RESULTS

in rats which received 20% fresh palm oil, 15% and 20% thermally oxidized palm oil.

Physical Observations

The control rats showed no clinical signs.

However, depression and weakness were observed

Morphometric Analysis of body and kidney weights

Table 1: Comparison of mean initial and final body weights in all groups.

Groups	A(control)	B(20% fresh palm oil)	C(15% thermooxidized palm oil)	D(20% thermooxidized palm oil)
Initial body weights(g)	175.00±2.04	180.00±2.04	185.00±2.04	180.00±4.08
Final body weight(g)	190.15±2.63 ^a	195.24±16.83 ^{≠b}	173.90±12.98 ^{≠b}	224.13±19.47 ^{≠b}
Relative kidney weight(mg/g)	7.37±0.21	7.79±0.87 [≠]	8.69±0.93 [≠]	8.22±0.32 [≠]

Values are expressed as mean±SEM, [≠] = non-statistically significant compared with the control group, ^a = statistically significant compared with the initial body weight, ^b = non-statistically significant compared with initial body weight, significance level were taken as P<0.05.

Table 1 showed that there was an observable increase in the body weights of rats in control group (with initial body weight, 175.00±2.04g and final body weight, 190.15±2.63g), in group B (with initial body weight, 180.00±2.04g and final body weight, 195.24±16.83g) which received 20% fresh palm oil as well as in group D (with initial body weight, 180.00±4.08g and final body weight, 224.13±19.47) that received 20% thermally oxidized palm oil. Rats in group C (with initial body weight, 185.00±2.04g and final body weight,

173.90±12.98g) that received 15% thermally oxidized palm oil, showed a decrease in weight but none of the weight changes were significant (P>0.05) when compared with the control group. However, when the final body weights were compared with initial body weights, group A showed a significant increase (P<0.05) in body weight (Figure 1).

No significance difference was observed in relative kidney weight of the test groups when compared with the control (Table 2).

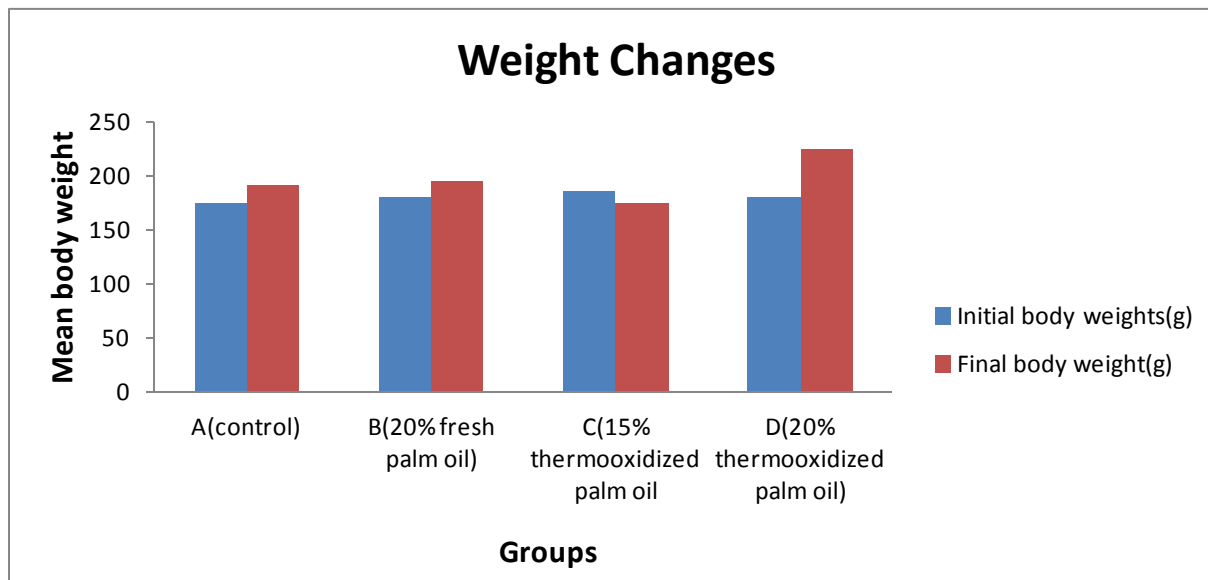


Figure 1: Bar chart showing the mean initial and final body weight

Histopathological Findings

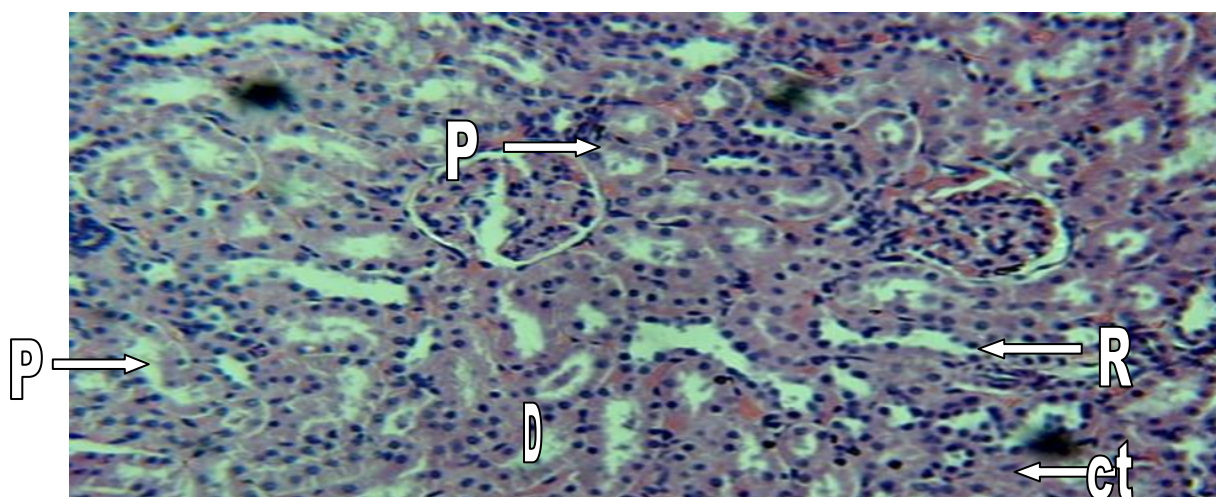


PLATE 1: Showing a photomicrograph of the kidney of control (Group A) rats showing normal histological structure of renal corpuscle (R), proximal convoluted tubule (P), distal convoluted tubule (D), Henle's loop (H), and collecting tubule (CT). Stained by H & E technique, (x200).

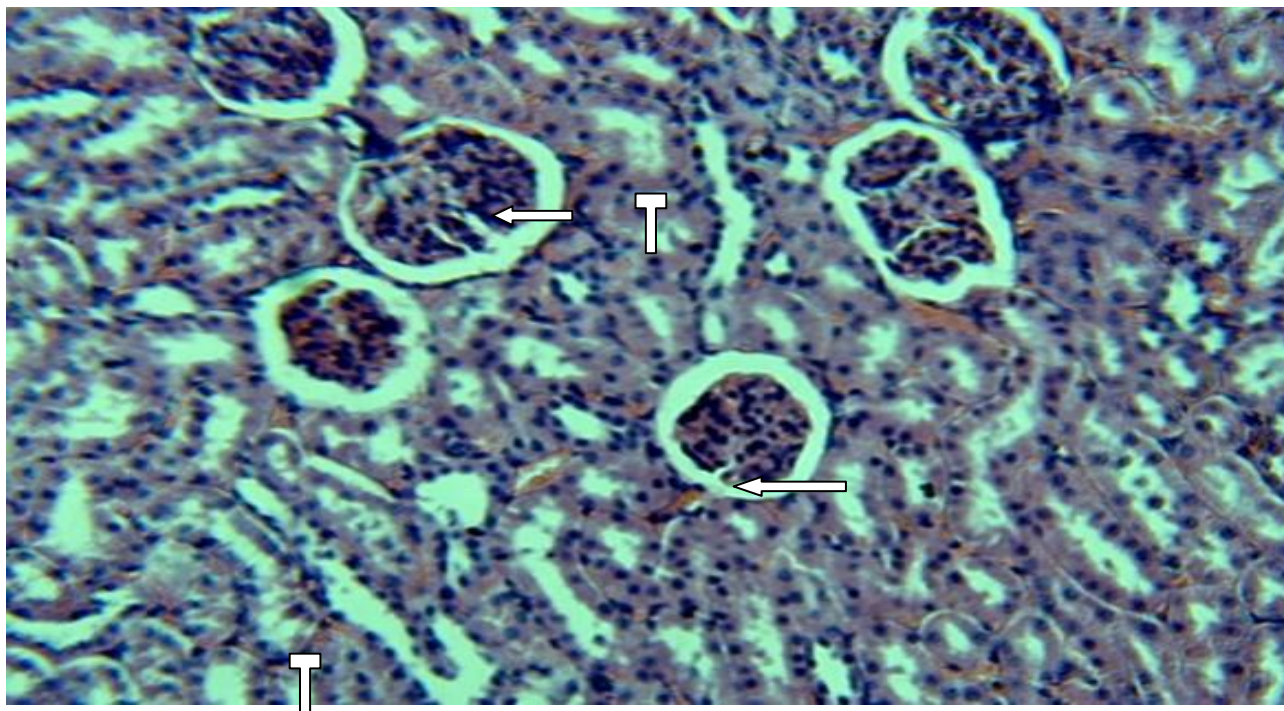


PLATE 2: Photomicrograph of the kidney of Group B rats fed with 20% fresh palm oil showing vacuolation of renal corpuscle. Also, there is evidence of tubular necrosis (T). Stained by H & E technique (x200). Arrows indicate sites of vacuolation.

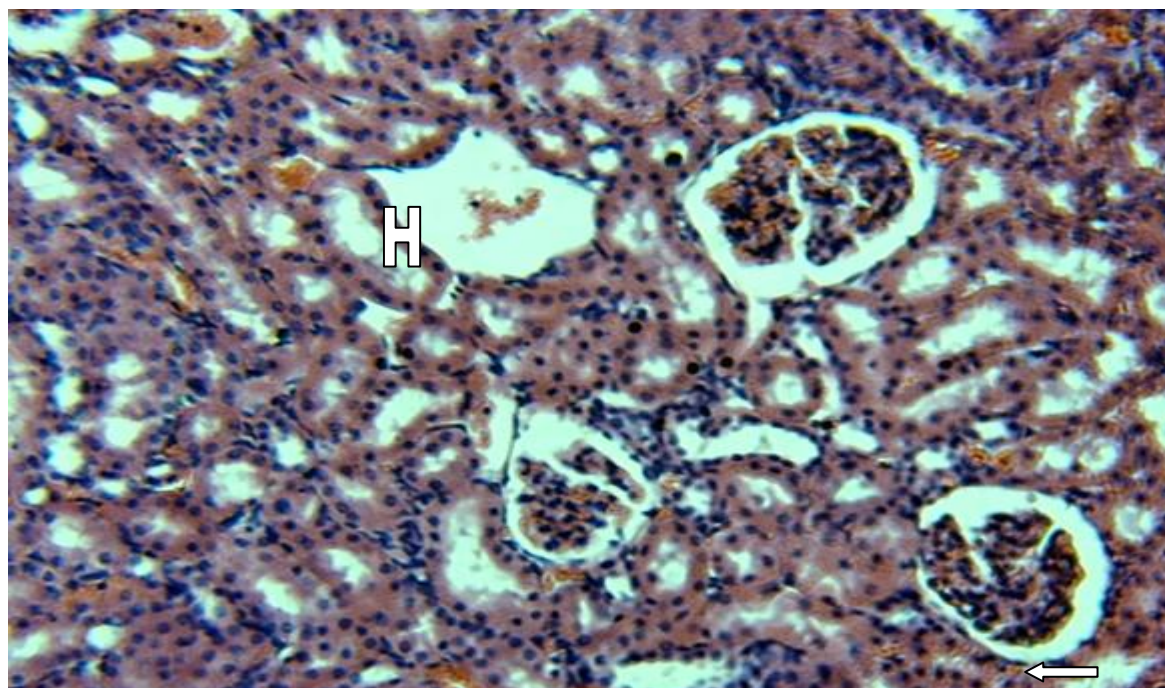


PLATE 3: Photomicrograph of the kidney of Group C rats fed with 15% thermally oxidized palm oil showing evidence of vacuolation of renal corpuscles (Arrow), a homogenous substance with eosinophilic debris (H), as well as evidence of degeneration of renal corpuscles. Stained by H & E technique, (x200).

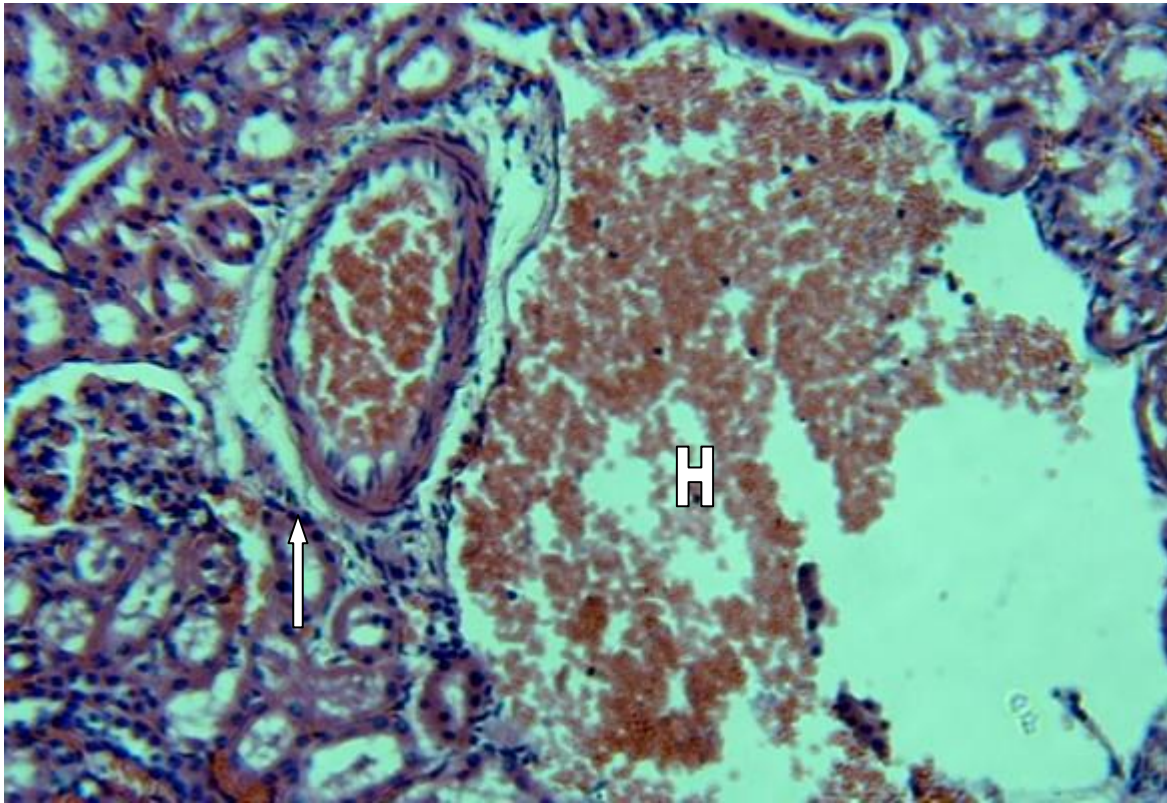


PLATE 4: Photomicrograph of the kidney of Group D rats fed with 20% thermally oxidized palm oil showing a homogeneous substance with mass accumulation of eosinophilic materials (H), as well as evidence of necrosis (Arrow). Stained by H & E technique, X 200.

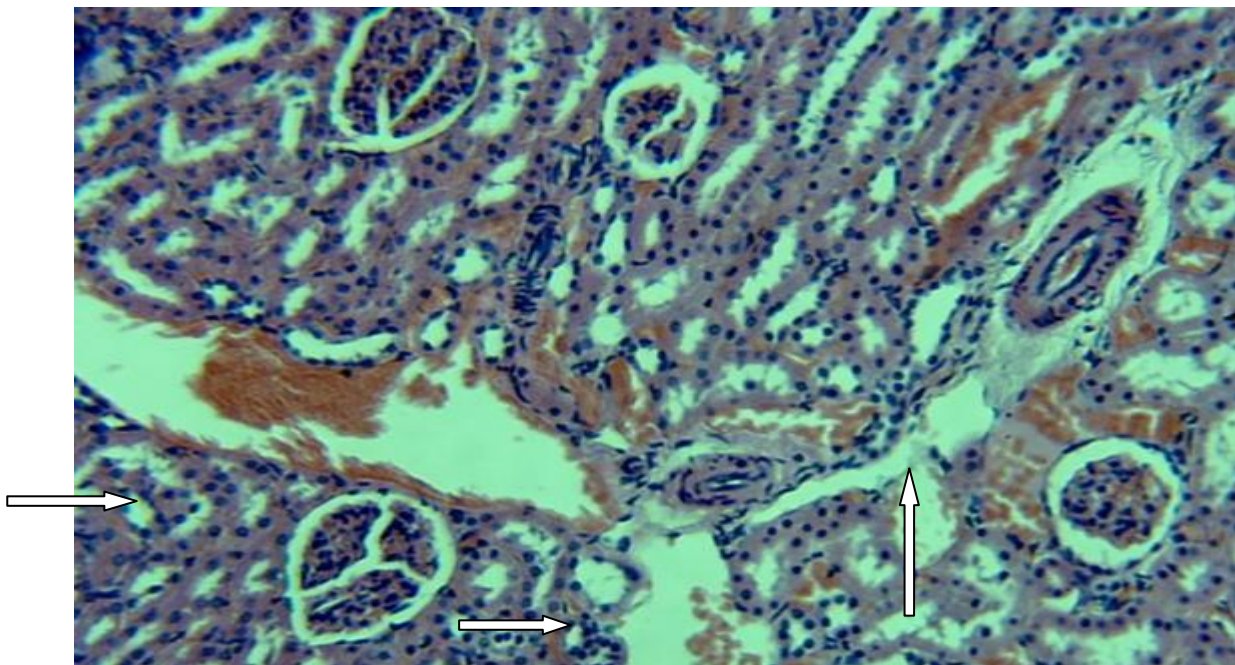


PLATE 5: Photomicrograph of the kidney of Group D rats fed with 20% thermally oxidized palm oil showing Patchy or diffuse denudation of the renal tubular cells with loss of brush border, suggesting acute tubular necrosis (Arrows). Stained by H & E technique, (x200).

DISCUSSION

The results of this study showed that the excessive consumption of fresh palm oil and thermally oxidized palm oil is toxic to the kidney. It was observed from this study that fresh palm oil induced vacuolation of renal corpuscle and tubular necrosis while thermally oxidized palm oil causes vacuolation and degeneration of renal corpuscles, patchy/diffuse denudation of renal tubular cells with loss of brush border and accumulation of homogenous substances with eosinophilic debris. This finding is similar to that reported by Shastry and Co [14], who pointed out that extreme consumption of thermally oxidized palm oil caused tubular cell in medullary region, cytoplasmic as well as nuclear vacuoles. Also, he revealed that occasionally, tubules contained eosinophilic materials in the lumen.

These effects could be as a result of extreme consumption of thermally oxidized palm oil and these effects probably could lead to kidney failure. This is evidenced in tubular necrosis and accumulation of eosinophilic materials in the tubules. However, this study has made us to discover that consumption of thermally oxidized palm oil is hazardous to the kidney, and also extreme consumption of fresh palm oil could lead to kidney failure. The toxicity of the this thermally oxidized palm oil may be attributed to the many oxidative products such as hydroperoxide and aldehydes produced during deep-frying which can cause oxidative damage effects to cells and organs [12-13].

The increase in weight as observed in this study is somehow in lined with Shastry and Co [14] who reported a significant increase in body weight in rats fed with fresh palm oil, reused palm oil and sunflower oil. However, the increase in weights in this study was not statistically significant.

CONCLUSION

Having noted the above pathological damages to the organ (kidney), thermally oxidized palm oil, and extreme consumption of fresh palm oil is toxic to the kidney.

RECOMMENDATION

Having critically and carefully carried out this research; witnessed and observed the damages caused by thermally oxidized palm oil and excessive fresh palm oil on the kidney of Albino Wistar rat, it is sincerely recommended that the consumption of thermoxidized palm oil and excess fresh palm oil should be avoided.

I also recommend that further researches be made on other vital body organs including the heart using the same substrate (thermoxidized palm oil).

REFERENCES

1. Mesembe O.E; Igiri A.O; Udoaffah G; Akpa O.A; Enoh L.A and Fisher V.A. (2004a). Influence of thermoxidized and fresh palm oil diets on some mineral contents of the femur bone of growing wistar rats. *J. Expt and Clin* 3(1): 8-11.
2. Jaarin K; Norhayaty M; Norzana G; Nor Ani U and Ima-Nirwana S. (2006). Effect of

- heated vegetable oils on serum lipids and aorta of ovariectomized rats. *Pakistan Journal of Nutrition*, 5(1): 19-29.
3. Perkins E.G and VanAkkeren L.A. (1965). Heated fats subjected to deep fat frying processes. *J. Am. Oil Chem. Soc.* 42:161-166.
 4. Hill E.G, Johnson S.B, Lawson L.D, Manfouz M.M, Hol R.T. (1982). Perturbation of metabolism of essential fatty acids by dietary partially hydrogenated vegetable oil. *Pro. Natl Acad Sci*, 79: 953-957.
 5. Izaki Y; Yoshikawa S and Uchiyama M. (1984). Effect of injection of thermally oxidized frying oil on peroxidative criteria in rats. *Lipids* 19(5): 324-331.
 6. Isong E.U; Ebong P.E; Ifon E.T; Umoh I.B and Eka O.U. (1997). Thermo-oxidized palm oil induces reproductive toxicity in healthy and malnourished rats. *Plant Foods for Human Nutrition*, 51(2): 159-166.
 7. Edem DO. (2002). Palm oil: Biochemical, Physiological, Nutritional, Haematological and Toxicological Aspects. A review. *Plant Foods for Human Nutrition*, 57(3-4): 333-341.
 8. Eder K, Keller U; Hirche E and C. Brandsch. (2003). Thermally oxidized dietary fat increase the susceptibility of rat LOL to lipid peroxidation but not their uptake by macrophage. *Journal of Nutrition* ,133(12): 2830–2837.
 9. Igiri A.O, Ibegbu A.O and Osim E.E. (1994). The morphological and histological changes in the small intestines induced by chronic consumption of palm. *Journal for applied sciences.* 3&4:144-153.
 10. Mesembe O.E; Igiri A.O; Akpa A.O.C; Ekong M.B; Fisher V.A and Anibeze C.I.P. (2004b). Histological changes and demonstration of glycogen distribution in the gonads of male wistar rats following long term injection of mixed palm oil diets. *J. Expt and Clin Anat* 3(2); 54-56.
 11. Umoh I.B. (1972). Changes in the Nutritive Values of Some Nigerian Diets After Cooking by Certain South-East Traditional Methods. PhD thesis, University of Ibadan, Nigeria.
 12. Choe, E. and Min D. B. (2007). Chemistry of deep and repeated frying of oils. *Journal of Food Science*, 72(5), R77 – R86.
 13. Dobarganes, C. and Marquez – Rutz G. (2003). Oxidized fats in foods. *Current Opinion in Clinical Nutrition and Metabolic Care*, 6(2), 157-163.
 14. Shastry C.S. Patel Narendrakumar Ambalal, Joshi Himanshu and Aswathanarayana B.J (2011). Evaluation of Effect of Reused Edible Oils on Vital Organs of Wistar Rats. *Nitte University J. Health Science.* 1(4): 10-15.
 15. The Kidneys and How they Work. National Kidney and Urologic Diseases Information Clearinghouse (NKUDIC) [serial online]. Available from: National Institute of Diabetes and Digestive and Kidney Diseases (NIDDK), NIH. Available at <http://kidney.niddk.nih.gov/kudiseases/pubs/yourkidneys/#kidneys>.