



IGM Publication

Journal Of Medical Science And Clinical Research

An Official Publication Of IGM Publication

Endo- Perio Lesion- A Brief Review

Authors

Sharmila Devi Devaraj¹, Jayashri Prabhakar²

Saveetha Dental College & Hospitals, Chennai TamilNadu, India.

Email id: *shalluluxana@gmail.com*.

ABSTRACT

Endo- Perio lesions are considered to be complex dental conditions for the clinicians to establish accurate diagnosis and treatment plan. The aim of this article is to bring about proper diagnosis followed by the removal of causative factors and making use of various treatment modalities in order to restore health, function and aesthetics of the concerned teeth. This article also discuss various topics that will guide clinicians in the management of such lesions have been summarized.

KEY WORDS-*Endo – Perio lesion, Endo – Perio inter relationship, Pulpal diseases, Periodontal pocket, Endodontic treatment.*

INTRODUCTION

Endodontium and Periodontium are closely interrelated and diseases of one tissue may lead to the involvement of the other.[2] The effect of periodontal disease on the pulp was described first by Turner & Drew in 1919.[5] The actual relationship between periodontal and pulpal diseases was first described by Simring &

Goldberg in 1964.[2] Pulp and periodontium have embryonic, anatomic and functional inter relationships. The interrelationship of these structures influences each other during health function and diseases. [3] Many authors have reported the similarity of the bacterial flora associated with endodontic and periodontal infections. Cross seeding of bacteria from one

tissue to other can occur in either direction through the communication pathways. [16] Therefore periodontal therapy deals with many aspects of the supporting structures including prevention and repair of lesions of the gingival sulcus and supporting structures. Endodontics deals primarily with diseases of pulp and periapical tissues. The success of both periodontal and endodontic therapy depends on the elimination of both disease processes, whether they exist separately or as a combined lesion. [3]

PATHWAYS OF COMMUNICATION

The dental pulp and periodontal tissues are closely related. The pulp originates from the dental papilla and the periodontal ligament from the dental follicle and it is separated by Hertwig's epithelial root sheet. As the tooth matures and the root formation takes place, three main entrance for exchange of infectious elements and other irritants between the two zone of compartments are created by dentinal tubules, lateral and accessory canals, and the apical foramen.[1] They are ecto mesenchymal in origin, the cells from which proliferate to form dental papilla and dental follicle, these are the precursors of the pulp and periodontium . They get separated during the formation and development of tooth bud from the overlying ectoderm which differentiate into enamel and dentin. [6]

DENTINAL TUBULES

Dentinal tubules which contains the odontoblastic process that extends from the odontoblast at the Pulpal dentin border to the dentino enamel junction or cemento enamel junction.[3] Tubular

communication between pulp and periodontium may occur when dentinal tubules become exposed to periodontium by the absence of overlying cementum.[2] Dentinal tubules are exposed when cementum and enamel do not meet at CEJ as well as the effect of root scaling and planning on cementum integrity, trauma and bleaching induced pathosis.[1] Exposed dentinal tubules in areas devoid of cementum may serve as communication pathways between the pulp and the periodontal ligament.[1] Other areas of dentinal communications may occur due to developmental grooves like palato-gingival and apical grooves, disease processes, or periodontal or surgical procedures.[7]

LATERAL AND ACCESSORY CANALS

Lateral and accessory canals can be present in any position along the root .[1] It is estimated that 30–40% of all teeth have lateral or accessory canals and the majority of them

are found to be in the apical third of the root.[7] Root canal rampification first described nearly 100 years ago by Preiswerk (1901). The term “Accessory canal” is now used to describe any rampification that connects the root canal system to the periodontal ligaments.[8] The frequency of these rampifications on the root surface are as follows : Apical third 17%, Coronal third 1.6%, Body of the root 8.8% .[9] These canals contain connective tissue and blood vessels that connect the circulatory system of the pulp with that of periodontium. However , not all these canals extend the full length from the pulp chamber to the floor of the furcation. [1] In some instances,

the lateral or accessory canal is obliterated by calcification but patent communication of varying sizes (10-250 micro meter) may remain in many cases.[3] Bender et al , stated that periodontal endodontic problems were much more frequent in the molars than in the anterior teeth because of the greater number of accessory canals present in the molars.[10] The radiographic indications of the presence of lateral canals before obturation are

A) localised thickening of PDL on the lateral root surfaces.

B) a frank lateral lesion.[3]

APICAL FORAMEN

The apical foramen is the main route of communication between the pulp and the

periodontium. Bacterial toxic products and inflammatory mediators in a diseased pulp may exit readily through the apical foramen to cause periapical pathosis. The apex of the root is a portal of entry of inflammatory elements from deep periodontal pockets to the pulp. Pulp inflammation or pulpal necrosis extends into the periapical tissues, causing a local inflammatory responses often associated with bone and root resorption.[1]

NON- PHYSIOLOGICAL PATHWAYS

A) Iatrogenic root canal perforation

B) Vertical root fractures due to trauma

C) Fractured roots due to lateral condensation technique and intra canal endodontic posts.[8]

ETIO PATHOGENESIS

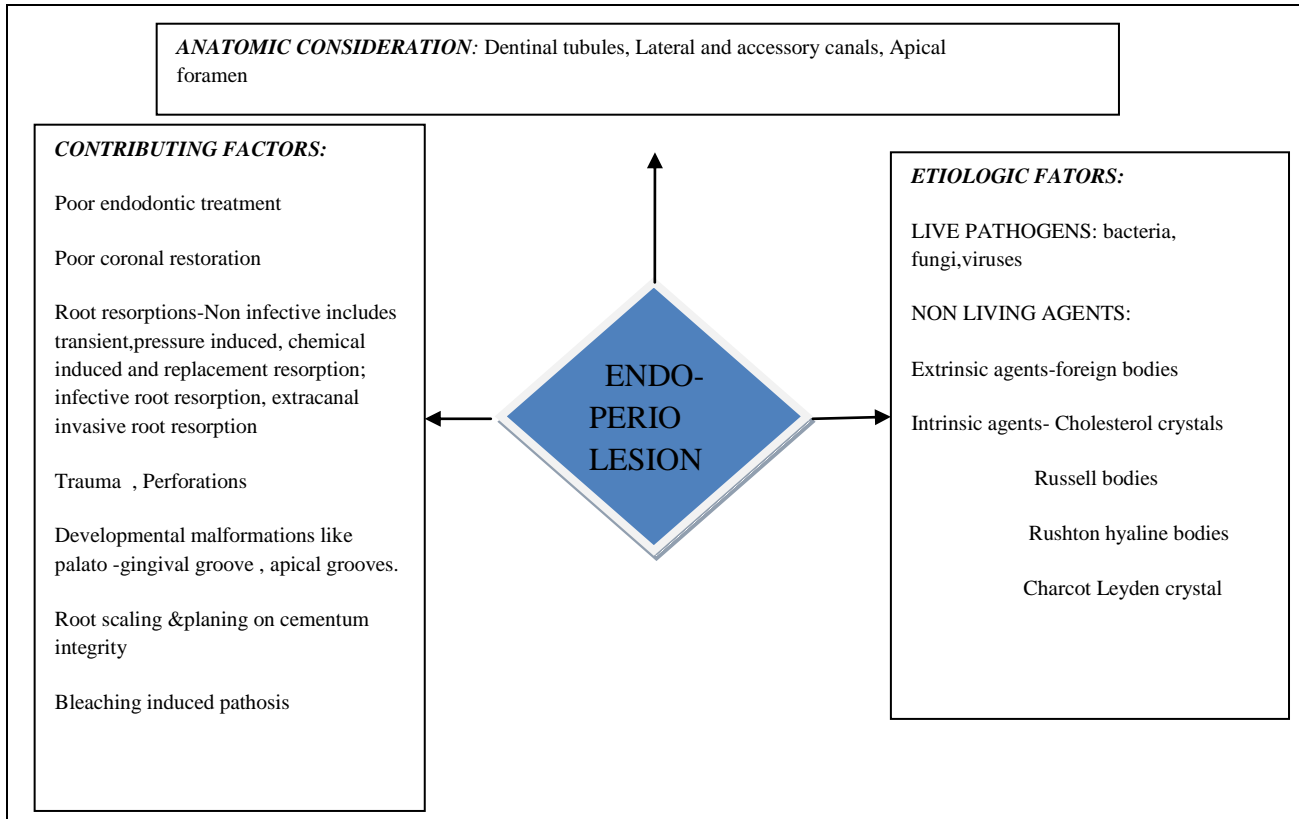


FIG .1 DIAGRAMMATIC REPRESENTATION OF THE ETIO PATHOGENESIS OF ENDO-PERIO LESIONS [11]

CLASSIFICATION: [12]

AUTHORS	PREVIOUS CLASSIFICATIONS
Oliet and Pollock	<p>Class I: Primary endodontic involvement with secondary periodontal factors, requiring only endodontic treatment.</p> <p>Class II: Primary periodontal involvement with secondary endodontic factors, requiring periodontal treatment alone.</p> <p>Class III: Endodontic-periodontal involvement requiring correlated and combined therapy.</p>
Simon et al	<p>Class I: Primary endodontic lesion.</p> <p>Class II: Primary periodontal lesion.</p> <p>Class III: Primary endodontic disease with secondary periodontal involvement.</p>

	<p>Class IV: Primary periodontal disease with secondary endodontic involvement.</p> <p>Class V: True combined lesion.</p>
<p>Rotstein and Simon</p>	<p>Class I: Primary endodontic disease.</p> <p>Class II: Primary periodontal disease.</p> <p>Class III: Combined disease, which include:</p> <p>A) Primary endodontic disease with secondary periodontal involvement.</p> <p>B) Primary periodontal disease with secondary endodontic involvement.</p> <p>C) True combined disease.</p>
<p>Guldener</p>	<p>Class I: Primary endodontic lesions.</p> <p>Class I (A): Accidental perforations (intraalveolar) or resorptive perforations (internal resorption).</p> <p>Class I (B): Chronic periradicular lesion (granuloma or cyst) or acute periradicular lesion (alveolar abscess).</p> <p>Class II: Primary periodontal lesions.</p> <p>Class II (A): Advanced periodontal disease with or without extension to the apical area (pulp vital).</p> <p>Class II (B): Secondary endodontic involvement.</p> <p>Infection through lateral canals or dentinal tubules. Pulpal necrosis with or without secondary periapical involvement.</p> <p>Class III: Combined lesion.</p> <p>True combined lesion (coalescence between periodontal and endodontic lesion) or vertical crown-root fracture with Pulpal.</p>
<p>Geurtsen et al(1985), cited in Haueisen and Heidemann</p>	<ol style="list-style-type: none"> 1) Combined lesions requiring only a single root-canal treatment (favourable prognosis). 2) Combined lesions requiring both endodontic and periodontal treatments (less favourable prognosis). 3) Combined lesions with little hope of successful treatment (poor prognosis).

Torabinejad and Trope	<p>1) Periodontal defect of endodontic origin.</p> <p>2) Periodontal defect of periodontal origin.</p> <p>3) Combined endodontic- periodontal lesion.</p> <p>. Independent endodontic and periodontal lesions without communication.</p> <p>. Endodontic and periodontal lesions with communication.</p>
Weine	<p>Class I: Tooth in which symptoms clinically and radiographically simulate periodontal disease but are in fact due to Pulpal inflammation and/or necrosis.</p> <p>Class II: Tooth that has both Pulpal or periapical disease and periodontal disease concomitantly.</p> <p>Class III: Tooth has no Pulpal problem but requires endodontic therapy plus root amputation to gain periodontal healing.</p> <p>Class IV: Tooth that clinically and radiographically simulates Pulpal or periapical disease but in fact has periodontal disease.</p>
Hiatt	<p>Class 1: Pulpal lesions with secondary periodontal disease of short duration.</p> <p>Class 2: Pulpal lesions with secondary periodontal disease of long duration.</p> <p>Class 3: Periodontal lesions of short duration with secondary Pulpal disease.</p> <p>Class 4: Periodontal lesions of long duration with secondary Pulpal disease.</p> <p>Class 5: Periodontal lesions treated by hemisection or root amputation.</p> <p>Class 6: Complete and incomplete crown-root fractures.</p> <p>Class 7: Independent Pulpal and periodontal lesions which merge in to a combined lesion.</p> <p>Class 8: Pulpal lesions which evolve in to periodontal lesions following treatment.</p> <p>Class 9: Periodontal lesions that evolve in to Pulpal lesions following treatment.</p>
Hany Mohamed Aly Ahmed	<p>Class I Synchronous endo perio lesion</p> <p>Class II Pulpal lesions with subsequent periodontal involvement</p> <ol style="list-style-type: none"> 1. Localised pathological pattern 2. Unilaterally distributed pattern

Class III Periodontal lesions with subsequent Pulpal involvement

1. Developmental
2. Non developmental

Class IV Independent endo perio lesions

Class V Iatrogenic endo perio lesions

1. Endodontic procedures causing periodontal lesions
2. Periodontal procedures causing Pulpal lesions
3. Non-endodontic /Non periodontal procedures causing endo perio lesions.

Class VI Advanced endo perio lesion

1. Advanced endo perio lesion with independent periodontal involvement
2. Advanced endo perio lesion with no independent periodontal involvement

Class VII Indefinite endo perio lesions.

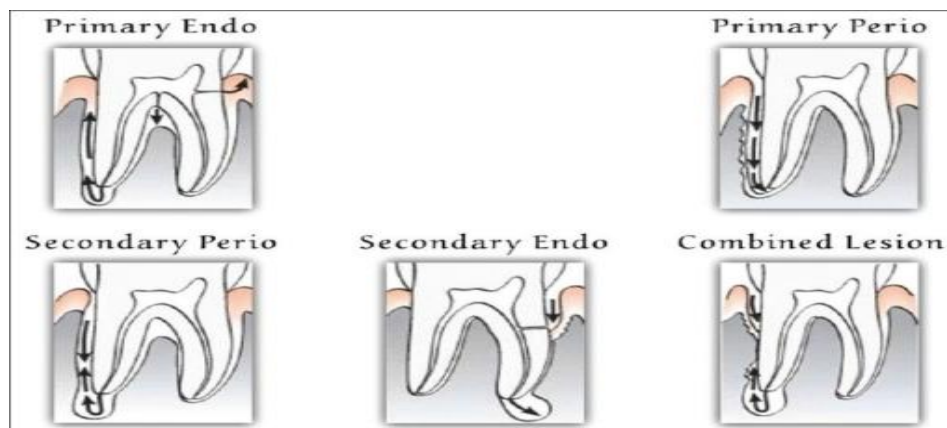


FIG.2 DIAGRAMMATIC REPRESENTATION OF POSSIBLE ENDO- PERIO PROBLEMS [13]

CLASS I-PRIMARY ENDODONTIC LESION

An acute exacerbation of a chronic apical lesion on a tooth with a necrotic pulp may drain coronally through the periodontal ligament into the gingival sulcus.[1] Endodontic lesions are

most frequently initiated and sustained by the apical foramen, followed by accessory and lateral canals, most infrequently by dentinal tubules. [2] These inflammatory lesions causes localized oedema and results in increased intra-pulpal pressure and cell death.[14] Increasing damage

associated with an inflammatory exudates causes local collapse of the venous part of the local microvasculature. This causes localised tissue hypoxia and anoxia resulting in localized necrosis, the chemical mediators of which cause further localized oedema. [15] An inflammatory process in the periodontal tissues resulting from noxious agents present in the root canal system of the tooth. [2] This condition may clinically mimic the presence of a periodontal abscess. In reality, it would be a sinus tract originating from the pulp that opens into the periodontal ligament. A similar situation occurs where drainage from the apex of a molar tooth extends coronally into the furcation areas. This may also occur in the presence of lateral canals extending from a necrotic pulp into the furcation area. [16] Primary endodontic lesions usually heal following root canal therapy. The sinus tract extending into the gingival sulcus or furcation area disappears at an early stage, once the affected necrotic pulp has been removed and the root canals are well cleaned and obturated. [1]

CLASSII- PRIMARY PERIODONTAL LESION

The lesions are caused primarily by periodontal pathogens. In this process, chronic periodontitis progresses apically along the root surface. In most cases, pulpal tests indicate a clinically normal pulpal reaction. There is frequently an accumulation of plaque and calculus and the presence of deep and wider pockets may be detected. [17] The prognosis depends on the stage of periodontal disease and the efficacy of periodontal treatment.[20]

CLASS III- PRIMARY ENDODONTIC DISEASE WITH SECONDARY PERIODONTAL INVOLVEMENT

If a suppurating primary endodontic disease remains untreated for a long period of time, it may then become secondarily involved with marginal periodontal breakdown. [1] Plaque accumulation at the gingival margin of the sinus tract leads to plaque induced periodontitis in the concerned area. When plaque and calculus are detected, the treatment and prognosis of the teeth are different from those of the teeth involved with only endodontic disease. The tooth will requires both endodontic and periodontal treatment. [3] Primary endodontic lesions with secondary periodontal involvement may also occur as a result of root perforation during root canal treatment, or where pins or posts have been misplaced during coronal restoration. Symptoms may range from local deepening of periodontal pockets to more acute periodontal abscess formation. Root fractures may also present as primary endodontic lesions with secondary periodontal involvement. [16] Root canal therapy is carried out and certain amount of time is allowed for periodontal tissues to heal. After that evaluation period of 2-3 months periodontal therapy is carried out if required. Prognosis depends on the amount of attachment loss and severity of periodontal diseases. [5]

CLASS IV- PRIMARY PERIODONTAL DISEASE WITH SECONDARY ENDODONTIC INVOLVEMENT

The apical progression of a periodontal pocket may continue until the apical tissues are involved. In this type of lesion, the pulp may become necrotic as a result of infection entering via lateral

canals or the apical foramen. In the single rooted teeth, the prognosis is usually poor. [1] In molar teeth, the prognosis may be better. Root resection can be considered as a treatment alternative. [16] If the neurovascular supply circulating through the apex is intact, the pulp has good prospects for survival. It has been reported that pulpal changes resulting from periodontal disease are more likely to occur when the apical foramen is involved. In these cases, microbiota originating from the periodontal pocket are the most likely source of root canal infection. [17] Radiographically these lesions are similar to primary endodontic lesions with secondary periodontal involvement. [19] Prognosis for a tooth involved with periodontal disease is determined by the outcome expected from periodontal therapy. [20]

CLASS V- TRUE COMBINED LESION

These lesions are often indistinguishable from an advanced primary endodontic lesion with secondary periodontal involvement and/or a primary periodontal lesion with secondary endodontic involvement. [21] True combined endodontic-periodontal disease occurs with lesser frequency. [2] It is formed when an endodontic lesion progresses coronally and combines to an infected periodontal pocket progressing apically.[13]The degree of attachment loss in this lesion is invariably large and the prognosis is guarded .These are particularly true in single-rooted teeth[1]. The radiographic appearance of combined endodontic-periodontal disease may be similar to that of a vertically fractured tooth. A fracture that has invaded the pulp space, with

resultant necrosis, may also be labelled a true combined lesion and yet not be amenable to successful treatment.[2] Immediate sealing of root perforations, root canal therapy, advanced endodontic surgery, periodontal therapy with procedures such as hemisection, root resection may be required treatment options. Prognosis is guarded and depends on the amount of destruction caused by periodontal disease. [5]

DIAGNOSIS

Diagnosis of primary endodontic disease and primary periodontal disease usually present no clinical difficulty. In primary periodontal disease, the pulp is vital and responsive to testing. In primary endodontic disease, the pulp is infected and non vital. However, primary endodontic disease with secondary periodontal involvement, primary periodontal disease with secondary endodontic involvement, or true combined diseases are clinically and radiographically very similar. Accurate diagnosis can be achieved by careful history taking, examination of both endodontic and periodontal status by using the special tests. [3]

History taking

Chief complaint

Patient complaints of Previous Pulpal exposure, previous periodontal treatment , trauma , pain

Duration

Primary Pulpal condition mostly will be acute, whereas secondary Pulpal, periodontal or combined conditions mostly will be chronic. At the same time a combined or a concomitant

condition have a chronic periodontal with acute involvement.

Distribution

Pulpal is mostly localized whereas periodontitis is mostly generalized.

Aetiological factors

Pulpal exposure / trauma for primary periapical lesions and calculus / plaque for primary periodontal lesions.

Visual examination

A thorough visual examination of the lips, cheeks, oral mucosa, tongue, palate and muscles should be carried out. The alveolar mucosa and the attached gingiva are examined for the presence of inflammation, ulcerations or sinus tracts. Frequently, the presence of a sinus tract is associated with a necrotic pulp. [20]

Pain

Duration and type of pain for Pulpal will mostly be sharp and acute; a dull comfort is experienced in case of periodontal conditions. Pulp do not contain proprioceptive nerve fibres, whereas periodontal ligament does have them.

Pulp vitality

Non vital Pulpal pathology and vital is periodontal pathology. The most commonly used pulp vitality tests are cold test, electric test, blood flow tests and cavity test. The presence

or absence of vital tissue in a tooth with a single canal can be determined with confidence with the current pulp testing procedures. The same degree

of confidence cannot be ascribed to positive pulp test responses in a tooth with multiple canals. [20]

Palpation

This will detect the presence of periradicular abnormalities or “hot” zones that produce painful response to digital pressure.[22]

Percussion

Percuss the affected tooth in corono-apical direction for Pulpal and lateral for periodontal conditions.

Periodontal pockets

Pockets are purely related to periodontal diseases if the tooth is vital. If the tooth is non- vital, possibility of Pulpal involvement exists. Long and single, narrow pockets especially in a single tooth. Pockets that have multiple and wide entrance suggestive of periodontal origin.

Sinus tract

Intraorally , the opening is usually visible on the attached bucco gingival or in the vestibule. Fistula tracking is done by inserting a semi rigid radio opaque material into the sinus track until resistance is met. Commonly used materials include gutta-percha cones or pre-softened silver cones .A radiograph is then taken, which reveals the course of the sinus tract and the origin of the inflammatory process

Evaluation of the Periodontal status

Probing depth (PD)

The periodontal probe (PCP15 – HuFriedy, Chicago, IL, USA) was inserted parallel to the vertical axis of the tooth and run circumferentially

clockwise around each surface of the tooth, to detect the area of deepest penetration.[23]

Clinical attachment level (CAL)

The distance from the cemento enamel junction to the base of the pocket represents the CAL.

Plaque index (PI)

The buccal and lingual surfaces at the gingival margin of the teeth were scored according

to Silness & Loe (1964). The amount of plaque found was assigned a score of 0–3. A unique score was given, representing the surface (buccal or lingual) harbouring the greatest amount of plaque.

Tooth mobility

grade 0: normal mobility

grade I: slight mobility (less than 1 mm of movement facio-lingually)

grade II: moderate mobility (more than 1 mm facio-lingually with no vertical displacement)

grade III: severe mobility (more than 1 mm facio-lingually and/or mesio-distally, combined with vertical displacement).[23]

Furcation involvement

grade I: incipient inter radicular bone loss

grade II: partial inter radicular bone loss

grade III: total inter radicular bone loss with through-and-through opening of the furcation

grade IV: similar to grade III, but with gingival recession exposing the furcation. [24]

Mobility

Hyper mobility is quite common in cases of primary endodontic involvement and should not be confused with true mobility caused by periodontal destruction. In cases of primary endodontic pathology, the mobility resolves within a week of initiating endodontic therapy. [11]

Radiographic findings

Interpretation of discrete periapical or lateral lesions and discrete periodontal lesions is of clinical importance in suggesting the cause of the lesion and the proper diagnostic procedures to follow to confirm the cause. Often, the initial phases of periradicular bone resorption from endodontic origin are confined only to cancellous bone. Therefore, it cannot be detected unless the cortical bone is also affected. However, when there is radiographic evidence that bone loss extends from the level of crestal bone to or near the apex of the tooth, the radiograph is of little value in determining the cause. [20]

TREATMENT

The prognosis of Endo-Perio Lesions treatment depends on management of both endodontic and periodontic disease process, whether they exist alone or as a combined lesion. The treatment of endo - perio lesions can be emergency treatment and local treatment. The emergency includes control of pain and infection. In case of acute pulpitis with severe pain, the emergency treatment like pulpectomy preferred and if pain is mild due to periodontal origin analgesics preferred.

Infection control is achieved mainly by the use of antibiotics such as Penicillin and Erythromycin for endodontic origin and Chemo therapeutic agents for management of lesions of periodontal origin. [25]

Tetracyclines are effective against *A. actinomycetem comitans* and Metronidazole (750 – 1000 mg / day / 2 weeks) is effective against anaerobes, porphyromonas gingivalis, prevotella intermedia). The locally delivered antimicrobials are

1) Tetracycline – containing fibers (Nonresorbable fibers, diameter 0.5 mm containing tetracycline- 12.7 mg / 9 inches. It sustains tetracycline exceeding 1300 µg /ml for 10 days),

2) Sub gingival delivery of Doxycycline, (Biodegradable) Atridox incorporates the antibiotic doxycycline (10%) in a syringeable gel system,

3) sub gingival delivery system for Minocycline, 2% minocycline Hcl is available as a syringeable gel suspension system and

4) Sub gingival delivery of Metronidazole, 25% dental gel is applied in the periodontal pocket, where it is liquidized by body heat and then hardens again forming crystal in contact with water.

The local delivery of antiseptic agents is mainly by the use of a resorbable , small chip composed of a biodegradable hydrolyzed gelatin matrix cross linked with glutaraldehyde, glyusine and water into which 2.5 mg chlorhexidine gluconate is incorporated to maintain drug concentration in

gingival crevicular fluid greater than 100 ug / ml for 7 days.

Treatment of primary endodontic lesions- Simon et al proposed that root canal therapy should be performed with multiple appointments. Healing is rapid and is usually accomplished within 3-6 months. [13]

Treatment of primary endodontic lesion with secondary periodontal involvement requires both endodontic and periodontal treatment as there is pulpal involvement and presence of a periodontal pocket.[18]

Treatment of primary periodontal lesion needs sequence of treatment. If periodontitis progresses and periodontal pocket deepens, with continuous loss of attachment, surgical pocket eradication procedures are indicated.

Treatment of primary periodontal lesion with secondary endodontic involvement is managed as follows that if a tooth does not respond to periodontal therapy alone the possible presence of a necrotic pulp may be suspected then endodontic therapy must be done to support the periodontal therapy along with osseous surgery if any bony defect is present. [26]

True combined lesions are treated initially as for primary endodontic lesions with secondary periodontal involvement. Prior to surgery, palliative periodontal therapy should be completed and root canal treatment carried out on the roots to be saved. The prognosis of a true combined perio-endo lesion is often poor or even hopeless, especially when periodontal lesions are chronic,

with extensive loss of attachment. The prognosis of an affected tooth can also be improved by increasing bony support, which can be achieved by bone grafting and guided tissue regeneration. These advanced treatment options are based on responses to conventional periodontal and endodontic treatment over an extended time period. [3]

Alternative for endo-perio lesion management are resective approach / redesign of anatomical structures like Root amputation, Hemisection and Bicuspidization.[27]

Root amputation is done in advanced marginal periodontitis if left untreated for longer period of time and in cases of close root proximity the disto-buccal root of the maxillary first molar and the mesio buccal root of the second molar often tend to flare towards each other. Selective root removal allows the re-establishment of a proper embrasure area.

Root resection is one of the treatment modality in cases of endo- perio lesion especially when molars are involved. Root resection may be carried out as vital or nonvital procedures. If vital sectioning is employed provision for final endodontic therapy should be made, and in cases of non-vital root resection endodontic therapy should be done prior to surgery. The prognosis of root resection has been well- documented in research studies. Root-resection therapy is still a valid treatment option for molars with furcation involvement and severe bone loss. Root resection to treat periodontal problems showed a better prognosis than root resection performed for non periodontal purposes .

[28] Hemisection is the the treatment of choice in deep furcation involvements. Bicuspidization when there is a gross perforation in the furcation and close root proximity.

Various regenerative approaches for the management of endo-perio lesions includes the use of Tricalcium phosphate graft (TCP) Platelet Rich Plasma (PRP) and Guided tissue regeneration (GTR). Albee and Morrison noticed when **Tricalcium phosphate graft (TCP)** is placed in close to vital bone, ceramic matrix of the material serves as a carcass for bone formation. [29]

PLATELET RICH PLASMA (PRP)

It is a rich source of growth factors and is effective in inducing tissue repair and regeneration. autologous platelet concentrate is a very novel technique which has proved to be successful in the management of infrabony defects.

The effects of platelet concentrate have been examined *in vitro* and *in vivo*. In 1995, Slater *et al.* added human platelet concentrate to fetal calf serum medium containing human fetal osteoblasts. They demonstrated stimulated proliferation and maintained the differentiated function of the cells in tissue culture. Marx *et al.* added autologous platelet-rich plasma to cancellous cellular marrow bone grafts to repair mandibular discontinuity defects.[30]

Wound healing commences with hemostasis , which includes the formation of a fibrin clot, platelet adhesion, and aggregation. In the process

of aggregation, alpha granules of platelets release many mediators, including platelet-derived growth factor (PDGF) and transforming growth factor (TGF)- α and - β . These growth factors promote fibroblast chemotaxis (PDGF and TGF- β), proliferation (PDGF), contraction (PDGF), extracellular matrix deposition (TGF- β), and reepithelialization (TGF- α) in the healing wound.[1] Periodontal ligament fibroblasts, cementoblasts, and osteoblasts are affected similarly by these growth factors[4]

GUIDED TISSUE REGENERATION (GTR)

The barrier which prevents contact of connective tissue with the osseous walls of the defect, protecting the underlying blood clot and stabilizing the wound. Pecora Git™ is logical to use bioresorbable collagen and polymer membranes in endodontic surgeries because there is often no need for a second to retrieve the membrane. GTR therapy has been implemented in the endodontic surgeries as a concomitant treatment during the management of the endodontic-periodontal lesions.[31]

CALCIUM HYDROXIDE

Calcium hydroxide was originally introduced to the field of endodontics by Herman in 1930 as a pulp-capping agent, but its uses today are widespread in endodontic therapy. It is the most commonly used dressing for treatment of the vital pulp. It also plays a major role as an inter visit dressing in the disinfection of the root canal system. [32]

BIOACTIVE GLASS

A new property of osteo stimulation has been reported in some recently available materials. One of the case reports attempts to utilize a bioactive glass with the property of osteostimulation as a bone replacement graft in the treatment of a combined endo-perio lesion with furcation involvement.[33] that bioactive glass in the form of putty which was primarily due to 21% of glycerin added to 69% of bioactive glass and 10% of poly ethylene glycol, made it feasible for manipulation of the material and effective defect fill. Therefore within the limits of this study it can be concluded that bioactive glass is effective as a bone graft substitute in treatment of periodontal component of the endodontic lesion.[33]

Clinical studies with bioactive glass particulate have been gaining momentum in recent scenario. Bioactive glass shows both osteo conductive and osteo stimulatory effects. The pore size (90–710 μm) allows optimal space for vascularization. It enhances bone formation by ionic dissolution of the ceramic particles such that the silica gel layer forms over the particles on contact with body fluids. Over that silica gel layer, a calcium phosphate layer forms, which is quickly converted into a hydroxyl carbonate apatite layer. This apatite layer has been shown to be identical to bone mineral and to provide the surface for osteoblastic cell attachment and bone deposition. [34]

LASER

Treatment includes root canal therapy and routine non-surgical subgingival periodontal therapy using soft diode laser. The use of diode laser resulted in clinical attachment gain without affecting the soft tissue profile. Treatment of endo-perio lesions with a soft tissue diode laser is more effective and less traumatic than conventional surgical methods. These newer methods have enabled patients to extend their treatment options as well the clinician to learn newer techniques of treatment. Lasers have bactericidal effect and can be used effectively for disinfection of the root canal system following biomechanical instrumentation. These procedures can be performed with minimal postoperative challenges.[35]

CONCLUSION

The success of the concerned teeth depends upon the clinician knowledge about the endo perio lesions of different origin and identifying the different pathological patterns of same origin and co relating the accurate diagnostic findings between the clinical, radio graphical features and finally the selection of most appropriate treatment plan. Prognosis is based on clinician focus on infection control and patient response to the selected treatment protocols.

REFERENCES

[1] Ilan Rotstein & James H. Simon, The endo-perio lesion: a critical appraisal of the disease condition, *Endodontic Topics*, 2006;13: 34–56.

[2] Preetinder Singh, Endo – perio dilemma – A brief Review. *Dent Res J (Isfahan)*, 2011; 8(1): 39–47.

[3] Raja Sunitha V, Pamela Emmadi, Ambalavanan Namasivayam, Ramakrishnan Thyegarajan, and Vijayalakshmi Rajaraman, The periodontal –endodontic continuum: A Review, *J Conserv Dent.*, 2008 Apr-Jun; 11(2): 54–62.

[4] Singh S, Management of an endo perio lesion in a maxillary canine using platelet-rich plasma concentrate and an alloplastic bone substitute, *J Indian Soc Periodontol.*, 2009;May:13(2):97-100.

[5] Dr. syed wali peeran, madhumala thiruneervannan, khaled awidat abdalla, marei hamed mugrabi, Endo-perio lesions, *International journal of scientific & technology research*, may 2013: 2(5).

[6] Ten Cate A R, Oral histology, development, structure and function, 4th ed. Philadelphia: Mosby, 1994.

[7] Harrington GW, Steiner D, Periodontal-endodontic considerations. In: Walton RE, Torabinejad M, eds, *Principles and Practice of Endodontics*, 3rd edn. Philadelphia: W.B. Saunders, 2002: 466–484.

[8] Zehnder M, Gold SI, Hasselgren G, Pathologic interaction in pulpal and periodontal tissues, *J Clin Periodontol.* 2002; 29: 663–71.

[9] DeDeus QD, Frequency location and direction of the lateral, secondary and accessory canals, *J Endod*, 1975;1:361–6.

- [10] Vertucci FJ, Williams RJ, Furcation canals in the human mandibular first molars, *Oral Surg*, 1990;69:743.
- [11] Rotstein I, Simon JHS, Diagnosis, prognosis and decision making in the treatment of combined periodontal-endodontic lesions, *Journal of Periodontology*, 2000;34:265-303.
- [12] Hany Mohamed Aly Ahmed, Different perspectives in understanding the pulp and periodontal inter communications with a new proposed classification for endo – perio lesions, *ENDO (lond engl)*, 2012: 6(2):87-104.
- [13] Simon JH, Glick DH, Frank AL., The relationship of endodontic-periodontic lesions, *J Clin Periodontol*, 1972;43:202.
- [14] Czarnecki RT, Schilder H, A histological evaluation of the human pulp in teeth with varying degrees of periodontal disease., *J Endod*, 1979;5(8):242–53.
- [15] Soames J V, Southam J C, 3rd ed. Oxford: Oxford University Press, USA, *Oral pathology*, 1998.
- [16] Dr. d. p. das, dr. vishal singh ,Endo-perio lesion- the emerging new concepts, *Rujods, ranchi university*, 2013;2(1).
- [17] Seema Nayyar, Nidhi Aggarwal, Vikas Jindal, Jyotika Jain, The Endodontic-Periodontic Inter-Relationship - A Review; *Indian Journal of Dental Sciences*, December 2012 , Vol.:4(5).
- [18] Gargiulo Jr A, Endodontic-periodontic interrelationships, *Diagnosis and treatment*, *Dent Clin North Am*, 1984;28(4):767- 81.
- [19] Kerns DG, Glickman GN, Endodontic and periodontal interrelationships. In: Cohen S and Hargreaves KM, Eds. *Pathways of the pulp*, 9th Ed. St. Louis: Mosby Inc, 2006:650-67.
- [20] Nina Shenoy, Arvind Shenoy, Endo-perio lesions: Diagnosis and clinical considerations, *Indian J Dent Res*, 2010: 21(4).
- [21] Jenkins WM, Allan CJ, 3rd ed. California: Wright Publishing Company, *Guide to Periodontics*, 1994: 146–52.
- [22] Sigurdsson A, Pulpal diagnosis, *Endod Top*, 2003;5:12-25.
- [23] Carranza FA, Takei HH , Clinical diagnosis. In: Newman MG, Takei HH, Klokkevold PR, Carranza F, eds. *Carranza's Clinical Periodontology*, 10th edn. St. Louis, MO, USA: Saunders, Elsevier, 2006: 546; 548–58.
- [24] A. C. Didilescu¹, D. Rusu², A. Anghel², L. Nica², A. Iliescu¹, M. Greabu¹, G. Bancescu¹ & S. I. Stratul , Investigation of six selected bacterial species in endo-periodontal lesions, *International Endodontic Journal*, 2012;45: 282–293.
- [25] Bacić M, Karakas Z, Kaić Z, Sutalo J between palatal grooves in upper incisors and periodontal complications, *Journal of periodontology*, 1990;61(3):197-9.
- [26] Snyder B, Ryerson CC, Corona H, Grogan EA, Reynolds HS, Contestable PB, et al., Analytical performance of an immunologic-based periodontal bacterial test for simultaneous detection and differentiation of *Actinobacillus actinomycetemcomitans*, *Porphyromonas*

gingivalis, and Prevotella intermedia, Journal of periodontology. 1996;67(5):497-505.

[27] Harrington G, The perio-endo question: differential diagnosis, Dental Clinics of North America, 1979;23(4):673.

[28] Nitin H. Dani, Shahabe A. Saquib, Root Resection: A Treatment Modality For Endoperio Lesions, Indian Journal of Dental Sciences, 2012;4(3).

[29] Arvind Arora, Vinita Goyal, Vineet Sharma, Madhu Gupta, Vjita Mehta, Fundamentals in Treatment of Endo-Perio Lesions-A Review, International journal of dental clinics, 2012, vol4 issue 1.

[30] Marx RE, Carlson ER, Eichstaedt RM, Schimmele SR, Straus JE, Georgeff KR, et al., Platelet-rich plasma growth factor enhancement for bone grafts, Oral Surg oral Med oral pathol oral radiol endod, 1998;85:638-46.

[31] Verma, et al, Combined endodontic - Periodontal lesion - A clinical dilemma, Journal of Interdisciplinary Dentistry , Jul-Dec 2011 :vol 1(2).

[32] P. Carrotte, Calcium hydroxide, root resorption, endo-perio lesions , British Dental Journal , 2004: 197: 735-743.

[33] Sumit Narang, Anu Narang, and Ruby Gupta ,A sequential approach in treatment of perio-endo lesion, J Indian Soc Periodontol, 2011 Apr-Jun: 15(2): 177-180.

[34] Louis FR, Brian M, Robert G., Mosby, Text Book Of Periodontics: Medicine, Surgery and Implants Elsevier, 2004: p. 586.

[35] Mithra, N. Hegde, Nidarsh D. Hegde, Nagesh. S.C, lasers in management of endo-perio lesion – a case report, AOSR 2011;1(4):215-218.