



## A Comparative Study between Laparoscopic Varicocelectomy and Open Varicocelectomy in the Treatment of Varicocele

Authors

**Md. Atiqul Haque Sarder<sup>1\*</sup>, Muhammad Alom<sup>2</sup>, Sabran Uddin<sup>3</sup>**

<sup>1</sup>PCPS, MCPS, FACS, FICS, FMAS, Surgical Specialist, Department of Surgery Combined Military Hospital Bogura, Bangladesh

<sup>2</sup>PCPS, MCPS, FMAS, Surgical Specialist, Department of Surgery Combined Military Hospital Bogura, Bangladesh

<sup>3</sup>FCPS, Surgical Specialist, Department of Surgery, Combined Military Hospital Bogura, Bangladesh

Corresponding Author

**Md. Atiqul Haque Sarder**

### Abstract

**Background:** *Varicocele is a vein anomaly affecting 15% of adult males, with prevalence increasing to 35% in men seeking infertility evaluation and 81% in those with secondary infertility. It is primarily due to a prevalent and remediable factor.*

**Objective:** *The objective of this study is to do a comparative analysis of the post-operative outcomes between open inguinal varicocelectomy and laparoscopic varicocelectomy.*

**Methods:** *The present investigation was undertaken within the surgical department of (Hospital name) over a duration of two years, spanning from December 2019 to December 2021. This study employed a prospective design and involved the inclusion of a cohort comprising 50 patients diagnosed with clinically severe varicocele. The participants were allocated into two distinct groups. Group A consisted of 25 individuals who underwent laparoscopic surgery, while Group B consisted of 25 individuals who received an open approach.*

**Results:** *In our study comprising a cohort of 50 patients, we observed a range of ages from 20 to 49 years. Among these patients, 19 reported experiencing scrotal pain, 25 exhibited testicular swelling, and 7 presented with infertility. The mean operation time for laparoscopic varicocelectomy was 48 minutes, while for open surgery it was 57 minutes. Interestingly, we found that the postoperative analgesic requirement was similar in both groups. Furthermore, the average duration of hospital stay was 35.6 hours for laparoscopic procedures and 50.6 hours for open procedures. The duration of the operative procedure in Laparoscopic Varicocelectomy was found to be  $17.25 \pm 2.1$  minutes in cases where the condition was unilateral, whereas it was  $29.32 \pm 2.8$  minutes in situations where the condition was bilateral. The average length of surgery for unilateral cases in Open Varicocelectomy was found to be  $42.5 \pm 3.4$  minutes, whereas for bilateral presentations, it was  $67.25 \pm 2.5$  minutes. The observed difference between the two groups was found to be statistically significant, with a p-value of less than 0.001. The recurrence rate was higher in laparoscopic group.*

**Conclusion:** *Laparoscopic varicocelectomy offers similar outcomes to open techniques, with minimal morbidity and shorter hospitalization periods. It treats bilateral varicoceles without extra incisions and has a higher recurrence rate, but overall patient satisfaction makes it a preferred surgical technique.*

**Keywords:** *laparoscopic varicocelectomy, Open varicocelectomy, Infertility.*

## Introduction

Varicoceles are enlarged and twisted veins in the scrotum<sup>[1]</sup>. While around 15% of adult men have varicoceles, the condition is much more common in men experiencing infertility. Studies show that up to 35% of men seeking help with infertility and a significant 81% of men with secondary infertility (where a couple previously conceived but are now struggling) have varicoceles. These enlarged veins are more commonly found on the left side<sup>[2-4]</sup>. This condition is the most prevalent remediable factor contributing to male infertility. Multiple non-randomized investigations have indicated that the correction of a varicocele that is clinically detectable, when accompanied by aberrant semen analysis findings, leads to enhancements in parameters and rates of pregnancy. Many varicoceles don't cause symptoms and are often found during routine checkups, suggesting the condition might be more widespread than previously thought. Improved diagnostic tools like scrotal ultrasounds have also helped identify and understand varicoceles more effectively.

Varicoceles are clinically identified and graded according to the criteria established in 1970 by Dubin and Amelar. Varicocele of grade 1 can be detected through palpation exclusively when the individual is in an upright position and engages in the Valsalva manoeuvre. The palpability of Grade 2 can be observed even when the individual is in a resting position or when standing. The visibility of Grade 3 can be observed through the skin of the scrotum<sup>[5]</sup>.

Several techniques exist to treat varicoceles, including open surgery, injections (sclerotherapy), and minimally invasive laparoscopy. This study compared laparoscopy and traditional open surgery (high open ligation) for varicocele treatment, focusing on surgery duration, sperm quality (sperm parameters), and post-surgical complications.

## Objective

The objective of this study is to do a comparative analysis of the post-operative outcomes between open inguinal varicocelectomy and laparoscopic varicocelectomy.

## Materials and Methods

The present investigation was undertaken within the surgical department of (Hospital name) over a duration of two years, spanning from December 2019 to December 2021. This study recruited 50 patients with clinically severe varicoceles. We divided them into two groups of 25 each. One group received laparoscopic surgery (Group A), while the other group underwent open surgery (Group B). All participants had their diagnosis confirmed using Doppler ultrasound. This study comprised patients who had primary varicocele for a duration of more than one year, and exhibited clinically detectable varicocele of Grade II and III, or silent varicocele confirmed by Doppler ultrasound of Grade I. Exclusion criteria encompassed patients who presented with recurrent varicocele, secondary varicocele, undescended testis in conjunction, or a prior history of orchidopaxy. A comprehensive history and thorough examination were conducted. The study involved doing semen analysis on individuals who presented with infertility. This analysis was performed at least two times before the surgery and continued every six months for a duration of 18 months after the surgery.

## Surgical Procedure

### Laparoscopic Varicocelectomy

The patients underwent surgery while lying on their backs (supine) and were completely unconscious due to general anesthesia. A urine catheter was introduced subsequent to the administration of anesthesia to empty the bladder, or alternatively, the patient was instructed to urinate immediately prior to being transferred to the operating room. A nasogastric tube was inserted following induction in order to alleviate gastric distension. A Veress needle was utilized to establish pneumoperitoneum by inserting it

through a little infra-umbilical incision. Subsequently, the abdominal cavity was insufflated with carbon dioxide (CO<sub>2</sub>) gas, ensuring that the pressure was consistently maintained within the range of 12-14 mm Hg. The elevation of the head end of the bed was decreased by a range of 150 to 300 units in order to relocate the bowel away from the lower quadrants of the abdomen. The Veress needle was substituted with a 10 mm trocar and cannula subsequent to the expansion of the incision in the skin. A 10-millimeter telescope was introduced into the abdominal cavity by a 10-millimeter trocar. The 10 mm and 5 mm trocars were inserted bilaterally by incisions positioned at a distance of two-thirds from the umbilicus to the anterior superior iliac spine, while being seen directly. In this procedure, the peritoneum overlaying the internal spermatic veins was incised using a grasper and scissors, creating two perpendicular cuts. Surgeons carefully identified and separated the blood vessels (arteries and lymphatics) from the varicose veins. The varicose veins were then tied off using either clips or knots placed inside the abdomen (intracorporeal). Once bleeding was controlled (hemostasis), the surgical instruments (trocars) were removed, and the incisions were closed with stitches. The incisions were then dressed with antiseptic laparoscopic dressings.

### Open Surgery

During surgery to tie off the testicular veins high in the abdomen (open high ligation), patients received either spinal or general anesthesia. A minor surgical procedure involving the division of a tiny muscle at the anterior superior iliac spine was performed, allowing access to the

retroperitoneal area. The peritoneal envelope was then displaced towards the midline to locate the internal spermatic arteries. The vessels underwent ligation and division. Meticulous attention was given to the preservation of the testicular artery. The suturing of the external spermatic fascia was performed, followed by the closure of the wound in many layers. The application of the antimicrobial dressing was performed.

### Statistical Analysis

The database was created using the SPSS software, namely version 23. The quantitative factors, such as age, were represented by their mean  $\pm$  standard deviation values and were assessed using a student's t-test. The Chi-Square test of independence was utilized to examine the association between two qualitative variables, provided that it was appropriate. In cases where the conditions for the Chi-Square test were not met, the Fischer exact test was implemented instead.

### Results

The majority of patients fell within the age range of 20 to 29 years. In Group A, there is a representation of 17 individuals, which accounts for 68% of the total population. In Group B, there was a prevalence of 12 individuals, accounting for 48% of the total population. This was subsequently followed by individuals aged between 30 and 39 years. In Group A, 6 individuals, representing 24% of the total, were observed. In Group B, 8 individuals, accounting for 20% of the total, were observed. The average age of the participants was  $24.44 \pm 3.5$  years and  $23.32 \pm 4.1$  years, respectively. (Table 1)

**Table 1:** Age Distribution of the Study Patients

Age in years	Group A (Laparoscopic)		Group B (Open)	
	Frequency	Percentage	Frequency	Percentage
20-29	17	68%	12	48%
30-39	6	24%	8	32%
40-49	2	8%	5	20%
Mean $\pm$ Std	24.44 $\pm$ 3.5		23.32 $\pm$ 4.1	
Total	25	100%	25	100%

The indications for varicocelectomy were same across all groups and encompassed testicular enlargement, scrotal discomfort, and confirmed alterations in sperm parameters leading to infertility. The majority of instances observed bilateral varicocele in Group A, accounting for 15 cases or 60% of the total, while in Group B, 18 cases or 72% exhibited bilateral varicocele. The

grading of varicocele was determined by a combination of clinical examination and Doppler ultrasound. The most prevalent type of grade observed was Grade II, which was found in 19 patients (76%) in Group A and 17 patients (68%) in Group B. The comparison of these parameters in both groups is presented in Table 2.

**Table 2:** Clinical Presentation of the Study Patients

Variables	Group A (Laparoscopic)		Group B (Open)	
	Frequency	Percentage	Frequency	Percentage
<b>Presentations</b>				
Scrotal Pain	9	36%	10	40%
Testicular Swelling	13	52%	12	48%
Infertility	4	16%	3	12%
<b>Total</b>	<b>25</b>	<b>100%</b>	<b>25</b>	<b>100%</b>
<b>Varicocele Side</b>				
Unilateral	10	40%	7	28%
Bilateral	15	60%	18	72%
<b>Total</b>	<b>25</b>	<b>100%</b>	<b>25</b>	<b>100%</b>
<b>Grade</b>				
Grade I	2	8%	3	10%
Grade II	19	76%	17	68%
Grade III	4	16%	5	20%
<b>Total</b>	<b>25</b>	<b>100%</b>	<b>25</b>	<b>100%</b>

The analysis of operating time between the open and laparoscopic cohorts revealed a statistically significant reduction in duration for laparoscopy in cases of both unilateral and bilateral varicoceles. The duration of the operative procedure in Laparoscopic Varicocelectomy was found to be  $17.25 \pm 2.1$  minutes in cases where the condition was unilateral, whereas it was  $29.32 \pm 2.8$  minutes in situations where the condition was bilateral. The average length of surgery for

unilateral cases in Open Varicocelectomy was found to be  $42.5 \pm 3.4$  minutes, whereas for bilateral presentations, it was  $67.25 \pm 2.5$  minutes. The observed difference between the two groups was found to be statistically significant, with a p-value of less than 0.001. The comparison of postoperative hospital stay between the two groups likewise shown statistical significance. (Table 3)

**Table 3:** Operative and postoperative outcomes

Variables	Group A (Laparoscopic)	Group B (Open)	P value
<b>Mean ± Std Operative Times</b>			
Unilateral	$17.25 \pm 2.1$	$42.5 \pm 3.4$	0.001
Bilateral	$29.32 \pm 2.8$	$67.25 \pm 2.5$	
<b>Mean ± Std Hospital Stay (Days)</b>	$1.5 \pm 0.4$	$4.2 \pm 0.9$	0.001

More patients who underwent open surgery (6) experienced persistent pain compared to those who had laparoscopy (3). In both groups, some patients developed additional complications. One person in each group had scrotal swelling (edema), and two laparoscopic patients and one open surgery patient developed fluid collections around the testicles (hydrocele). These complications were treated with rest, pain medication (nonsteroidal anti-inflammatory drugs), and scrotal supports. A single instance of

recurrence was observed in the laparoscopic group, when patients had open Varicocelectomy while under general anesthesia. There were no instances of hernias observed following the laparoscopic varicocelectomy procedure. Within the cohort labeled as Group A, a total of two patients were identified as having contracted wound infections. It is worth noting that all instances of wound infection were effectively treated by the implementation of medical therapy. (Figure 1)

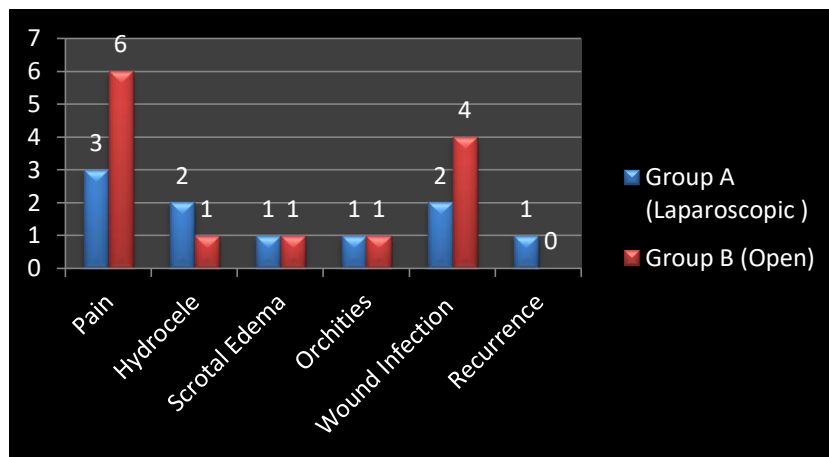


Figure 1: Varicocelectomy Complications with Different Surgical Methods

The analysis focused on evaluating and comparing the enhancement in semen quality in relation to the pre-operative semen analysis. A preoperative semen assay was conducted one week before to the surgical procedure, followed by a recommendation for a postoperative semen examination three months after the

varicocelectomy. Our study found a significant improvement in sperm quality after surgery. Sperm concentration increased by an average of 8 million per milliliter, motility improved by an average of 5.5%, and the percentage of abnormally shaped sperm decreased by 5%.

Table 4: Semen Analysis Report of Different Varicocelectomy Methods

Group A (Laparoscopic Method)	Before Treatment	After Treatment	Group B (Open Method)	Before Treatment	After Treatment
Sperm count × 10 <sup>6</sup> /ml	54 ± 38	46 ± 38	Sperm count × 10 <sup>6</sup> /ml	48 ± 35	42 ± 38
Sperm motility %	72 ± 52	90 ± 82	Sperm motility %	49 ± 35	62 ± 44
Sperm morphology %	62 ± 52	78 ± 36	Sperm morphology %	46 ± 41	53 ± 24

**Discussion**

Several techniques exist for treating varicocele. One of the earliest methods, described by Celsus in the 1st century, involved removing the affected testicle (ipsilateral orchidectomy)<sup>[6]</sup>. Laparoscopic

varicocelectomy, introduced by Winfield et al. in 1991, has become increasingly popular<sup>[7]</sup>. Studies suggest laparoscopy offers advantages like less tissue damage, reduced pain, and faster recovery, while maintaining effectiveness compared to open



surgery. However, the ideal balance between minimally invasive techniques and long-term success remains under investigation. This study compared open varicocelelectomy under general anesthesia (GA) with the laparoscopic approach.

In the present study the majority of the patients fell within the age range of 20 to 29 years for both groups. The average age of the participants was  $24.44 \pm 3.5$  years and  $23.32 \pm 4.1$  years, respectively. In a comparative study conducted by Bebars et al. the age of patients in laparoscopic group was 8–39 years (mean 21.3) and it was 8–42 years (mean 24.4) in open varicocelelectomy group<sup>[8]</sup>. The age range of patients was reported by Lynch WJ et al. In the open group, the age range was 25–48 years, whereas in the laparoscopic group, it was 23–49 years<sup>[9]</sup>. Hagood reported an age group ranging from 16 to 54 years<sup>[10]</sup>.

In our investigation involving a cohort of 50 individuals diagnosed with varicoceles, it was shown that 19 patients reported experiencing scrotal pain, while 25 patients exhibited testicular edema. Additionally, 7 patients presented with infertility. Similar findings were reported by Al-Shareef et al.<sup>[11]</sup> In the current investigation, it was reported that a total of nine individuals with varicoceles underwent treatment with laparoscopic closure of internal spermatic veins while under general anesthesia. A total of 12 individuals experienced symptoms of either scrotal discomfort or uncomfortable swelling, while an additional four patients exhibited signs of infertility.

In the conducted study, it was observed that 34% of the cases had unilateral varicocele, while the remaining 66% of patients presented with bilateral illness. Fifteen patients underwent laparoscopic surgery in a single session. This intervention demonstrated a high level of cost-effectiveness for both patients and healthcare providers.

The duration of the operative procedure in Laparoscopic Varicocelelectomy was found to be  $17.25 \pm 2.1$  minutes in cases where the condition was unilateral, whereas it was  $29.32 \pm 2.8$  minutes

in situations where the condition was bilateral. The average length of surgery for unilateral cases in Open Varicocelelectomy was found to be  $42.5 \pm 3.4$  minutes, whereas for bilateral presentations, it was  $67.25 \pm 2.5$  minutes. These differences were statistically significant ( $p$  value  $<0.001$ ). In a separate study, comparable findings were documented regarding the duration of unilateral laparoscopic varicocelelectomy, which averaged  $13.8 \pm 1.2$  minutes. Similarly, bilateral cases of laparoscopic varicocelelectomy exhibited a mean duration of  $17.3 \pm 1.7$  minutes. Conversely, unilateral open varicocelelectomy required a longer time period, with an average duration of  $27.55 \pm 2.05$  minutes, while bilateral cases of open varicocelelectomy took approximately  $49.7 \pm 3.50$  minutes. The observed differences exhibited statistical significance, as shown by a  $p$ -value of less than 0.001.<sup>[12]</sup>

Patients who underwent laparoscopic surgery stayed in the hospital for a much shorter time on average ( $1.5$  hours  $\pm 0.4$  hours) compared to those who had open surgery ( $4.2$  hours  $\pm 0.9$  hours).

In their study, Osman et al. found that the duration of postoperative hospitalization was 52 hours for the open varicocelelectomy group and 8.4 hours for the laparoscopic varicocelelectomy group<sup>[13]</sup>. In a study conducted by Podkamenev et al., it was observed that the mean duration of hospitalization for patients undergoing laparoscopic varicocelelectomy was 3 days, while those undergoing open varicocelelectomy had an average hospital stay of 7 days<sup>[14]</sup>. In their study, Ogura et al. also noted a significant difference in the duration of hospitalization between patients who underwent laparoscopic surgery and those who underwent open surgery, with laparoscopic patients having a shorter length of stay (0.97 days) compared to the open surgery group (1.42 days) ( $p = 0.0078$ )<sup>[15]</sup>.

The recurrence rate seen in our study was 4% in the laparoscopic group and 0% in the open group. A study saw a comparable rate of recurrence, with a reported recurrence rate of 5.6% following laparoscopic surgery<sup>[16]</sup>. Another study

demonstrated a recurrence rate of 4.65% in the laparoscopic group, while the open group exhibited a higher recurrence rate of 18.6%<sup>[17]</sup>.

Our study found a significant improvement in sperm quality after surgery, with an average increase of 8 million sperm per milliliter, a 5.5% improvement in motility, and a 5% decrease in abnormal shapes. These findings align with a previous study by Al-Kandari et al., who reported similar improvements in sperm motility or concentration across open, laparoscopic, and microsurgical groups (65%, 67%, and 76%, respectively)<sup>[18]</sup>. Additionally, their study showed no significant difference in pregnancy rates between the groups after one year (28%, 30%, and 40%).

### Conclusion

The study findings indicate that laparoscopic varicocelectomy yields similar outcomes to the open technique, while presenting little morbidity and shorter hospitalization periods. Additionally, the laparoscopic approach has the advantage of treating bilateral varicoceles without necessitating extra incisions. Although the laparoscopic procedure exhibited a greater recurrence rate, it is noteworthy that laparoscopic varicocelectomy yields superior overall patient satisfaction. Consequently, it can be regarded as a preferable surgical technique, despite the similarity in sperm analysis outcomes between the two methods.

### References

1. Choi WS, Kim SW. Current issues in varicocele management: a review. *World J Mens Health*. 2013 Apr;31(1):12-20.
2. Clarke BG. Incidence of varicocele in normal men and among men of different ages. *JAMA*. 1966 Dec 5;198(10):1121-1122.
3. Gorelick JI, Goldstein M. Loss of fertility in men with varicocele. *Fertil Steril*. March 1993;59:613-616.
4. Alsaikhan B, Alrabeeah K, Delouya G, Zini A. Epidemiology of varicocele. *Asian journal of andrology*. 2016 Mar;18(2): 179-181
5. Dubin L, Amelar RD. Varicocele size and results of varicocelectomy in selected subfertile men with varicocele. *Fertil Steril*. 1970;21:606-609.
6. Dubin L, Amelar RD. Varicocele. *Urol Clin North Am*. 1978;5:563-572.
7. Hargreave TB. Varicocele: A clinical enigma. *Br J Urol*. 1993 Oct;72(4):401-408.
8. Bebars GA, et al. Laparoscopic versus open high ligation of the testicular veins for the treatment of varicocele. *JSLs*. 2000 Jul-Sep; 4(3): 209-213
9. Lynch W J, Badenoch D F and Mcanena O J Comparison of Laparoscopic and open ligation of the testicular veins. *British Journal of Urology* dec 1993;72:796-798.
10. Hagood PG, Mehan DJ, Worischek JH, et al. Laparoscopic varicocelectomy: preliminary report of a new technique. *J Urol* Jan1992;147:73-76.
11. Al-Shareef ZH, Koneru SR, Al-Tayeb A, Shehata ZM, Aly TF, Basyouni A. Laparoscopic ligation of varicoceles: an anatomically superior operation. *Annals of the Royal College of Surgeons of England*. 1993 Sep;75(5):345-348.
12. Verma D, Lal C, Sharma A, Sirwi M. Laparoscopic versus open surgical management of idiopathic varicocele: a study on 100 patients. *Int Surg J* 2017;4:3071-6.
13. Osman T, El-Shourbagy A, Moustafa H, Maged W. Laparoscopic versus Open Retroperitoneal Bilateral Varix Ligation for Obese Patients Presenting with Primary Sub-Fertility: A Randomized Comparative Study. *African Journal of Urology*. 2004;10(1):50-57.
14. Podkamenev VV, Stalmakhovich VN, Urkov PS, Solovjev AA, Iljin VP. Laparoscopic surgery for pediatric varicoceles: randomized controlled trial.

Journal of pediatric surgery. 2002 May 1;37(5):727-729.

15. Ogura K, Matsuda T, Terachi T, Horii Y, Takeuchi H, Yoshida O. Laparoscopic varicocelectomy: invasiveness and effectiveness compared with conventional open retroperitoneal high ligation. International Journal of Urology. 1994 Mar;1(1):62-66.
16. Farag, A., Abo-Elsaad, A., Ahmed, Y., Azzam, A. Laparoscopic varicocelectomy initial experience at Al\_Azhar Hospital (Demietta). The Egyptian Journal of Hospital Medicine, 2018; 73(11): 8077-8083. doi: 10.21608/ejhm.2018.21923
17. Saeed AB, Ahmed S, Iqbal J. Comparison of surgical techniques used in adult varicocele. JSZMC 2017;8(1):1101- 1104.
18. Al-Kandari AM, Shabaan H, Ibrahim HM, Elshebiny YH, Shokeir AA. Comparison of outcomes of different varicocelectomy techniques: open inguinal, laparoscopic, and subinguinal microscopic varicocelectomy: a randomized clinical trial. Urology. 2007 Mar 1;69(3):417-420.