



Malignant Leydig Cell Tumor of Testis: Case Report

Authors

**Dr Himani Thakur¹, Dr Sarita Asotra^{2*}, Dr Kavita Mardi³,
Dr Kailash Mohan Bhandari⁴, Dr Kavita Kumari⁵**

¹Junior Resident, Department of Pathology, IGMC Shimla

^{2,3}Professor, Department of Pathology, IGMC Shimla

⁴Junior Resident, Department of Pathology, IGMC Shimla

⁵Assistant Professor, Department of Pathology, Dr. RKGMC Hamirpur

*Corresponding Author

Dr Sarita Asotra

Professor Department of Pathology IGMC Shimla, India

Abstract

Testicular tumors accounts for % of the tumors in men. 5% of which are the sex cord stromal tumors and the remaining are of germ cell origin. Leydig cell are the common subtype of Sex cord stromal tumors and accounts for 1%-2% of all the testicular tumors. Tumor arises from the leydig cells that normally reside in the interstitium of testicles and secrete testosterone in the presence of leutenizing hormone. They show a bimodal distribution with peaks in the prepubertal age group and between 30-60yrs of age. Leydig cell tumor being a hormonally active tumor often presents with precocious puberty, breast tenderness and gynaecomastia. Histopathology reveals a well circumscribed mass .Cut surface shows golden brown homogenous appearance. Microscopically, tumor cells are large to polygonal with round to oval nucleus with deeply granular cytoplasm. Cytoplasm shows characteristics rod sghaped crystals referred to as “crystalloids of Reinke”. Leydig cell tumors are mostly follow a benign course but approximately 5-10% of these have malignant potential. Regional lymph nodes, lungs , liver and bones are the commonest sites of metastasis. Due to aggressive difficult to treat nature of metastatic disease it is essential to differentiate benign leydig cell tumor from its malignant counterpart in order to guide its initial surgical and radiological management. Assessment of the clinicopathological features of Leydig cell tumor allows for its optimal management.

Introduction

Leydig cell tumor is a rare subtype of testicular tumors arising from gonadal stroma and accounts for 1-3% of all testicular tumors in adults and 4% in prepubertal children.¹ Leydig cell tumors arise

from the leydig cells present in the interstitium of the testis and secrete testosterone in the presence of leutenizing hormone.² They are typically benign tumors with 5%-10% malignant potential.³ They show 2 peaks of incidence in the prepubertal

age group and in adults at 30-60yrs of age.⁴ Leydig cell tumors are asymptomatic in most of the cases or may present in a variety of ways from benign to locally invasive to metastatic disease⁵. There is rise in the incidence of testicular tumors in the last few years (14.7%) well above the literature predictions. Advancement in ultrasound technology results in the early detection of small testicular nodule that were not previously detected.¹ Here, we present a case of malignant leydig cell tumor of the right testis.

Case Report

A 56 year old male presented to the surgical department of our hospital with chief complaint of right scrotal swelling since 3 months. On local examination the swelling was hard and variegated. On ultrasonographic examination, a solid hypoechoic mass was found in the right testis of size(4.6x3x3)cm along with hydrocoele. Serum tumor markers such as alpha feto protein, HCG and LDH were done and were found to be within normal range. Right side high inguinal orchitectomy of the patient was done and sent for histopathological evaluation. Grossly, it was an encapsulated tumor of size (4.5x3.5x2)cm with a bossellated outer surface. Cut surface of the was tan yellow to tan brown in colour . Microscopic examination of the tumor shows sheets and cords of uniform polygonal tumor cells with round nuclei, conspicuous nucleoli, abundant granular eosinophilic cytoplasm, lipofuscin pigment, reinke's crystalloids. Tumor cells were infiltrating the seminiferous tubules, tunica albugenia and there was lymphovascular invasion and mitotic index of 4/10 HPF. All these features were suggestive of malignant leydig cell tumor of testis. Immunohistochemical studies reveal diffuse strong cytoplasmic positivity for Melan A and calretinin. Synaptophysin,S-100 and calretinin shows focal positivity. On the basis of clinical presentation, biochemical profile, histopathological and immunohistochemical findings the diagnosis of malignant leydig cell tumor of the right testis was made.

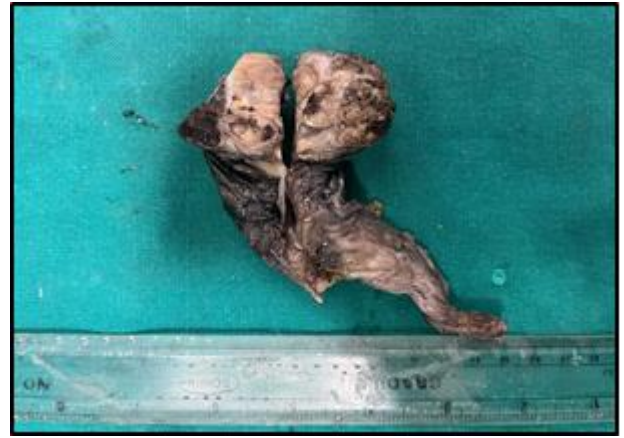

Fig. A) Gross photograph showing right orchidectomy specimen revealing multiple tumor nodules separated by fibrous septae

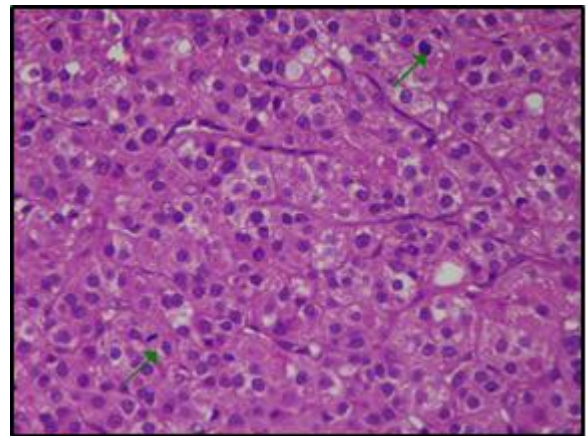


Fig B) Nests of polygonal tumor cells with central nuclei, abundant granular eosinophilic cytoplasm, prominent nucleoli and atypical mitotic figures, (Hematoxylin & eosin, 40X)

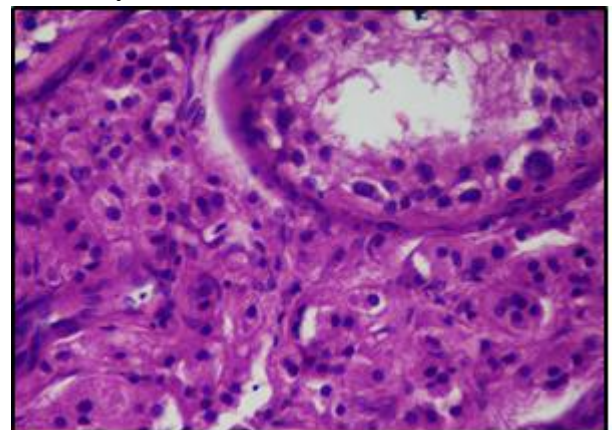


Fig. C) Tumor cells infiltrating between seminiferous tubules, (Haematoxylin & eosin, 40X)

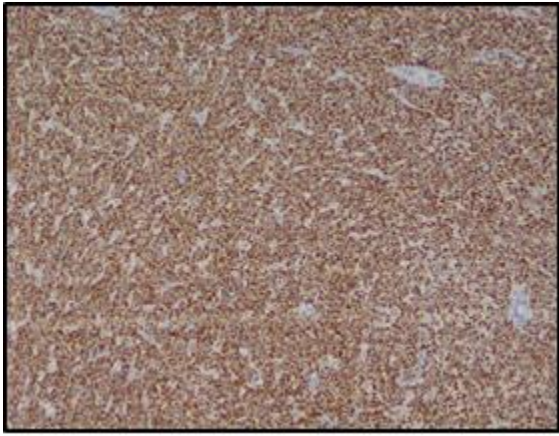


Fig. D) Strong diffuse cytoplasmic positivity of Melan A in tumor cells, (IHC 10X)

Discussion

Primary tumors of the testis are rare and accounts for 1%- 1.5% of all the tumors in men³. Germ cell tumors and sex cord/stromal tumors are the two members of the primary testicular tumors⁶. Among the sex cord/stromal tumors, Leydig cell tumors are the most common histological type and accounts for 1% o 3% of all testicular tumors of adults.⁷ LCT are mostly unilateral however 3-10% of them show bilaterality and 10% are malignant with metastatic potential. Leydig cell tumor arise from the leydig cells of the testis in most of the cases, rarely it may originate from epididymis².

These tumors have bimodal distribution with 2 peaks of incidence in prepubertal boys at 5-10 yrs of age and other peak in adults at 30-60 yrs of age⁸. In our case tumor was unilateral in the right testis and the patient belongs to the age group with the highest incidence. These tumors are found incidentally on ultrasonographic examination done for other conditions. Clinically they present with a testicular mass along with varied degree of symptoms such as pain in testis, enlargement of testicle, heaviness in scrotum and gynaecomastia. Infertility and azoospermia are rarely seen but if present they are reversible after surgery⁴. Hormonal disorder are associated with the increased production of testosterone and estrogen by the tumor.¹

The pathogenesis of leydig cell tumor is poorly understood. Excessive proliferation of the leydig cells due to excessive stimulation by the leutinizing hormone resulting from disruption of the hypothalmo-pituitary-testicular axis thoght to play a role⁷. Mutations in the guanine nucleotide binding protein alpha gene causes adult leydig cell tumor.³

Testicular tumor are readily identified on scrotal ultrasound and shows a hypoechoic mass with a heterogenous enhancement pattern or peripheral hypervascularity.³ MRI is superior to ultrasonography in diagnosing testicular lesions; marked and maintained enhancement is characteristic sign to differentiate Leydig cell tumor from other testicular tumors.⁴ CT scan of the abdomen & pelvis is done in cases of malignancy to rule out metastasis. In our case scrotal ultrasound revealed a non homogenous hypoechoic mass in the right testis measuring (4.6x3x3)cm.

Blood investigations for tumor markers such as AFP, beta hCG & LDH are usually negative¹. Hormones secreted by the leydig cell tumors are testosterone and estrogens². Most of the cases Leydig cell tumor present as a non functional testicular mass. Leydig cell tumor arises from the interstitial leydig cell adjacent to the seminiferous tubules.

Histopathological and immunohistochemical findings are essential for diagnosis of Leydig cell tumor. Grossly, Leydig cell tumor resent as a well circumscribed lesion in testis. Cut surface shows a characteristic golden brown or homogenous yellow to light brown appearance.² Histopathologically, Leydig cell tumor is characterized by sheetsand nests of large polygonal tumor cells with round to oval nucleus, conspicuous nucleoli, granular eosinophilic cytoplasm, rod shaped cyrstal present in the cytoplasm known as “crystalloids of Reinke” seen in 35% of the tumors and lipofuscin pigment seen 10% to15% of the cases.Reinke’s crytals are typical of leydig cell but do not indicate neoplasia⁸ On immunohistochemistry, Leydig cell tumor shows uniform positivity for inhibin and

Melan A with variable positivity for calretinin and vimentin. Negative immunostaining for LDH, AFP & HCG helps to distinguish Leydig cell tumor from germ cell tumors of testis⁵. In our case, tumor cells were positive for Melan A and calretinin and there was focal immunoreactivity for cytokeratin, S-100 and no immunoreactivity for CD marker and HCG.

10% of the cases of leydig cell tumor have malignant potential with metastasis to retroperitoneal and inguinal lymph nodes (70%), liver (45%) , lungs(40%) and bones (25%)⁸. Metastasis is more common in patients above 40 yrs of age¹⁰. In our case clinical, hormonal, radiological, histopathological and immunohistochemical findings have supported the diagnosis of malignant leydig cell tumor.

Leydig cell tumors are rarely malignant and their malignant potential increases with increased age of patient, presence of endocrine changes, tumor size (>5cm), mitotic index, infiltrative margins areas of hemorrhage and necrosis extending beyond testicular parenchyma as in our case⁹.

Surgical excision remains the mainstay of treatment for both benign and malignant Leydig cell tumor.³ Poor response to additional chemotherapy and radiotherapy has been observed in metastatic Leydig cell tumor. Regular follow up is required to exclude recurrence or metastasis⁹. In our case, resection margins were negative and there was no evidence of metastasis so no further management was suggested.

Conclusions

Leydig cell tumor are uncommon neoplasm arising from gonadal stroma. It is important for pathologist to keep the possibility of this rare tumor while diagnosing a case of testicular tumor. Complications from this disease arise mostly from delays in diagnosis and treatment. Hence, it is essential to differentiate benign Leydig cell tumor from its malignant counterpart on the basis of histopathological features to allow for optimal management.

References

1. Zhu J, Luan Y, Li H. Management of testicular Leydig cell tumor: a case report. *Medicine*. 2018 Jun;97(25).
2. Pomajzl AJ, Siref LE. Leydig Cell Cancer.
3. David J, Chumbalkar V, Chadha J. An insight into metastatic Leydig cell tumors: A case report. *SAGE Open Medical Case Reports*. 2023 Jul;11:2050313X231184180.
4. Carroll HK, Nolis T, Darwish W, Harrison M, McCaffrey JA. Leydig cell tumours: a case series from a single Irish centre. *SN Comprehensive Clinical Medicine*. 2021 Jun;3:1307-12.
5. Gheorghisan-Galateanu AA. Leydig cell tumors of the testis: a case report. *BMC Research Notes*. 2014 Dec;7:1-6.
6. Al-Agha OM, Axiotis CA. An in-depth look at Leydig cell tumor of the testis. *Archives of pathology & laboratory medicine*. 2007 Feb 1;131(2):311-7.
7. Leonhartsberger N, Ramoner R, Aigner F, Stoehr B, Pichler R, Zangerl F, Fritzer A, Steiner H. Increased incidence of Leydig cell tumours of the testis in the era of improved imaging techniques. *BJU international*. 2011 Nov;108(10):1603-7.
8. Damjanov IV, Katz SM, Jewett MA. Leydig cell tumors of the testis. *Annals of Clinical & Laboratory Science*. 1979 Mar 1;9(2):157-63.
9. Mati W, Lam G, Dahl C, Andersen JT, Balslev E. Leydig cell tumour—a rare testicular tumour. *International urology and nephrology*. 2002 Mar;33:103-5.
10. Grem JL, Robins HI, Wilson KS, Gilchrist K, Trump DL. Metastatic leydig cell tumor of the testis report of three cases and review of the literature. *Cancer*. 1986 Nov 1;58(9):2116-9.