



Post Percutaneous Transluminal Coronary Angioplasty (PTCA) Coronary Aneurysm- A Case Report

Authors

Dr Sandipta Ray¹, Dr. Mainak Mukhopadhyay²

^{1,2}Consultant Interventional Cardiologist, Department of Cardiology, AMRI Hospitals, Saltlake Kolkata

Introduction

Coronary aneurysm defined angiographically as luminal dilation 50% larger than that of the adjacent reference segment.⁽¹⁾

Drug-eluting stents (DES), which locally elute antiproliferative drugs, can dramatically inhibit neointimal growth. However, several pathological studies have indicated that DES may delay healing after vascular injury, and DES implantation may be theoretically associated with a risk of coronary artery aneurysm formation. Coronary aneurysms have been reported from 3 days to up to 4 years after DES implantation procedures, with varying clinical presentations. The incidence of coronary artery aneurysms after DES implantation is low within the first 9 months, with a reported incidence of 0.2% to 2.3%, a rate similar to that reported after bare-metal stent (BMS) implantation (0.3% to 3.9%) in the DES versus BMS randomized trials.⁽²⁾

However, the true incidence of coronary aneurysms in an unselected patient population is still largely unknown. It can be congenital, or secondary to vasculitis (Kawasaki disease) or after percutaneous coronary intervention. Drug-eluting

stents (DES), which locally elute antiproliferative drugs, can dramatically inhibit neointimal growth has become standard of care for routine coronary angioplasty. However, several pathological studies have indicated that DES may delay endothelial healing after vascular injury, and DES implantation may be theoretically associated with a risk of coronary artery aneurysm formation⁽³⁾

Coronary aneurysms have been reported from 3 days to up to 4 years after DES implantation. The incidence of coronary artery aneurysms after DES implantation is low within the first 9 months, with a reported incidence of 0.2% to 2.3%, a rate similar to that reported after bare-metal stent (BMS) implantation (0.3% to 3.9%) in the DES versus BMS randomized trials. However, the true incidence of coronary aneurysm is still largely unknown. Majority of coronary aneurysm are pseudoaneurysm.⁽⁴⁾

Generally they are asymptomatic diagnosed incidentally. Some presents with feature of heart failure, coronary steal phenomenon and very rarely with atypical symptoms like hemoptysis. CT coronary angiogram is better diagnostic tool for anatomical details.

Case Summary

A 47 year gentleman, diabetic, chronic smoker, hypertensive presented with High grade stable angina for 6 months. Baseline ECG shows lateral wall ischaemia. Echocardiography was normal with Left ventricular ejection fraction (LVEF) of 61%. Coronary angiogram reveals Triple Vessel Disease (TVD) with a Syntax score of 22. After discussion with heart team patient was taken for Percutaneous coronary Intervention (PCI). Left circumflex artery (LCX) was stented with 2.75x32 DES. Left anterior descending artery (LAD)stented with 2.75x40 mm DES, post dilated with 3x12 balloon at 14 atmosphere. 10 days later Right coronary artery (RCA) was stented with 3x24 mm DES. While taking Check angiogram of the left coronary system a moderate size coronary aneurysm was detected. Coronary aneurysm was originating from the proximal part of the LAD stent. Size and location of the coronary aneurysm was assessed with multiple angiographic view. (Figure 1 and 2)

To assess the vessel diameter, exact origin of aneurysm and identification of the neck of the aneurysm we decided to perform intracoronary imaging.

We did an Optical Coherence Tomography (OCT) run from the distal LAD segment. LAD stent was well apposed distally and proximally aneurysm was visible with floated mal-apposed stent struts. (Figure 3 and 4)

After discussion with Cardiothoracic Surgeon we decided to put a Cover stent across the aneurysmal segment. Graft Master (2.8x19 mm) deployed across the aneurysm segment of the LAD stent. Cover stent was optimized with 3.5 non compliant (NC) balloon. We achieved distal TIMI 3 flow with almost disappearance of the coronary aneurysm. (Figure 5)

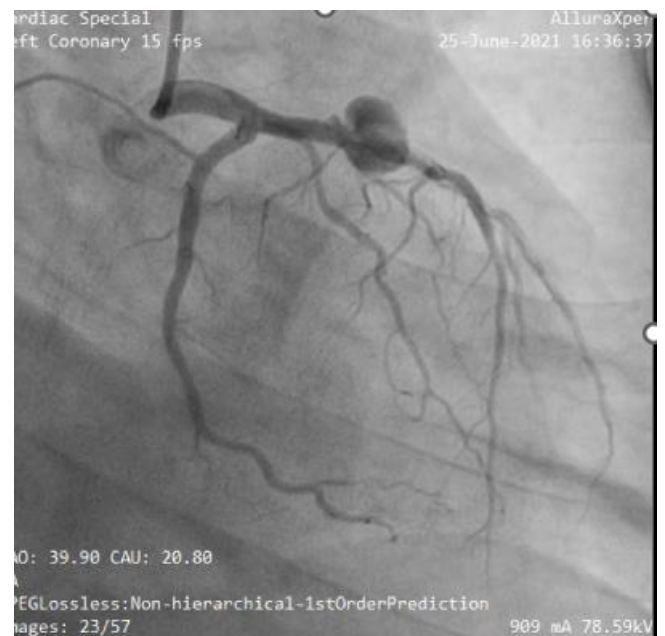


Figure 1 RAO caudal view showing large coronary aneurysm at the junction of proximal and mid LAD

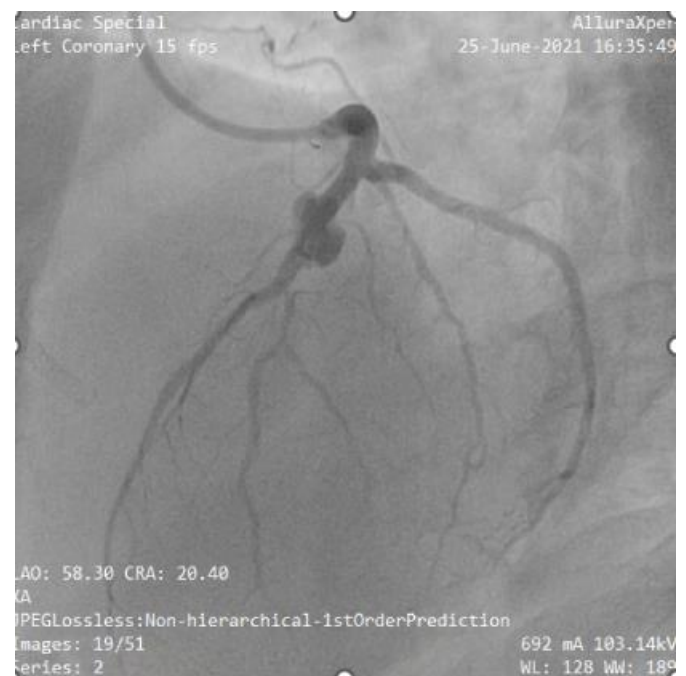


Figure 2 same coronary aneurysm in LAO cranial view

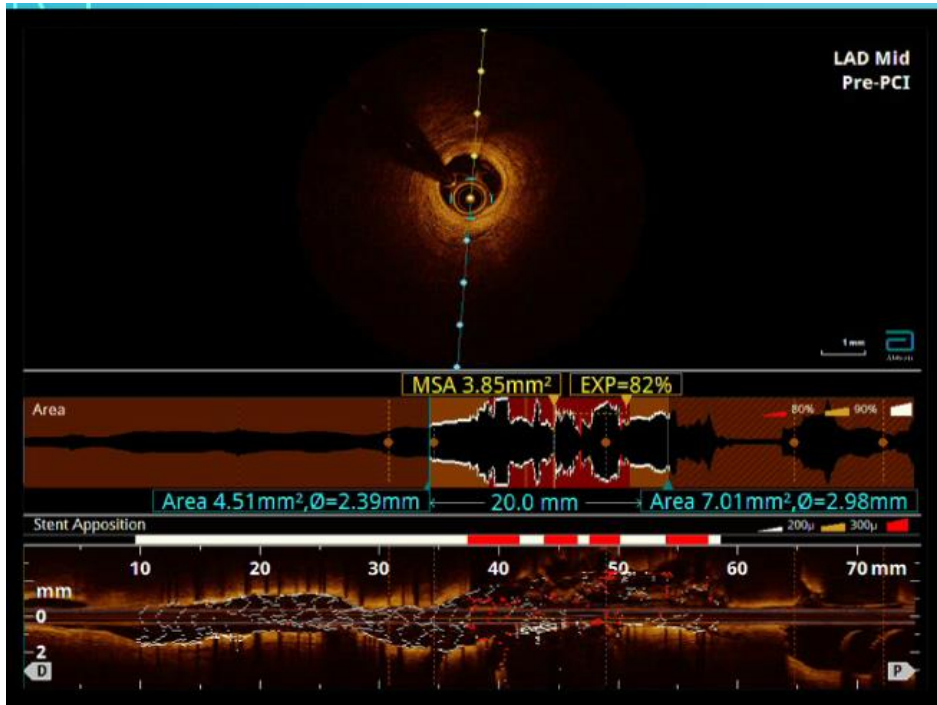


Figure 3 OCT run in mid LAD showing underexpanded stent

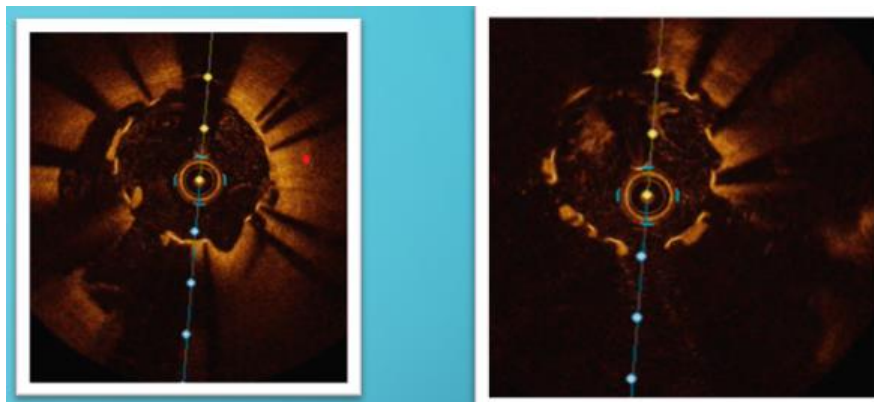


Figure 4 OCT shows giant coronary aneurysm

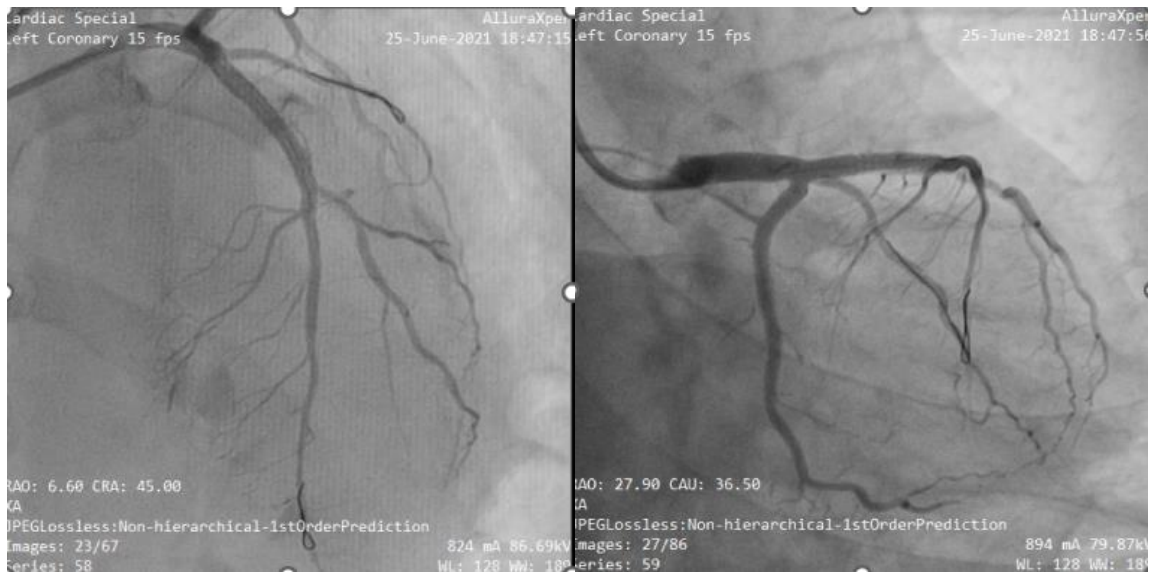
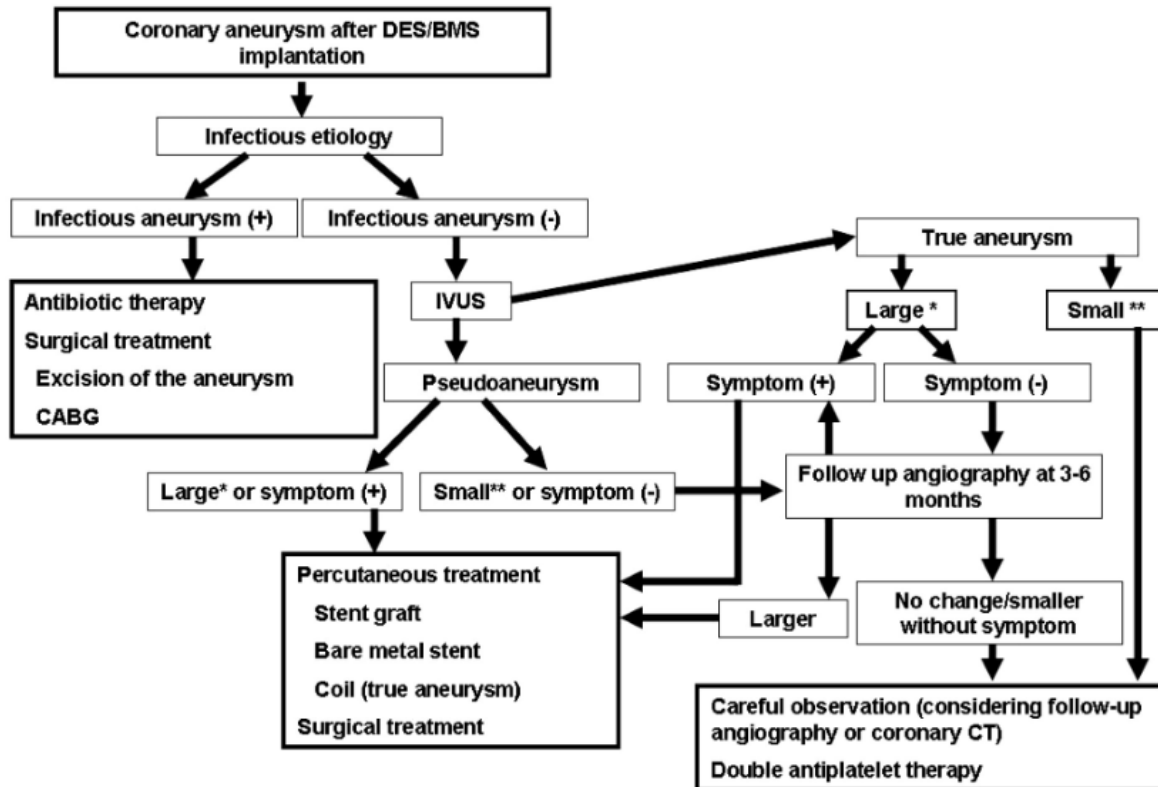


Figure 5 – Final angiographic view after placement of cover stent (AP cranial and RAO caudal view)

Treatment algorithm for coronary aneurysm



Discussion

Coronary aneurysm generally results from vasculitis like Kawasaki Disease, Poly arteritis nodosa, giant cell arteritis. In recent era due to high number of coronary angioplasties, incidence of iatrogenic coronary aneurysm is on rise. Incidence is 2-10% as reported in different literature globally. Complex angioplasties, use of rotablation, coronary wire induced trauma may lead to this type of coronary aneurysm immediately after coronary angioplasty. Endothelial damage particularly paclitaxel mediated damage of vascular lamina remains the main proposed mechanism. Mechanically induced trauma to coronary bed, mal-apposition of stent, micro-dissection are the other contributory factors. Type I aneurysm is a type of aneurysm that demonstrates rapid early growth with formation of pseudoaneurysm detected within 4 weeks. Given the rapid time course of aneurysm formation, it is likely that vessel damage related to the procedure is the likely contributor to aneurysm formation in

these cases rather than the chronic arterial response to the stent, polymer, and drug.⁽⁵⁾ Type 2 aneurysm do have a subacute or chronic presentation (more than 6 weeks). These aneurysms are largely asymptomatic.⁽⁶⁾ Type 3 coronary aneurysm is mycotic or infective. Staphylococcus aureus is the most common organism. Patient may present with fever and other systemic symptoms.⁽⁷⁾ Majority of these coronary aneurysm does not require treatment as they are largely asymptomatic. Sometimes they get infected leading to formation of mycotic aneurysm. It is one of the dreaded complication, can be fatal and need to be managed aggressively. Some aneurysm may expand rapidly leading to need for an early surgery. Treatment of coronary aneurysm remains controversial. Many patients are treated conservatively. Surgery remains the gold standard as treatment modality for coronary aneurysm particularly if it is medium to large in size.

Use of cover stent is one of the viable option to treat these type of lesion. main disadvantage of cover stent is side branch compromise along with increase risk of stent failure due to closed cell design and high metal burden.

In our case we were able to cover the aneurysm percutaneously with cover stent (Graft Master). With the steady increase in Post PTCA coronary aneurysm globally, cover stent should be considered as an attractive alternative where it is feasible technically.

Learning Objectives

In our case coronary aneurysm is formed very rapidly after DES implantation (within 10 days only)

OCT image shows under expanded LAD stent (may be the reason for aneurysm formation)

It was successfully covered by using cover stent (Graft master) instead of surgery.

CT coronary angiogram should be considered for better evaluation.

Treatment decision has to be a Heart team approach for better long term result.

Reference

1. P.A. Slota, D.L. Fischman, M.P. Savage, R Rake, S. Goldberg Frequency and outcome of development of coronary artery aneurysm after intracoronary stent placement and angioplasty: STRESS Trial Investigators .Am J Cardiol, 79 (1997), pp. 1104-1106
2. J.J. Popma, M.B. Leon, J.W. Moses, *et al.* Quantitative assessment of angiographic restenosis after sirolimus-eluting stent implantation in native coronary arteries Circulation, 110 (2004), pp. 3773-3780
3. R. Virmani, G. Guagliumi, A. Farb, *et al.* Localized hypersensitivity and late coronary thrombosis secondary to a sirolimus-eluting stent: should we be

cautious? Circulation, 109 (2004), pp. 701-705

4. M.R. Bell, K.N. Garratt, J.F. Bresnahan, W.D. Edwards, D.R. Holmes Jr Relation of deep arterial resection and coronary artery aneurysms after directional coronary atherectomy J Am Coll Cardiol, 20 (1992), pp. 1474-1481.
5. R.K. Gupta, R. Sapra, U. Kaul Early aneurysm formation after drug-eluting stent implantation: an unusual life-threatening complication J Invasive Cardiol, 18 (2006), pp. E140-E142
6. H. Nohara, T. Shida, N. Mukohara, H. Ob o, M. Yoshida A case of the coronary artery aneurysm including stent device after percutaneous coronary intervention Ann Thorac Cardiovasc Surg, 10 (2004), pp. 202-204.
7. O. Leroy, E. Martin, A. Prat, *et al.* Fatal infection of coronary stent implantation Cathet Cardiovasc Diagn, 39 (1996), pp. 168-170.