



Mediastinal Tuberculosis with Sternal Encroachment - A Rare Presentation of Tuberculosis

Authors

**Dr Hidayath Hussain¹, Dr B Namratha Sai Reddy², Dr Sindhu Pericherla³,
Dr RJ Bhavna Srivastav⁴**

¹Professor and HOD in Pulmonology- Dr VRK Women's Medical College, Teaching Hospital and Research Centre, Consultant Pulmonologist, Omega Hospital, Gachibowli

²MD, DNB (Medical Oncology), Omega Hospital, Gachibowli

³MD, DM (Medical Oncology), Omega Hospital, Gachibowli

⁴Third year Post graduate in Pulmonology, Dr VRK Women's Medical College, Teaching Hospital and Research Centre

Corresponding Author

Dr RJ Bhavna Srivastav

Introduction

Extra-pulmonary tuberculosis constitutes 15-20% of the total tuberculosis (TB) caseload in immunocompetent patients. Affliction of the skeletal system is rare with still rarer presentation of sternal tuberculosis.

Sternum is one of the least common bones of the body to get infected ⁽¹⁾

Sternal TB is predominantly seen in middle-aged adults although no age is immune and it has also been reported in an infant. It can arise primarily due to a hematogenous route or direct extension from the hilar lymph nodes and/or could be due to lymphatic dissemination⁽²⁾. Sternal tuberculosis has also been reported after BCG vaccination in the pediatric age group ⁽³⁻⁵⁾

Here we present an unusual case of tuberculosis of the sternum, which presented with swelling and pain in the chest in a 9 year old boy.

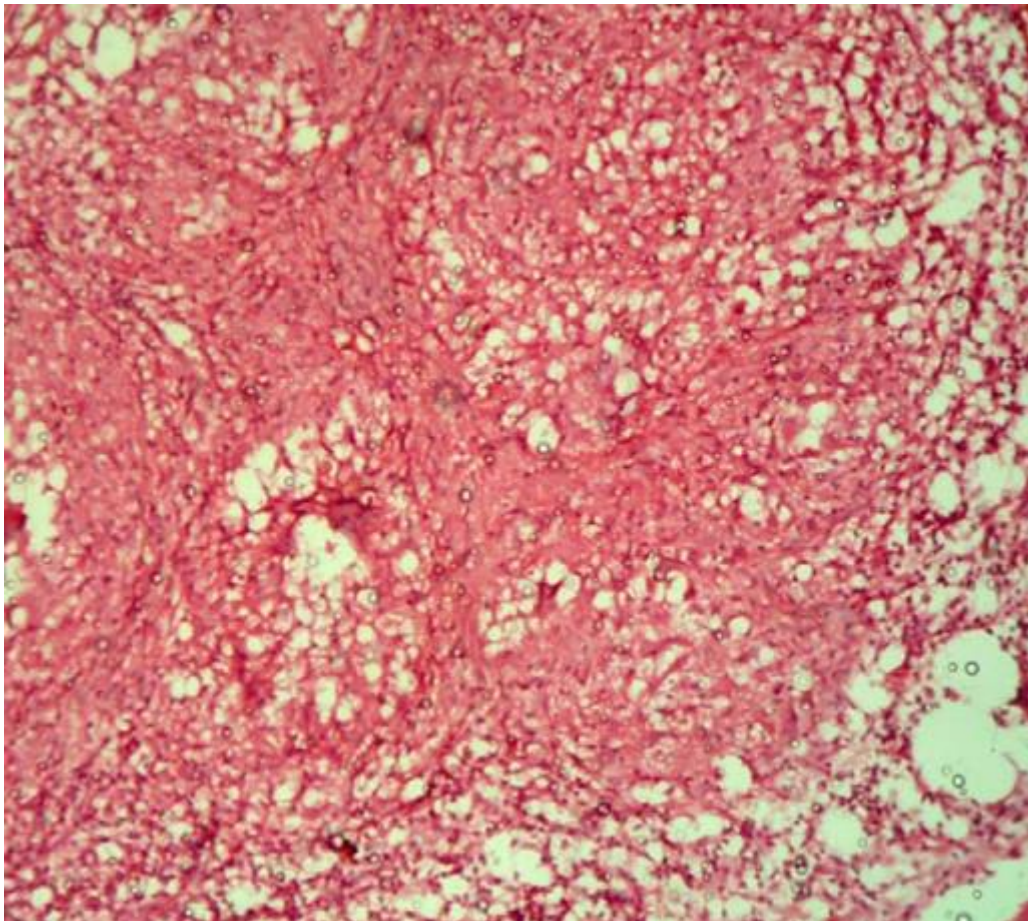
Keywords: Sternal tuberculosis, Manubrium sterni, Skeletal Tuberculosis, Pediatric sternal tuberculosis, Mediastinal Koch's

Case Report

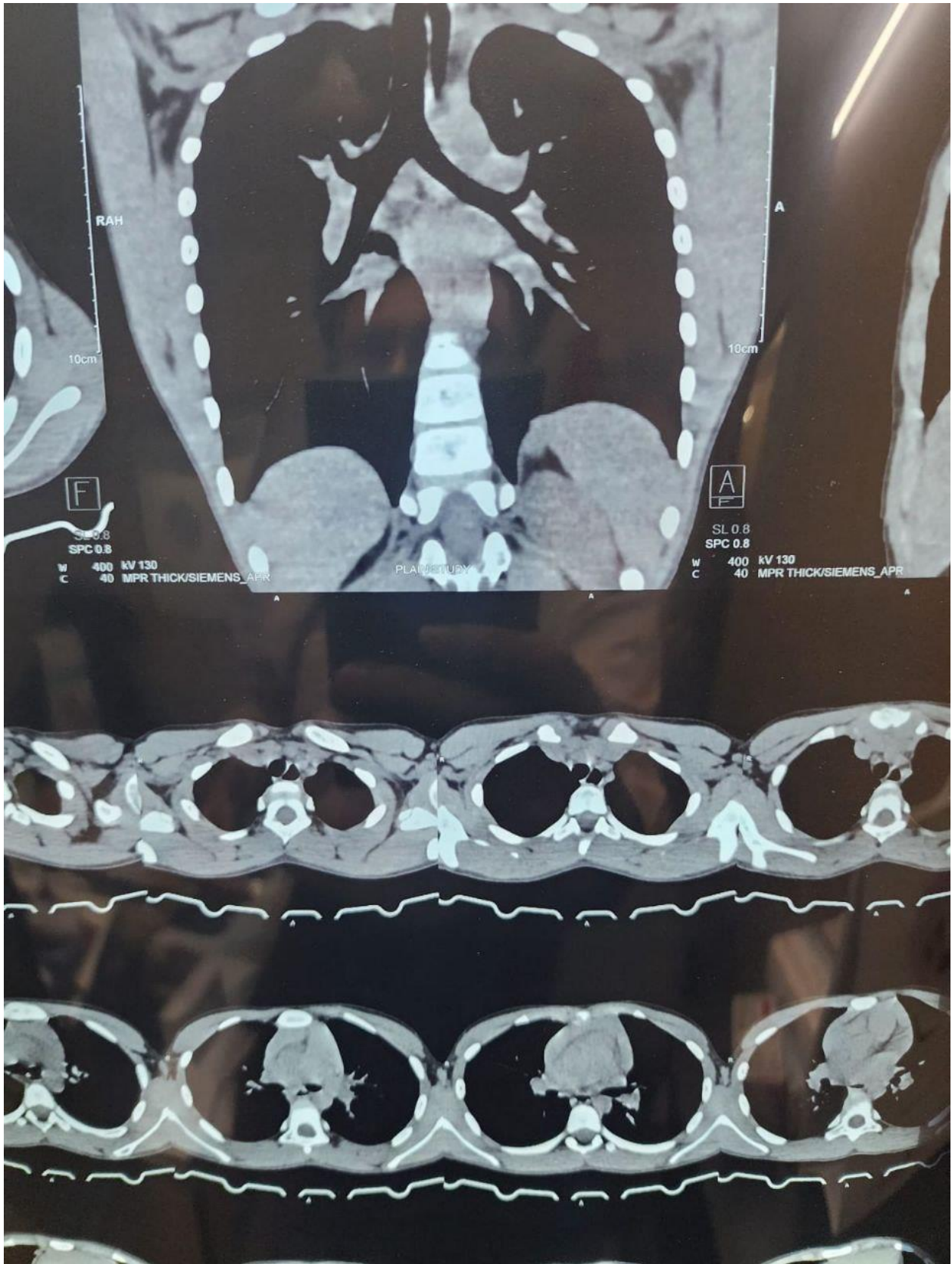
A 9-year-old child had insidious onset symptoms of swelling in the chest and pain for 3 months, fever associated with loss of appetite since 2 month. No previous history of trauma or discharge from the swelling is noted. There was no past history of Koch's. General physical examination was unremarkable. Local examination revealed tender, firm and non-erythematous swelling that

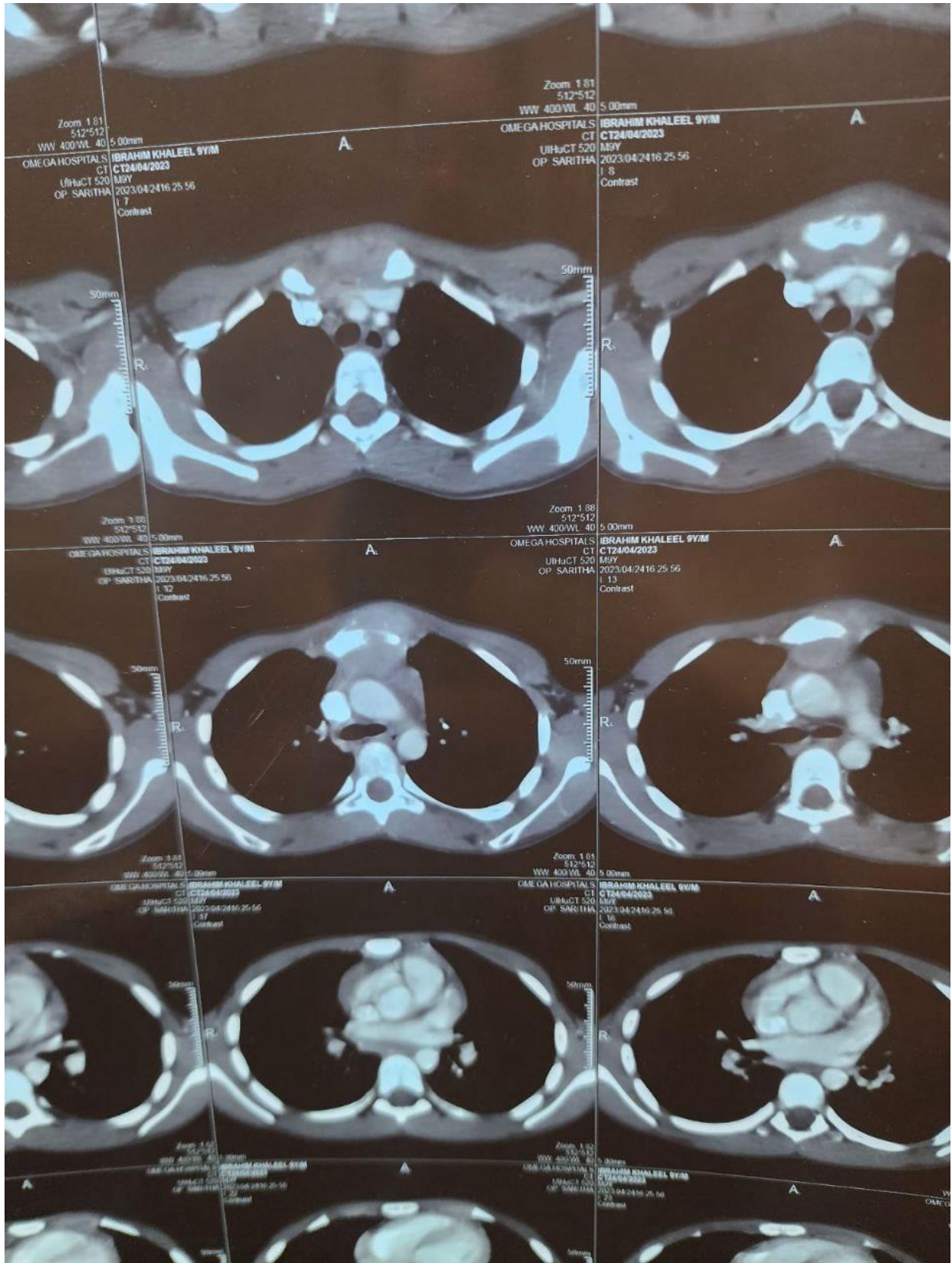
was palpable over the manubrium sterni. Systemic examination did not reveal any other abnormalities. Chest auscultation did not reveal any adventitious sounds. Hematological profile was within normal limits, ESR was raised. Mantoux was >15 mm. Chest radiograph was normal. Fine needle aspiration cytology (FNAC) from the swelling revealed numerous epithelioid cell granulomas with mononuclear infiltrate and scattered giant cells. Acidfast staining of the

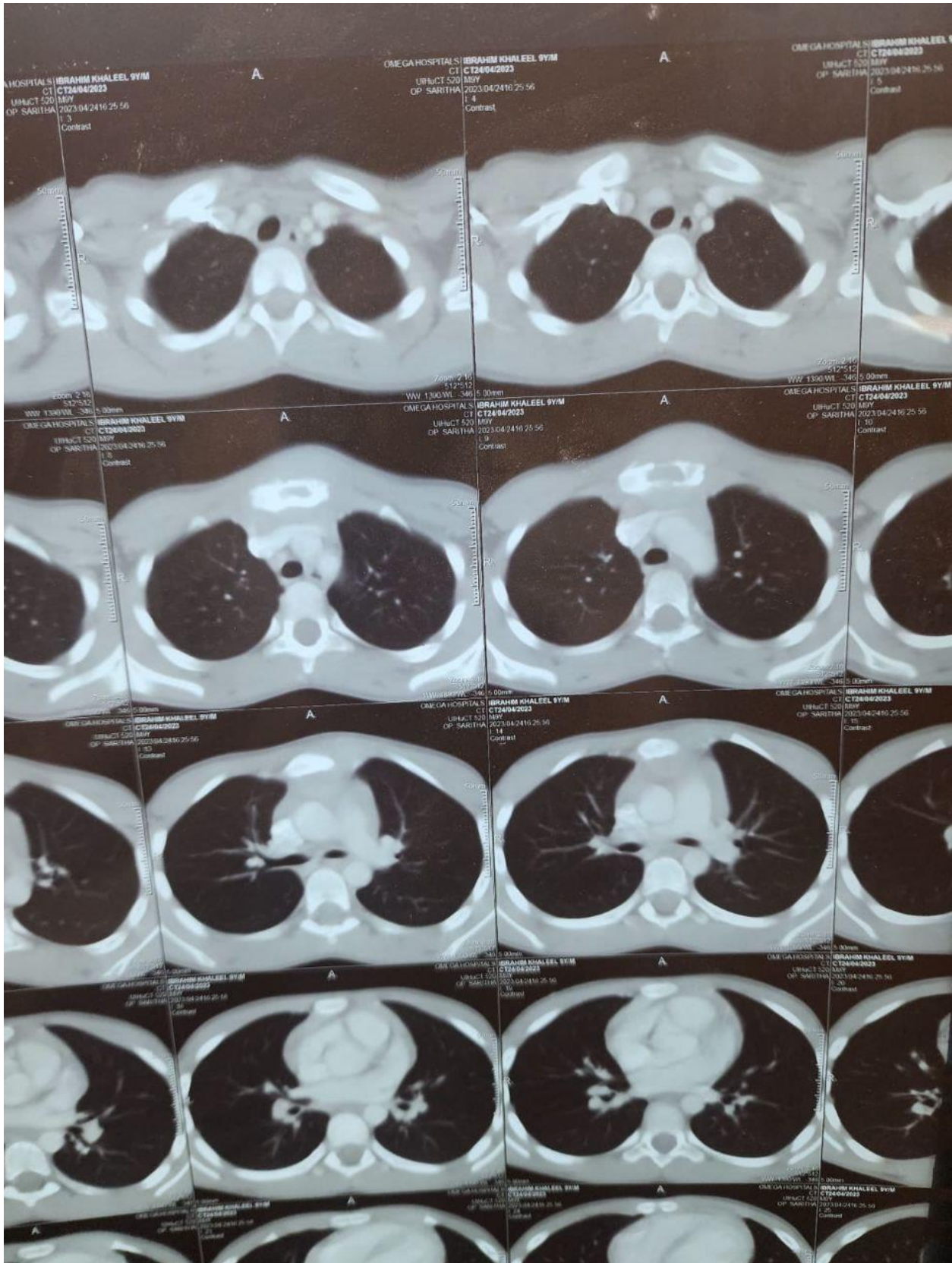
aspirate showed plenty of tuberculous bacilli. HIV serology was negative. CT Chest showed soft tissue density enhancing lesion in the anterior mediastinum measuring (40x59x38 mm - APxTRxCC) destroying the manubrium of the sternum-likely malignant with no evidence of mediastinal lymphadenopathy. Histopathology report for USG biopsy - Manubrium Sternum showed granulomatous inflammation of Koch's aetiology, which is a very rare phenomenon.



Fine needle aspiration cytology (FNAC) from the swelling showing numerous epithelioid cell granulomas with mononuclear infiltrate and scattered giant cells.







Discussion

Primary mycobacterial infection of the sternum, is an extremely rare condition. Tuberculosis of bones and joints accounts for 1—3% of patients

with the disease. Isolated tuberculosis of the sternum constitutes less than 1% of cases of tubercular osteomyelitis⁽⁶⁻⁷⁾.

Aspiration and anti-tuberculous chemotherapy are the treatments of choice in sternal tuberculosis. As per the INDEX guidelines for drug-susceptible skeletal TB, Intensive phase with 2HRZE plus continuation phase of 10HRE is recommended⁽⁸⁾. In a study series, 12 out of 14 patients with tuberculosis of the sternum who were initially treated with multi-drug anti-tubercular therapy, did not require any surgical interventions⁽⁹⁾. Patient is advised to get regular fundoscopy done, to prevent ophthalmic complications. In pediatric age group, it is advised that the academic teachers are also well informed about the child's condition, and detect any sign of blurring of vision and keep the parents informed. A close follow-up is essential to detect complications that may necessitate surgery in these patients. Mediastinal masses in young kids, can mimic as malignancy with a poor prognosis. Surgical treatment is advised when there is a need for the removal of a large sequestrum when the diagnosis is doubtful and in non-responding cases. Early drainage and complete debridement of necrotic material from the lesions along with multi-drug anti-tubercular therapy hastens recovery. Rotational tissue flaps can be employed to cover the chest wall defect due to the extensive loss of soft tissue and bone integrity after debridement⁽¹⁰⁾

Acknowledgments

Special thanks to Dr Mohana Vamsy, Chairman of Omega Group of Hospital and Dr Namratha Vamsy, Medical Director of Omega Hospital, Gachibowli for giving permission to write the Case Report.

References

1. Tuli SM. Tuberculosis of rare sites, girdle and flat bones. In: Tuli SM, editor. *Tuberculosis of the Skeletal System*. 2nd ed. Delhi: Jaypee Brothers Medical Publishers; 2000.
2. Kato Y, Horikawa Y, Nishimura Y, Shimoda H, Shigeto E, Ueda K. Sternal tuberculosis in a 9-month-old infant after BCG vaccination. *Acta Paediatr*. 2000;89:1495–7
3. Kato Y, Horikawa Y, Nishimura Y, Shimoda H, Shigeto E, Ueda K. Sternal tuberculosis in a 9-month-old infant after BCG vaccination. *Acta Paediatr* 2000;89:1495—7.
4. Corrales IF, Cortes JA, Mesa ML, Zamora G. Sternal osteomyelitis and scrofuloderma due to BCG vaccination. *Biomedica* 2003;23:202—7.
5. Withagen MI, Ruitenbergh A, van Soolingen D, Ru'mke HC, Diepstraten AF, de Groot R. Osteomyelitis as a complication following BCG vaccination. *Ned Tijdschr Geneesk* 1995;139:2047—50.
6. Boh JA, Janner D. Mycobacterium tuberculosis sternal osteomyelitis presenting as anterior chest wall mass. *Pediatr Infect Dis J* 1999;18:1028—9.
7. Watts HG, Angrles L, Lifesto RM. Current concepts review: tuberculosis of bones and joints. *J Bone Joint Surg Am* 1996;78:288—98.
8. Index TB guidelines, *Skeletal Tuberculosis*, 96
9. Khan SA, Varshney MK, Hasan AS, Kumar A, Trikha V. Tuberculosis of the sternum: a clinical study. *J Bone Joint Surg Br* 2007;89: 817—20.
10. Sarlak AY, Gundes H, Gundes S, Alp M. Primary sternal tuberculosis: a rare unhealed case treated by resection and local rotational flap. *Thorac Cardiovasc Surg* 2001;49:58—9.