



An Insight into Upper Gastrointestinal Endoscopy at CDSIMER

Authors

Dr Vinayaka N.S.¹, Uppada Vibha², Thrishala Guruprakash³, Sushma P⁴,
Spandana Srinidhi⁵, Kyathi Sundar H⁶

¹Associate Professor, Department of General Surgery, CDSIMER

^{2,3,4,5,6}Phase III MBBS Student, CDSIMER

Abstract

Introduction: Upper gastrointestinal endoscopy is very commonly done diagnostic and therapeutic outpatient basis tool for patients with upper gastrointestinal symptoms. Upper gastrointestinal endoscopy was carried out as OPD procedure in department of general surgery at CDSIMER.

Objectives: To study the various patterns of upper gastrointestinal diseases in our population and their course of management.

Methods: A retrospective study of upper gastrointestinal endoscopy in CDSIMER over past 1 year. Demographics, medical history, indications for upper gastrointestinal endoscopy and the various disease patterns were collected. All patients undergoing upper gastrointestinal endoscopy between 18 and 90 years. Paediatric age group (<18 years), elderly patients above 90 and patients with bleeding disorders are excluded.

Results: Among 359 symptomatic patients who underwent upper gastrointestinal endoscopy, 328 (91.36%) had abnormal results. The top four results were antral gastritis (44.29%), pangastritis (20.33%), GERD (13.09%) and oesophageal candidiasis (4.73%). Inflammation of gastric mucosa in antral gastritis was more severe in the *H.pylori* positive group (23.17%). 220 males and 108 females were affected. Most affected were the age between 38 to 47 years.

Conclusion: Upper gastrointestinal endoscopy is a valuable diagnostic and therapeutic tool in patients with dyspepsia and other upper gastrointestinal symptoms. Training with endoscope is mandatory for surgeon and physicians treating these set of patients. Also it can be a valuable screening tool for diagnosis of carcinoma oesophagus and carcinoma stomach.

Background

Endoscopy is the gold standard investigation for upper gastrointestinal tract allowing direct visualization, tissue sampling and widening remit

of therapeutic curative procedures for early cancers and also enables physicians to visualize a variety of upper gastrointestinal lesions, particularly small lesions^[1]. Nevertheless,

gastroscopy is generally indicated only in case of symptomatic patients. In asymptomatic healthy people, routine endoscopy remains controversial [2].

Orientation within the upper gastrointestinal tract during endoscopy is challenging due to the complex interaction between the flexibility of the scope, the multiple degrees of the freedom of end of the endoscope tip, use of torque and predominant focus on the displayed image^[1].

In this study, we sought to clarify the incidence of various abnormal upper gastrointestinal endoscopic results, among males and females, and different age groups from 18 to 90 years.

Endoscopy

Development of fibre-optic endoscope has greatly facilitated diagnosis of peptic ulcer disease. Diagnostic accuracy is about 95% or more and the evidence is clear that endoscopy is superior to radiography in defining presence of lesion in the oesophagus, stomach and duodenum. By endoscopy, the whole of the interior of the stomach can be adequately inspected.

The fibre optic endoscope is an instrument in which glass-fibres act as lens. This is a flexible instrumentso introduction is easy. By this endoscopy one can clearly inspect the inside of oesophagus, stomach and duodenum.

Camera will allow taking pictures of the inside views. One can even take biopsy under direct vision through this instrument. Inside can also be visualized by television method.

Indications:

1. Persistent symptoms despite appropriate empirical therapy or warning signs such as

intractable vomiting, anaemia, weight loss, dysphagia or bleeding.

2. Symptoms of malabsorption and chronic diarrhoea
3. Therapeutic endoscopic procedures: control of upper gastrointestinal haemorrhage, band ligation in esophageal varices, benign esophageal stricture and achalasia.
4. Assessment of small bowel: Occult haemorrhage, Cryptic haemorrhage.

Materials and Methods

This retrospective study included the results from symptomatic individuals of age 18-90 years who underwent upper gastrointestinal endoscopy at CDSIMER between March 2022 and June 2023. There were 359 patients, 235 males and 124 females. They were divided into 7 subgroups according to age (18-27, 28-37, 38-47, 48-57, 58-67, 68-77, 78-87 years) to see the incidence in each group and hence the most affected group.

The symptoms include upper abdominal pain, retrosternal burning, dyspepsia, globus, odynophagia, regurgitation, hematemesis, melaena, early satiety and even weight loss. Patients also came with foreign body ingestion.

Instruments used included flexible fibre optic Olympus endoscope,

10% lignocaine spray for local anaesthesia and rapid urease test (RUT) kit.



Prior written informed consent was taken. Patient was kept nil per oral (NPO) for 6 hrs prior to the procedure and Injection Hyoscine Bromide 20mg was administered 1 hr prior. Upper gastrointestinal endoscopy was done by experienced and trained surgeons. The disease diagnosed was documented and patients were given printed reports with images of the condition.

UPPER GI ENDOSCOPY Report

Indication : DYSPEPSIA, MALAENA, ANAEMIA

Premedication : LIGNOCAINE 10% SPRAY

Esophagus : BILIARY REFLUX

OG Junction : 35 CMS

Stomach :

Fundus : BILE STASIS

Body : PALE MUCOSA

Antrum : GROWTH IN PRE-PYLORIC AREA SUSPICIOUS OF MALIGNANCY WITH BLEEDING. BIOPSY DONE

Biopsy : TAKEN

Impression : ? CARCINOMA STOMACH

Signature:

Date & Time : 12/ 07/2022

UPPER GI ENDOSCOPY Report

Indication : DYSPEPSIA

Premedication : LIGNOCAINE 10% SPRAY

Esophagus : GRADE B REFLUX ESOPHAGITIS

OG Junction : 36 CMS

Stomach :

Fundus : BILE STASIS

Body : ATROPHIC GASTRITIS WITH BILE STASIS

ULCEROPROLIFERATIVE GROWTH IN LESSER CURVATURE

Pylorus : Normal

Duodenum :

D1 : Normal




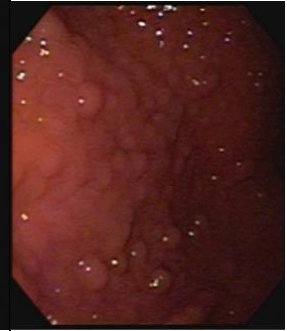
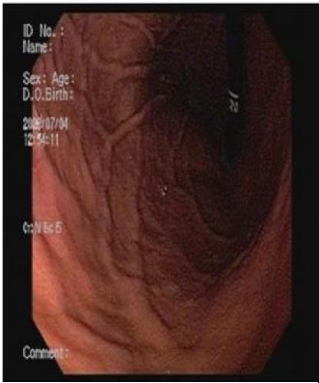
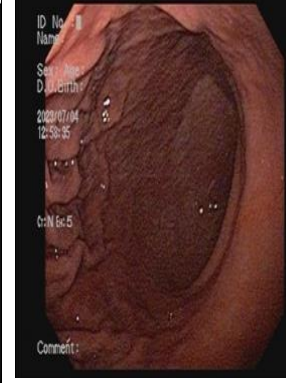



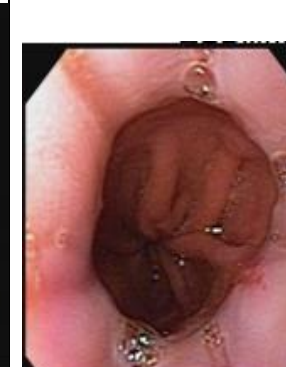


Biopsy : Taken from the growth

Impression : ? CARCINOMA STOMACH

Advice :

CECT ABDOMEN

FOLLOW HPE REPORT

			
BARRETT'S ESOPHAGUS	ESOPHAGEAL VARICES	ESOPHAGEAL CANDIDIASIS	GASTRIC POLYPOSIS
Fundus inflamed	INFLAMED BODY	antral erosions	PYLORUS INFLAMMED
			
PANGASTRITIS			
			
CARCINOMA ESOPHAGUS	HIATUS HERNIA	HIATUS HERNIA	GERD

The patients were then advised treatment and followed up. All of them given injection Pantoprazole 40mg stat. They were medically managed according to the diagnosis. Patients with foreign body in the upper gastrointestinal tract were treated by removal of the foreign body which included coins and dentures.

Inclusion Criteria

All patients undergoing upper gastrointestinal endoscopy over a period of one year, with upper gastrointestinal symptoms or those indicated for the procedure and had complete basic information on demographics like age, sex and medical history.

Exclusion criteria

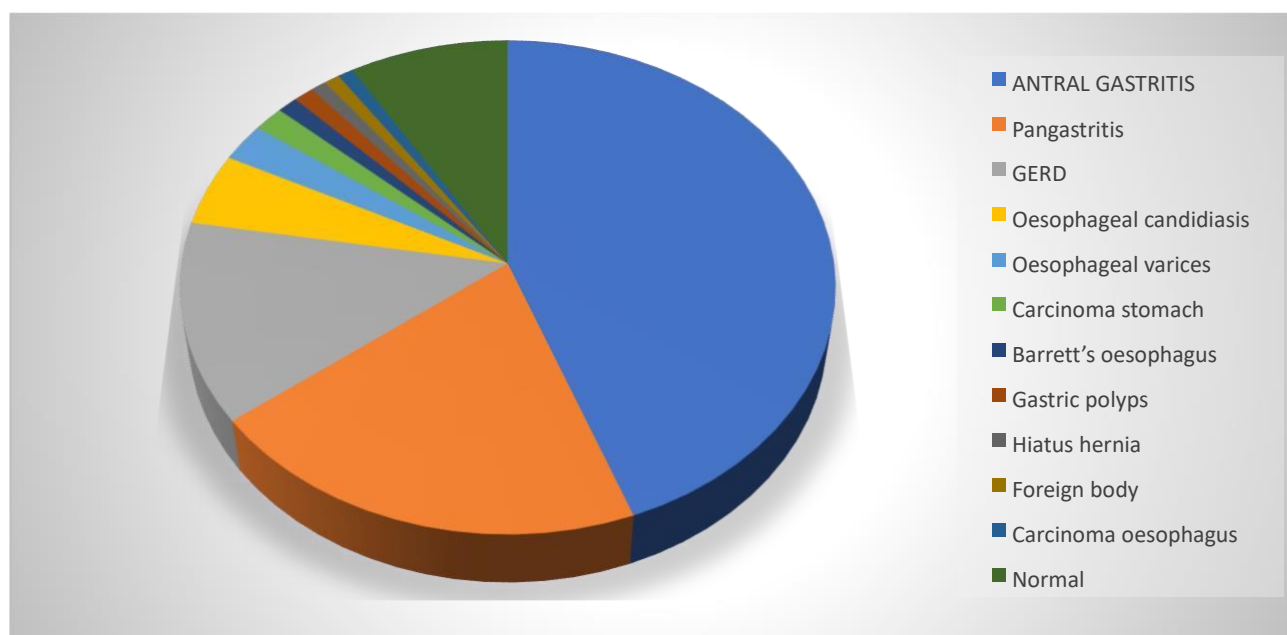
Paediatric age group (of <18 years), patients above the age of 90 years and patients with bleeding disorders.

Results

Out of 359 patients, 225 males and 124 females who presented with upper gastrointestinal symptoms after history and clinical examination, underwent upper gastrointestinal endoscopy and the results were found out to be following:

Distribution of lesions detected in the upper gastrointestinal tract

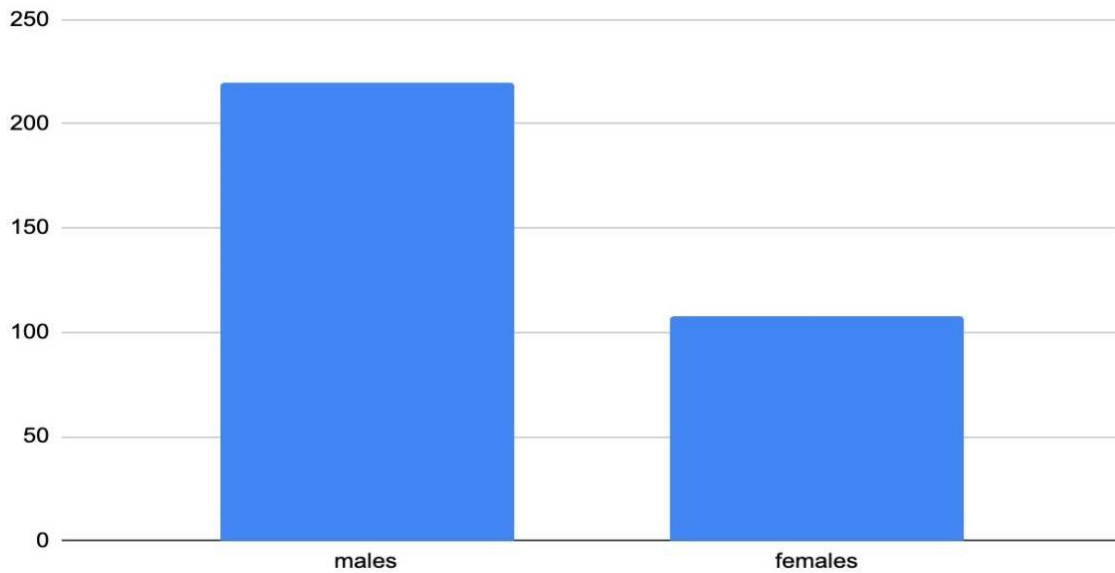
Abnormal upper gastrointestinal endoscopic results	Number of cases detected (%)
Antral gastritis	159 (44.29%)
Pangastritis	73 (20.33%)
GERD	47 (13.09%)
Esophageal candidiasis	17 (4.73%)
Esophageal varices	09 (2.51%)
Carcinoma stomach	06 (1.67%)
Barrett's esophagus	04 (1.11%)
Gastric polyps	04 (1.11%)
Hiatus hernia	03 (0.83%)
Foreign body	03 (0.83%)
Carcinoma esophagus	03 (0.83%)
Normal	31 (8.63%)



Distribution according to sex

220 out of 235 males and 108 out of 124 females who underwent upper gastrointestinal endoscopy were affected.

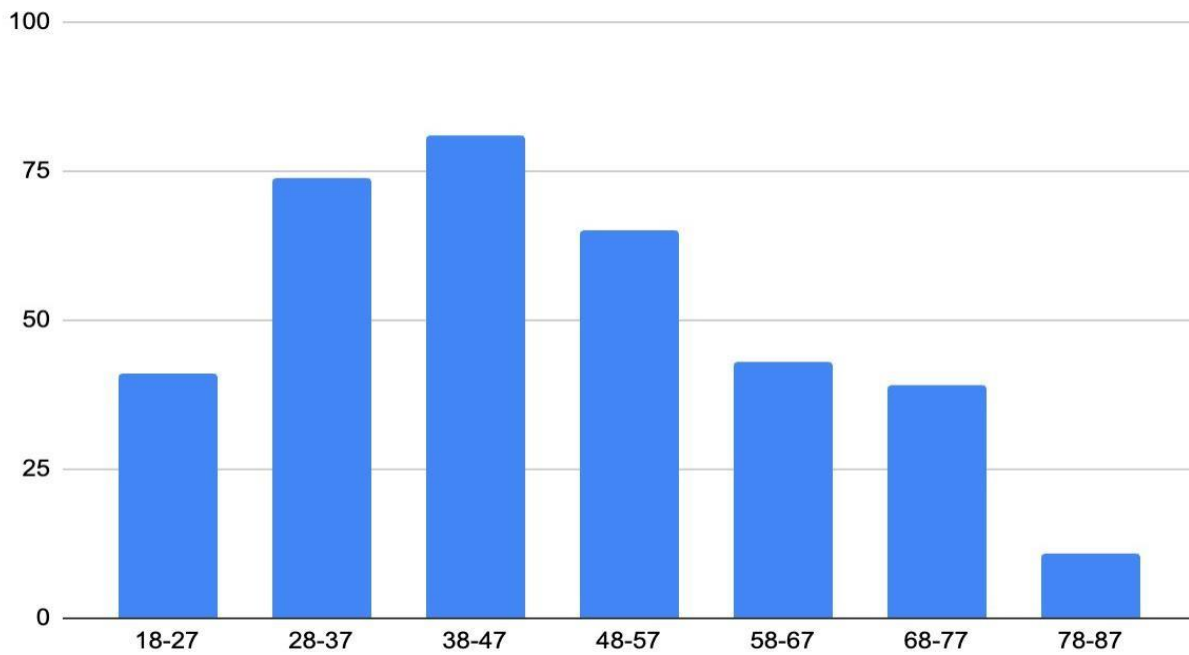
15 males and 16 females showed normal findings



Distribution according to age

Maximum number of affected patients belong to the age group of 38 to 47 years followed by 28 to

37 years, 48-57 years and the least being from the elderly that is 78-87 years.



Discussion

In this study, gastrointestinal symptoms were found more common in males (65.45%) compared to females (34.54%). This could be due to alcoholism, smoking and lifestyle factors are more common in males compared to females.

The present study found that majority of symptomatic patients undergoing upper gastrointestinal endoscopy were diagnosed to

have antral gastritis which was found alone or mostly coexisting with H.pylori infection, Pangastritis, GERD, Hiatus hernia, Barrett’s esophagus, Esophageal candidiasis and oesophageal varices. Other findings were Carcinoma stomach, Carcinoma esophagus, Gastric polyps and Foreignbody^[2].

Antral gastritis, a chronic inflammatory condition of the gastric mucosa, was one of the most

common findings of endoscopy in the population. It includes superficial gastritis, erosive gastritis, and atrophic gastritis according to endoscopic appearance^[3]. Antral gastritis is most oftenly caused by H.pylori infection. The course of H.pylori gastritis, whether it remains antral or progresses to pangastritis and atrophy, is the result of interplay between gastroduodenal mucosal defences, host immune responses and bacterial virulence factors (flagella, urease, adhesions, toxins such as CagA). Antrum is the most commonly infected site in H.pylori gastritis and hence preferred for biopsy. Other causes include autoimmune gastritis, radiation injury, mechanical injury(due to nasogastric tube), chronic bile reflux, systemic diseases such as crohn disease, amyloidosis or graft-versus-host disease. The symptoms here are less severe but more persistent than acute gastritis. It includes nausea, vomiting and abdominal pain.

Gastro-esophageal reflux disease(GERD) is a common upper gastrointestinal disorder caused due to loss of competence of the lower oesophageal sphincter and is extremely common. The classic triad of symptoms is retrosternal burning pain (heartburn), epigastric pain(sometimes radiating through to the back) and regurgitation. Symptoms are provoked by food, particularly those that delay gastric emptying (fats and spicy food).They may also present with bitter or acid taste, odynophagia, angina- like chest pain, pulmonary or laryngeal symptoms. Dysphagia is a sign of esophageal stricture. Complication includes stricture and esophageal shortening. Endoscopy may be required and 24-hour pH is the gold standard.

Oesophageal candidiasis is a condition typically diagnosed in immunocompromised patients caused by *Candida albicans*(predominantly), although non-*albicans* species such as *Candida glabrata* and *Candida tropicalis*. Patients presents with dysphagia and odynophagia that can be often pinpointed to a specific retrosternal area. In immunocompromised patients oral thrush often occurs concurrently. A definitive diagnosis can be

established by endoscopy, with visible white mucosal plaque-like lesions. Endoscopic brushing and biopsy will identifies yeasts and pseudohyphae that invade mucosal cells^[4].

Oesophageal varices are tortuous dilated veins within the lower oesophagus. The large varices can rupture and result in exsanguination. It is caused by portal hypertension. It is commonly seen in patients with cirrhosis, due to alcoholic liver disease. Variceal hemorrhage is an emergency that can be treated medically by inducing splanchnic vasoconstriction or endoscopically by sclerotherapy, balloon tamponade or variceal ligation. Despite these interventions, it confers 15-20% risk of mortality and half of who survive have recurrence within one year.

Carcinoma stomach is one of the most common causes of cancer death in the world. The aetiology is multifactorial, but H.pylori is an important factor for distal but not proximal gastric cancer. They can be classified as intestinal and diffuse type. Early gastric cancer is associated with high cure rates, hence early diagnosis is the key to success with this disease. Spread may be by lymphatics, blood, transcoelomic or direct but distant metastases are uncommon in the absence of lymph node involvement.

Barrett's esophagus is a metaplastic change in the mucosal lining of the esophagus in response to chronic GERD and is associated with increased risk of esophageal adenocarcinoma. In barrett's esophagus, the junction between esophageal mucosa and gastric mucosa moves proximally. It may be difficult to distinguish barrett's esophagus and tubular, sliding hiatus hernia during endoscopy, as the two often coexist or the visible barrett's segment is short. Patients with long segment have greater risk of carcinoma than those with short segment

Gastric polyps are distinct intraluminal projections of mucosal or submucosal tissue. These lesions may actually represent early gastric cancer. Gastric polyps perse are non-neoplastic but these are often associated with Gardener's syndrome

and colorectal neoplasms. Gastric polyps are may be hyperplastic (75%) or adenomatous (10%). Adenomatous are neoplastic in origin, size >2cm is potentially malignant (25%) whereas hyperplastic polyp has minimal risk of malignancy (2%). They are asymptomatic. It may present with pain, haematemesis and gastric outlet obstruction. Gastroscopy is diagnostic.

Hiatus hernia is a condition where a stomach bulges through an opening in the diaphragm into chest cavity. There are two main types: Sliding (more common) and paraesophageal (more dangerous because of volvulus). The paraesophageal hernia is best diagnosed by CT scan with oral contrast. The sliding hiatus hernia is diagnosed through endoscopy but more often confused with Barrett's esophagus.

Carcinoma esophagus is the sixth most common cancer in the world. It can be either squamous cell carcinoma (upper 2/3 of esophagus) and adenocarcinoma (lower 1/3 of esophagus). Patients most commonly present with dysphagia but it is a late feature. Other features include odynophagia, regurgitation, vomiting and weight loss. Etiological factors are tobacco and alcohol in squamous cell carcinoma, GERD and obesity in adenocarcinoma. Lymph node involvement here is bad prognostic factor. Patients with early disease present with non specific dyspeptic symptoms. These patients are diagnosed during endoscopic surveillance especially of patients with barrett's esophagus. The widespread use of endoscopy as a diagnostic tool provides an opportunity for early diagnosis of cancer. Biopsy should be taken of all lesions in esophagus irrespective of indication. Endoscopic ultrasonography can determine the depth of spread of the malignant tumour through esophageal wall.

Conclusion

Upper gastrointestinal endoscopy is a valuable diagnostic and therapeutic tool in patients with dyspepsia and other upper gastrointestinal symptoms. Training with endoscope is mandatory for surgeon and physicians treating these set of patients. Also it can be a valuable screening tool for diagnosis of carcinoma oesophagus and carcinoma stomach.

References

- 1 G. K. A. D. Arun Sivananthan, "Orientation in Upper Gastrointestinal Endoscopy," *World Journal of Gastrointestinal Endoscopy*, vol. 15, no. 3, 2023.
- 2 S. S. R. M. Shashidhara Puttaraju, "Study of upper gastrointestinal endoscopy in patients with gastrointestinal symptoms," *International Surgery Journal* 6(10):3595, 2019.
- 3 Y. R. M. W. Z. G. Y. Y. Z. L. X. C. H. W. J. D. L. Y. & J. P. Haosu Huang, "Analysis of gastroscopy results among healthy people undergoing a medical checkup: a retrospective study," *BMC Gastroenterology*, 2020.
- 4 d. T. E. H. L. A. B. Yousef Nassara, "Possible Risk Factors for Candida Esophagitis in Immunocompetent Individuals," *Gastroenterol Res and Elmer Press Inc*, vol. 11, pp. 195-199, 2018.