



Congenital Vaginal Atresia: A Rare Case Report

Authors

Dr R. S. Ramya¹, Dr Sundar Narayanan²

¹MBBS, DGO, DNB (Obg) (Endogynaecology Fellowship Resident, Siva Hospital)

²MBBS, MD (Professor of Endogynaecology Department, Siva Hospital)

Abstract

Congenital vaginal atresia is a rare abnormality of the female reproductive tract which occurs as a result of failure of canalisation of the urogenital sinus^[1]. The prevalence of female genital tract anomalies is 4-7% amongst general population and as common as 8-10% in women with recurrent pregnancy loss and approximately 3% in patients with infertility. Vaginal atresia, a rare Müllerian anomaly whose incidence is 1/4000 to 1/10000 people, is frequently associated with either normal lower vagina or the absent vagina^[4].

We report an uncommon case of a 13yearold girl with a primary amenorrhea associated with cyclical pelvic pain. Ultrasound examination revealed hematometrium and Magnetic Resonance Imaging (MRI) revealed hematometrocolpos secondary to imperforate hymen and left ovarian hemorrhagic cyst. The diagnosis of partial vaginal aplasia with normal uterus was diagnosed intraoperatively and the patient underwent diagnostic vaginolaparoscopy with laparoscopy guided vaginoplasty. The evolution was satisfactory with regular cycles and improvement of pelvic pain.

Congenital vaginal atresia is a rare malformation which presents as primary amenorrhea with chronic cyclic pelvic pain. Diagnosis is based on clinical examination and imaging. The MRI is designed to assess the atresia and guide surgical management while the surgical technique aims to restore the integrity of the utero-vaginal tract.

Surgical reconstruction is possible in these cases. Extirpative surgery may be preserved for surgical failures. Uterovaginal anastomosis should be considered in difficult cases, especially those prone for stenosis. Early surgery is essential for favourable results. Clinical judgement of the surgeon is most important. It is important to determine the malformation during surgery. Also it is of crucial importance for us to follow up the patient well into reproductive and obstetric outcomes in future. The postoperative results are usually satisfactory: menstruation and sexual activity are established in the majority of the patients.

Keywords: *Congenital vaginal atresia, hematometrocolpos, vaginoplasty, Mullerian anomaly.*

Introduction

Congenital vaginal atresia is a rare abnormality of the female reproductive tract which occurs as a result of failure of canalisation of the urogenital sinus^[1]. During embryogenesis, the lower part of

the vagina develops from the urogenital sinus and the tubes, the uterus and the upper two-thirds of the vagina develop from the Mullerian ducts. Isolated vaginal atresia occurs due to a developmental defect of the terminal part of the

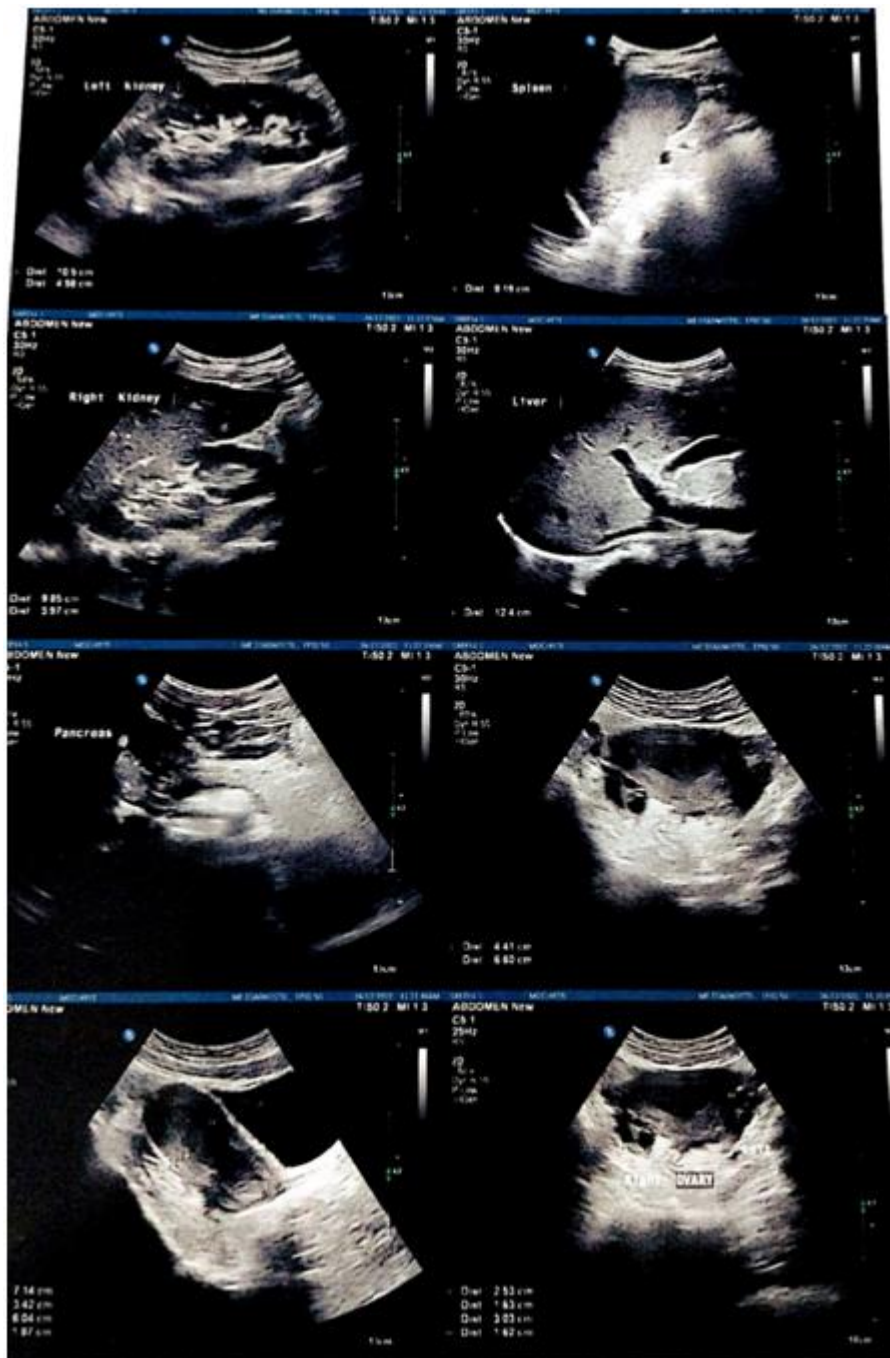paramesonephrotic ducts. We report a case of an isolated partial vaginal aplasia on functional uterus and discuss the management.

Case Report

We hereby report an uncommon case of a 13-year-old girl who presented with primary amenorrhea associated with chronic and cyclic pelvic pain since 4 months. Her height was 145 cm and weight 45 kg and had normal secondary sexual characters (tanner stage 4 of breast and tanner 5 of pubic

hair). External genitalia was normal. Vagina was almost 1.5 cm length and non tender.

Ultrasonography showed a uterus of size 7.1 x 3.4 x 6.6 cm. The endometrium cavity appears distended with hyperechoic area measuring 6 x 4.4 x 1.8 cm predominantly hypoechoic with few hyperechoic areas. Cervix appears normal. Both ovaries appear normal in size and echotexture. No obvious adnexal mass seen. There is no free fluid in the peritoneal cavity. Features suggestive of hematometrium



MRI revealed cystic dilatation of upper 2/3rd vaginal canal, entire length of cervical and endometrial cavity noted with maximum AP diameter measures 3 cm, 1.5 cm and 0.9 cm respectively. Dilated cavity is filled with T2/ STIR heterogeneously hyperintense, T1 iso to mild hyperintense cystic lesion with thin internal

septations in pelvis more towards left side. No evidence of fluid level in T1. The lesion measures 6.0 x 5.5 x 5.8 cm. Left ovary is not separately visualised from the lesion. The lesion is displacing uterus towards left posterolaterally. Suggestive of left ovarian hemorrhagic cyst.



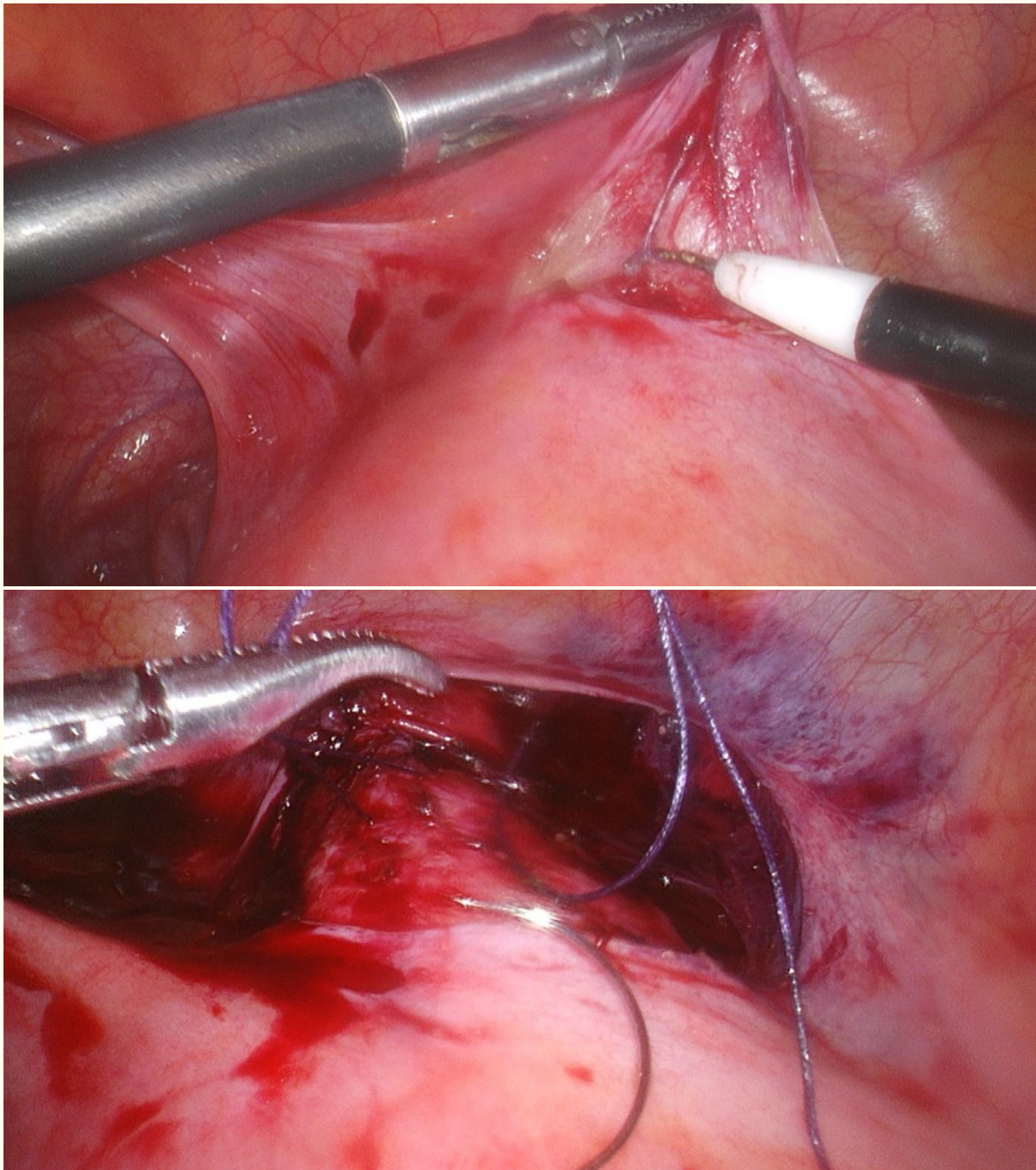
The patient underwent diagnostic vaginolaparoscopy with laparoscopy assisted vaginoplasty. Under general anesthesia, bladder

catheterised. Vagina was found to be partially atretic. Plane created between rectum and urethra. Laparoscopic findings included normal uterus,

cervix could not be delineated, both fallopian tubes appeared normal, left ovarian clear cyst punctured, fluid drained out and cauterised, Right ovary normal, Minimal adhesions in POD lysed. Uterovesical fold of peritoneum opened using cautery and bladder pushed down. Anterior colpotomy done. Anterior fornix identified by vaginal manipulation using folded gauze. Anterior vaginal wall opened using harmonic scalpel. Stay sutures taken on cervix and cervix pulled through the opening vaginally. Cervix sutured to apex of

vaginal end with interrupted sutures using 3-0 vicryl. External os identified. Cervix dilated and hematometra drained. Hysteroscopy done to rule out uterine anomalies. Hemostasis ensured. Cystoscopy done and bladder was found to be intact. Wash given with saline. All entry ports closed.

The evolution was marked by the appearance of regular cycles with marked improvement of pelvic pain.



Discussion

Incidence of Mullerian duct anomaly is approximately 1% among general population and 3% among patients with infertility^[4].

Vaginal atresia, a rare Mullerian anomaly, has an incidence of 1/4000 to 1/10000 people^[4]. Total or partial isolated vaginal atresia is a rare congenital anomaly which comprises 9% of cases of vaginal atresia^[1].

Surgical management is the norm for these patients. In asymptomatic prepubertal girls, the vaginal reconstruction is ideally postponed till pubertal age, as soon as the hematocolpos appears and before development of hematometrocolpos. This is done to provide sufficient time for development of the vaginal tissue which will facilitate vaginal anastomosis in limited partial forms. In addition it would further reduce the incidence of stenosis which is a frequently associated complication. The principle of all surgical techniques comprise of a preliminary dissection of the fibrous plane located between the bladder and the urethra in front and the rectum behind, which is approached through perineal or mixed perineal-abdominal or laparoscopic access.

Embryology

The paramesonephric ducts develop into the main female genital ducts at the end of the third month of embryonic life. Each paramesonephric duct can be divided into three parts:

- (i) a cranial vertical division which develops into the fallopian tubes lie open-ended into the abdominal cavity
- (ii) a middle horizontal division portion which crosses over the mesonephric duct and this part develops into the broad ligament
- (iii) a caudal vertical part which fuses in the midline with the contralateral paramesonephric duct and develop into the uterus, the cervix, and the upper two-thirds of the vagina. The primitive cervix is situated approximately in the middle portion of a continuum of the fused mullerian ducts. Vacuolization of the paramesonephric

tissue results in the development of the fornices, the upper part of the vagina and the cervical canal.

Pathogenesis

Congenital cervical dysgenesis in cases with a normal vagina is well explained by the “atrophy hypothesis”.

An incomplete/partial caudal elongation defect of the fusion of the mullerian ducts during the embryonic period results in partial vaginal agenesis. This “defective elongation hypothesis” better explains the cause in cases of cervicovaginal aplasia, where the whole of the caudal parts of the primitive paramesonephric ducts appear to fail appropriately.

Clinical Manifestation

Cervical and vaginal malformations are typically obstructive anomalies. Any pubertal female who presents with primary amenorrhoea along with history of cyclic abdominal pain should raise the clinical suspicion of cervical malformations (with or without a normal vagina).

It is important to differentiate between hematocolpos secondary to imperforate hymen, a transverse vaginal septum and cervical and vaginal atresia.

An important matter of concern is the prevalence of endometriosis which is a devastating additional factor affecting the future normal function of the tubes and the ovaries. Any adhesions formed as a result of endometriosis will definitely have a negative impact on a surgical approach.

In cases of vaginal atresia, there is impairment of woman's sexual function.

Aim of Treatment

The management of congenital mullerian malformations should satisfy three distinct end points:

- 1) Relief from the obstructive symptoms
- 2) Establishment of normal sexual function
- 3) Preservation of the uterus for future fertility

In cases with late diagnosis, and uterine function is compromised either because of the hematometra or because of the severe pelvic adhesions already affecting the individual.

Conclusion

Surgical reconstruction is possible in these cases. Extirpative surgery may be preserved for surgical failures.

Uterovaginal anastomosis should be considered in difficult cases, especially those prone for stenosis.

Early surgery is essential for favourable results

Clinical judgement of the surgeon is most important.

It is important to determine the malformation during surgery.

Also it is of crucial importance for us to follow up the patient well into reproductive and obstetric outcomes in future.

The postoperative results are usually satisfactory: menstruation and sexual activity are established in the majority of the patients.

Fecundity may be preserved as well in many cases^[4].

Vaginal congenital malformations are very rare entities that currently can be managed with conservative surgical treatment.

Conservative surgery of vaginal congenital malformations serve as a first-line treatment.

References

1. Slaoui A, Benzina I, Talib S, Etheb A, Zerai N, Lakhdar A, Kharbach A, Baydada A. Congenital vaginal atresia: about an uncommon case. *Pan Afr Med J*. 2020 Sep 17;37:69. doi: 10.11604/pamj.2020.37.69.21682. PMID: 33244332; PMCID: PMC7680234.
2. Okoro PE, EliSS. Congenital vaginal obstruction in young girls: need for standard post-operative dilatation protocol. *Int Surg J*2019;6:207-10.
3. Mei L, Zhang H, Chen Y, Niu X. Clinical features of congenital complete vaginal

atresia combined with cervical aplasia: A retrospective study of 19 patients and literature review. *Congenit Anom (Kyoto)*. 2021 Jul;61(4):127-132. doi: 10.1111/cga.12417. Epub 2021 May 4. PMID: 33829535; PMCID: PMC8360086.

4. Regmi, D. R., Dangal, G., Karki, A., Pradhan, H. K., Shrestha, R., Bhattachan, K., Tiwari, K. D., Bharati, S., Manandhar, P., & Maharjan, S. (2021). Vaginal Atresia with Cervical Agenesis, a Rare Congenital Malformation. *Kathmandu University Medical Journal*, 19(3), 390–392. <https://doi.org/10.3126/kumj.v19i3.49746>.