



Ocular and Ear, nose, throat injuries in patients with Road traffic accidents

Authors

Dr Rohini Choudhary, Dr Ashish Sawhney, Dr Ashok Kumar Sharma

Introduction

Road traffic accidents account for a major proportion of people suffering all over the world. Ocular, Ear, head and nasal injuries contribute to a major part of trauma in road traffic accidents. Trauma to eyes can cause several types of eye injuries involving eyelids, lacrimal canaliculi, orbital wall, periorbital structures, conjunctiva, cornea, sclera, extraocular muscles resulting in even permanent visual impairment in some cases creating enormous effects both to the victim and to the society. Nasal bleed, nasal bone fractures, jaw injuries, ear lobe lacerations, traumatic perforations, temporal bone fractures, cut throat injuries, laryngeal injuries etc. are also very common findings seen in Road traffic accident cases leading to permanent hearing impairment, cosmetic disfigurement or in worse cases even death. This study is performed to evaluate the pattern of different types of ocular and ENT injuries in road traffic accidents.

Material and Methods

This cross-sectional observational study was conducted in Government Medical College Jammu for a period of 2 years from June 2020 to July 2022 which included 264 Road traffic accident cases irrespective of age and gender. The study population was drawn from the patients with

history of ocular or ENT injuries following road traffic accidents presenting to casualty and out-patient department of ENT and Ophthalmology department of Government Medical College, Jammu.

Inclusion Criteria

1. Patients who sustained ocular and ENT injuries during road traffic accidents.
2. Any Age and Gender

Exclusion Criteria

1. ENT or Ocular injuries due to accidental fall, assault or domestic trauma.
2. Injuries due to burns or chemicals.
3. Old Ocular or ENT injuries due to previous accident or trauma.
4. Patients who expired immediately after the accident or brought dead.

The patient data which included age, gender, type of injury, mode of accident, duration of injury, signs and symptoms and final outcome after treatment was recorded and tabulated in Excel spread sheet.

Each patient was evaluated completely and detailed history was obtained. Grading of head injury was done with Glasgow Coma Scale. Ocular examination included visual acuity (recorded using Snellen's chart), slit lamp examination, IOP was recorded, direct and

indirect Ophthalmoscopy was performed wherever required, plain X-ray skull and orbit AP & lateral view, B-scan ultrasonography was performed in cases with media opacities who were suspected of having posterior segment abnormality. ENT examination included nasal examination, detailed ear examination, oral cavity, tongue, throat and laryngeal endoscopic examination was done. Routine CT brain with HRCT temporal bone was done for patients presenting with ear bleeding, facial palsy or CSF otorrhoea. X-ray nasal bone was done in suspected cases of nasal bone fractures and X-ray skull AP and lateral in cases with fascio- maxillary trauma CT- face with 3D reconstruction was done. Pure tone audiometry was done in cases of hearing loss, tinnitus and traumatic perforation of tympanic membrane. CT and MRI were done wherever required. Patients were managed mainly at casualty and OPD level, and some patients with severe injuries were admitted for further management.

Results

Out of 264 patients 192 were males and 72 were females. Majority of the patients were in the age group of 25-40 years (age and gender distribution depicted in Table 1). Out of these, 101 patients presented with only ENT injuries and head

injuries, 46 presented with only eye injuries whereas 117 patients presented with both eye and ENT Injuries.

Ear injuries like bleeding from the ear, external ear laceration, temporal bone fracture, facial palsy, traumatic perforation, tinnitus and vertigo were observed. Nasal trauma like fracture nasal bones, lacerations, Le Fort fractures, septal injuries and CSF rhinorrhoea was seen. Laryngeal trauma, vocal cord palsy etc were seen among throat injuries and other facial injuries observed are given as under. (Figure 1a,1b,1c,1d).

Eye injuries observed were eyelid laceration/tear, corneal perforation, corneal abrasion, conjunctival tear, sub-conjunctival haemorrhage, periorbital edema, ecchymosis, chemosis, canalicular injuries, Hyphaema and orbital fractures (Figure 2).

Table 1: Age and gender distribution of Road traffic accident cases

Age Range (years)	Gender distribution	
	Male	Female
5- 15	06	02
16-25	24	10
26-35	84	36
36-45	38	16
46-55	22	06
>55	18	02
Total	192	72

Figure 1a: Ear injuries among accident cases.

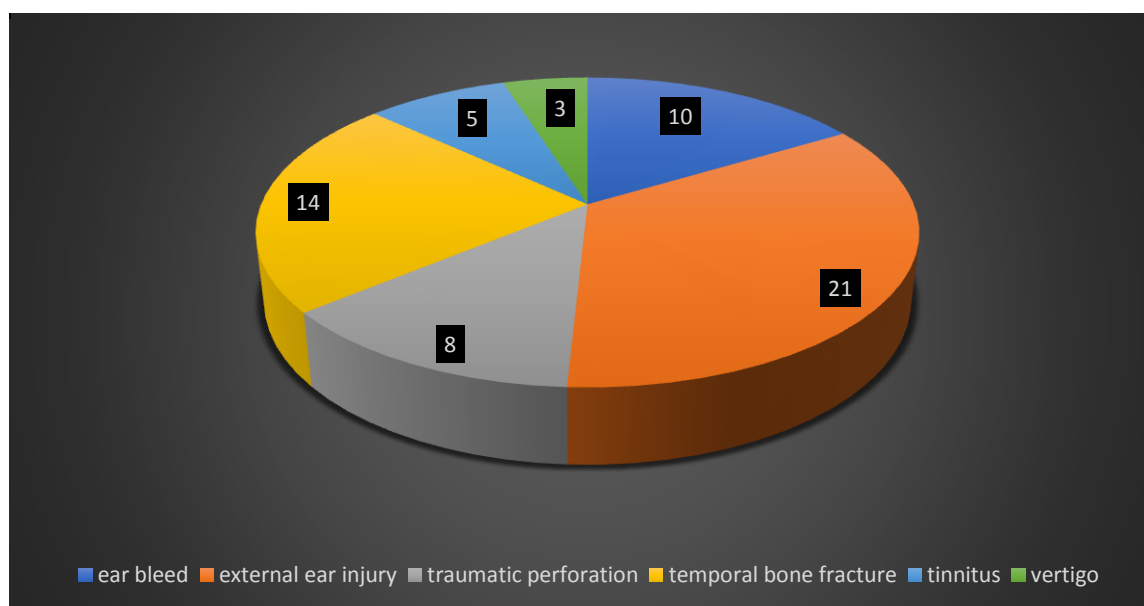


Figure 1b: Nose injuries in accident cases.

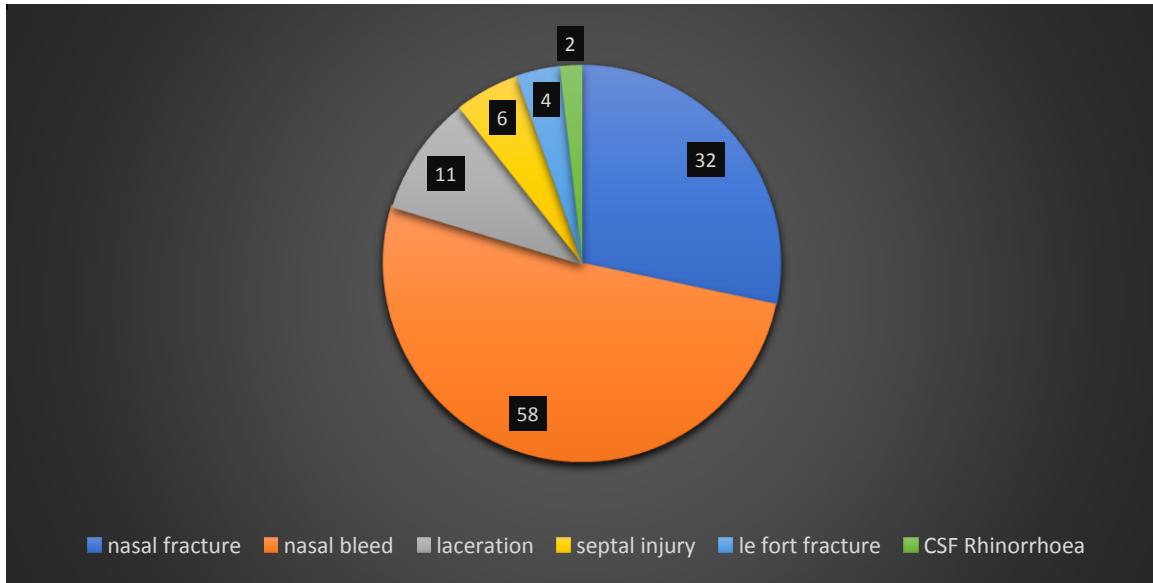


Figure 1c: Throat injuries in accidental cases.

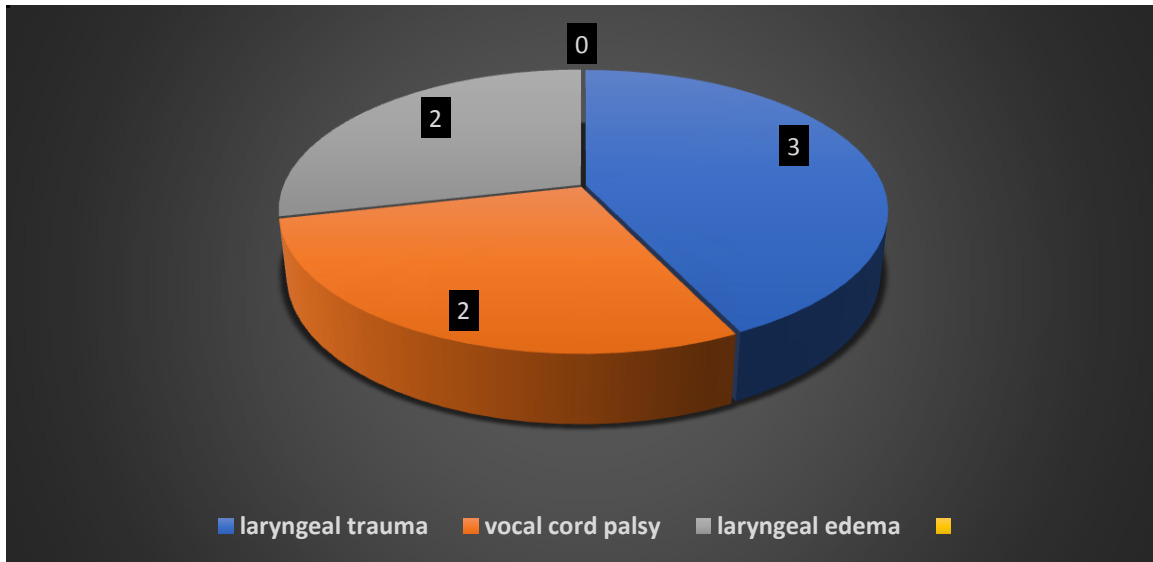
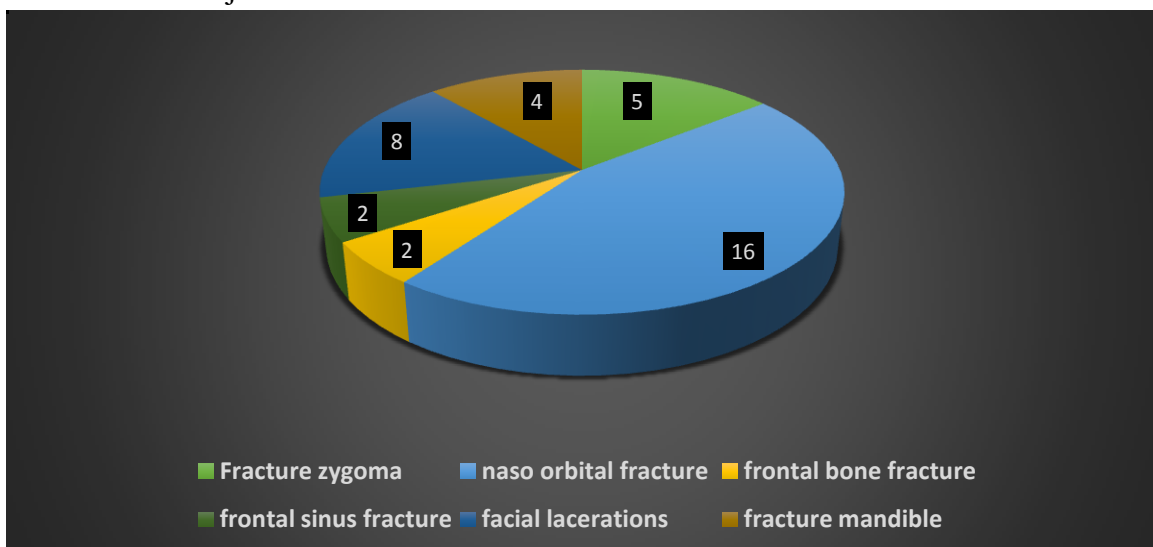


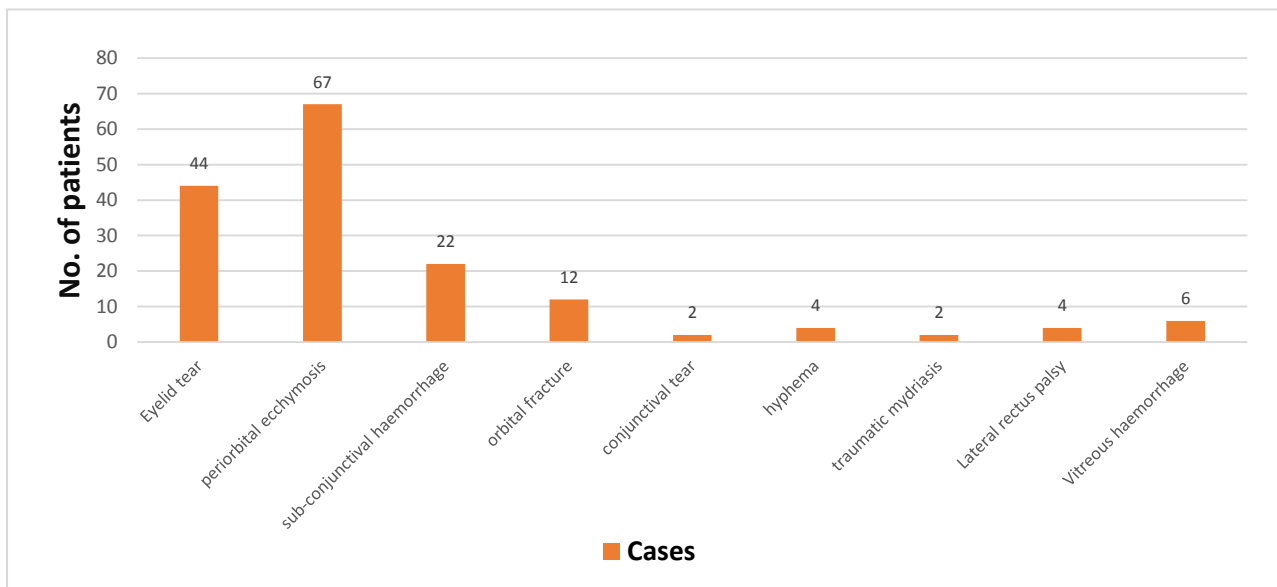
Figure 1d: Other Facial Injuries



Out of total 264 patients, 101 had only ENT injuries whereas 117 had both ENT and eye injuries. Among ENT injuries, few patients had multiple site involvement including mixed injuries of nose and ear, thus presenting with multiple symptoms like nasal bleeding with nasal fracture or septal injury. The most common ear injury

observed was temporal bone fracture seen in 21 patients, most common nasal injury finding was nasal bleed (40 patients), most common throat injury was laryngeal trauma (3 patients) and most common facial injury was naso-orbital fracture (14 patients).

Figure 2: Ocular injuries in accident cases



Among cases with ocular involvement, most common finding was periorbital ecchymosis (65 patients) followed by eyelid tear (44 patients). Other ocular injuries seen were orbital fractures, Sub conjunctival hemorrhage, Conjunctival tear, Hyphema, Traumatic mydriasis, Lateral rectus palsy and Vitreous hemorrhage.

Discussion

Motor vehicle accidents constitute the largest cause of head injury and the incidence of head injuries is increasing day by day. Oto-rhino-laryngological injuries associated with Road Traffic Accidents are grave and life threatening whereas, ocular injuries can be sight threatening. Facial cosmesis and restoration of normal physiology of sensory organs is very important and cannot be over emphasised. The advent of newer technologies in investigations and treatment like high resolution CT scan, MRI, endoscopies, OCT scans provides accurate assessment of

injuries and significant change in the management of head and neck injuries. This study highlights the necessity of the ENT and Eye surgeon’s inclusion in the trauma team and the present study has been done to evaluate various ear, nose, throat and ocular manifestations and investigations which helps in earlier diagnosis.

In the present study, a total of 264 patients were examined out of which, 192 were males and 72 were females. Majority of the patients were in the age group of 25-40 years (age and gender distribution depicted in Table 1). Out of these, 101 patients presented with only ENT injuries and head injuries, 46 presented with only eye injuries whereas 117 patients presented with both eye and ENT Injuries. Like our study, Templer et al also reported that ear injuries occur in patients of all ages. Moderate intensity force can cause lacerations or even amputation of pinna in some cases.

In our study, most common ear injury observed was external ear injury / pinna laceration (21) followed by temporal bone fracture (16). The most common nose injury was nasal bleed (58) and nasal fracture (32). Laryngeal injury was seen mostly among throat injury cases (3). Naso-orbital fracture was most commonly seen among facial injuries (16).

Ocular injuries are also very common in cases with Head injuries in Road traffic accidents. These injuries can range from being mild which heals within few days to severe which can be sight threatening causing irreversible damage to globe or optic nerve. The severity of ocular injuries can be assessed through proxy indicators such as: (a) potentially blinding bilateral injuries; (b) open-globe injuries; (c) endophthalmitis; (d) enucleation or (e) visual impairment. The most common ocular injury seen in our study was periorbital ecchymosis (67) followed by Eyelid trauma (44). Similar injuries were reported in a study by Kulkarni. Many of these accident cases showed overlapping of ENT and ocular symptoms presenting with both injuries. Thus, in this study we observed that ENT and Ocular Surgeon must be vigilant in RTA cases as most of the cases present with head and neck injuries. Most of the cases were managed conservatively with few cases needing ENT and Neurosurgical intervention similar to other related studies^[4].

Conclusion

Timely diagnosis and intervention by ENT and Ocular surgeons can help in better outcome in terms of patient's hearing abilities, visual functions, olfactory functions, cosmesis and other long-term complications in Road traffic accident cases.

Bibliography

1. Z Sarafraz M H Mirshamsi S A Musavi M H Azaraein Assessing the ignored associated injuries of the Ear, Nose and

Throat in patients with multiple trauma in Shahid Rahnamun Hospital of Yazd in 2012 & 2013. *Electron Physician*

2. Siddaram Patil Girish P. B. Ear manifestations in head and neck injury *Int J Otorhinolaryngol Head Neck Surg* 2017
3. H. Zusho Posttraumatic Anosmia *Archives of Otolaryngol- Head Neck Surg* 1982
4. A Adeyi Adoga otorhinolaryngological manifestations in head trauma: A prospective study of the epidemiology, clinical presentations, management and outcomes *Int J Crit Illn Inj Sci* 2017
5. Siddaram Patil Girish P. B. Ear manifestations in head and neck injury *Int J Otorhinolaryngol Head Neck Surg* 2017
6. Desai E, Patel RB, Pandya K, Mitra S. A Clinical Study of ENT Manifestations in Cases of Head Injury Patients Coming to Tertiary Care Centre of South Gujarat. *Indian J Otolaryngol Head Neck Surg.* 2022 Dec;74(Suppl 3):5675-5680.
7. Kulkarni AR, Aggarwal SP, Kulkarni RR, Deshpande MD, Walimbe PB, Labhsetwar AS. Ocular manifestations of head injury: a clinical study. *Eye (Lond).* 2005 Dec;19(12):1257-63.
8. Sharma B, Gupta R, Anand R, Ingle R. Ocular manifestations of head injury and incidence of post-traumatic ocular motor nerve involvement in cases of head injury: a clinical review. *Int Ophthalmol.* 2014 Aug;34(4):893-900.
9. Shtewi ME, Shishko MN, Purohit GK. Road traffic accidents and ocular trauma: experience at tripoli eye hospital, libya. *Community Eye Health.* 1999;12(29):11-2.
10. Négrel AD, Thylefors B. The global impact of eye injuries. *Ophthalmic Epidemiol.* 1998 Sep;5(3):143-69.