



## Case Report

# Asymptomatic presentation of Kikuchi Fujimoto disease as cervical lymphadenitis

Authors

**Kalpita Kumar Sahoo<sup>1</sup>, Preeti Sagar<sup>2</sup>, Shubham Haritash<sup>3</sup>,  
Simran Kaur<sup>4</sup>, Naresh Pal<sup>5</sup>, Bhavinder Kumar Arora<sup>6</sup>**

<sup>1,2,3,4</sup>Junior Resident, Department of General Surgery, PGIMS, Rohtak

<sup>5,6</sup>Professor, Department of General Surgery, PGIMS, Rohtak

Corresponding Author

**Dr Kalpita Kumar Sahoo**

Junior Resident, Department of General Surgery, PGIMS, Rohtak, 124001

## Abstract

*Kikuchi Fujimoto is a rare disease presenting with symptoms of fever, cervical lymphadenopathy and feature of systemic lupus erythematosus (SLE). It is thought to be a disease of viral etiology. It is difficult to differentiate from lymphoma, tubercular lymphadenitis and SLE. The asymptomatic presentation of Kikuchi Fujimoto disease is even rarer. The diagnosis is made by histopathological evaluation.*

**Keywords:** *Kikuchi-Fujimoto, lymphadenitis, asymptomatic, SLE.*

## Introduction

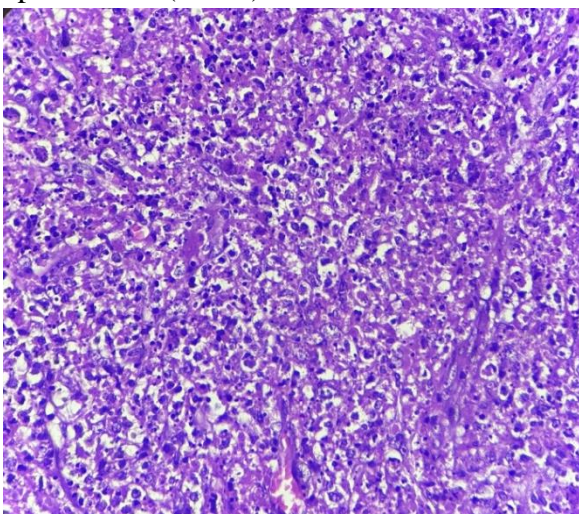
Kikuchi Fujimoto disease (KFD) is a rare disease presenting with sub-acute to chronic lymphadenopathy associated with fever, tender cervical lymphadenopathy and systemic symptoms, affecting young adult population, younger than 40 years of Asian ancestry with an ever increasing incidence globally.<sup>1</sup> Despite having first described in 1972 by Kikuchi and Fujimoto et al, its pathogenesis remains elusive. Clinical, histopathological and immunohistochemical features are suggestive of a viral etiology.<sup>2</sup> Often the diagnosis can be mistaken for SLE, malignant lymphoma or rarely

adenocarcinoma. Also known as histiocytic necrotizing lymphadenitis, it is characterized by paracortical lymph node expansion with patchy, well circumscribed areas of necrosis showing abundant karyorrhectic nuclear debris and absence of neutrophils and eosinophil.<sup>3</sup> This paper reports a case of an even rarer picture of the disease with asymptomatic presentation in a young Indian woman.

## Case Summary

A 26 years old female, came to surgery OPD with a complaint of swelling at the left side of neck which she noticed around 1.5 months back. It was

not associated with pain, discomfort or skin changes. No history of fever, fatigue and weight loss. No history of cough, cold, throat pain, ear pain or discharge from eye. No history of rashes or swelling at any other site of the body. No history of joint pain, abdominal or back pain. On examination she was conscious, oriented, afebrile, well-nourished and adequately hydrated. Blood pressure = 118/78 mmHg, Pulse Rate = 84/min, chest - bilateral air entry present, equal and clear, no added sound was heard. CVS - s1 s2 heard, no murmurs. Per abdomen- soft, non-tender, non-distended with audible bowel sounds. Local examination revealed a hard mass palpable in the left posterior triangle of neck about 2 x 2 cm in size, mobile, and non-tender with no skin changes or discharge. The patient was investigated. Total and differential leukocyte count were 8500/mm<sup>3</sup>, neutrophils/lymphocytes/eosinophil/basophils = 68/30/2/0. Chest X-ray was normal. Serum CRP level was normal. A diagnosis of cervical lymphadenopathy under evaluation was made. The mass was excised under general anesthesia. A total of 2 lymph nodes measuring 1.5x1.5 cm and 1x1 cm were excised & sent for histopathological examination. Histopathological examination of excised lymph nodes showed histiocytic necrotizing lymphadenitis. On Immunohistochemistry staining, CD 68 strongly positive in histiocytic cells, Suggestive of Kikuchi lymphadenitis. (FIG 1)



**Fig 1.** Microphotograph showing histiocytes

### Case Discussion

Kikuchi Fujimoto disease is a rare presentation of cervical lymphadenitis. The asymptomatic presentation of Kikuchi Fujimoto disease is far rarer. The most of cases reported in medical literature are symptomatic either with fever & autoimmune lymphadenopathy.<sup>4</sup> The differential diagnosis of Kikuchi Fujimoto disease includes granulomatous lymphadenopathy, lymphoma, tubercular lymphadenitis & auto-immune lymphadenopathy.<sup>5,6</sup> In our case, there was no symptom. The patient presented with cervical lymphadenopathy. The multiple lymph nodes present in the neck were subjected to excision biopsy. The histo-pathological report confirmed the diagnosis i.e Kikuchi Fujimoto disease. There are three histological varieties: proliferative, necrotizing & xanthomatous.<sup>7</sup> In our case, it was proliferative variety, no necrotic changes were seen in histopathological examination. On immunohistochemistry histiocytes were positive for CD68. The patient was investigated for Systemic Lupus Erythematosus. Serum CRP, TLC & DLC, Chest X-ray were normal, which ruled out diagnosis of pulmonary tuberculosis.

### Take Home Message

We have reported this case because Kikuchi Fujimoto disease is a rare disease entity. The presentation in this case was asymptomatic. The presence of cervical lymph nodes in absence of any clinical symptom. The diagnosis of Kikuchi Fujimoto disease was possible only on excision biopsy of lymph nodes & histopathological examination.

### References

1. Martins SS, Buscatti IM, Freire PS, Cavalcante EG, Sallum AM, Campos L, Silva CA. Kikuchi-Fujimoto disease prior to childhood-systemic lupus erythematosus diagnosis. *Rev Bras Reumatol.* 2014;54(5):400-3.

2. Mahajan T, Merriman RC, Stone MJ. Kikuchi-Fujimoto disease (histiocytic necrotizing lymphadenitis): report of a case with other autoimmune manifestations. Proc (Baylor University Medical Center) 2007; 20: 149-151.
3. Pepe F, Disma S, Teodoro C, Pepe P, Magro G. Kikuchi-Fujimoto disease: a clinicopathologic update. Pathologica. 2016 Sep 1;108(3):120-129
4. Perry AM, Choi SM. Kikuchi-Fujimoto disease: a review. Arch pathol lab med. 2018 Nov 1;142(11):1341-1346
5. Lamzaf L, Harmouche H, Maamar M, Adnaoui M, Aouni M, Mezalek ZT. Kikuchi-Fujimoto disease: Report of 4 cases and review of the literature. European annals of otorhinolaryngology, head and neck diseases. 2014;131(6):329-332
6. Jamal AB. Kikuchi. Fujimoto disease. Clin med insights arthritis and Musculoskeletal Disord. 2012; 5:63-6.
7. Khanna D, Shrivastava A, Malur PR, Kangle R. Necrotizing lymphadenitis in systemic lupus erythematosus: is it Kikuchi-Fujimoto disease?. JCR: Journal of Clinical Rheumatology. 2010 Apr 1;16(3):123-124.