



## Case Report

# FLI-1 Positive Ewing's sarcoma with partial collapse of 6th dorsal vertebra in a girl aged 13 years: A case report

Authors

Supriya Mehrotra<sup>1</sup>, Bandana Mehrotra<sup>2</sup>, Sanjay Mehrotra<sup>3</sup>,  
Ashok Kumar Kapoor<sup>4</sup>, Hari Shyam<sup>5</sup>

<sup>1,2,4</sup>Pathologist, Department of Pathology, RML Mehrotra Pathology Pvt. Ltd, Nirala Nagar, Lucknow, Uttar Pradesh, India

<sup>3</sup>Director, RML Mehrotra Pathology Pvt. Ltd, Nirala Nagar, Lucknow, Uttar Pradesh, India

<sup>5</sup>Technologist, Department of Pathology, RML Mehrotra Pathology Pvt. Ltd, Nirala Nagar, Lucknow, Uttar Pradesh, India

Corresponding Author

**Dr Ashok Kumar Kapoor**

RML Mehrotra Pathology Pvt. Ltd. B-171, Nirala Nagar, Lucknow- 226020, Uttar Pradesh, India

## Abstract

*A female patient, aged 13 years had pain in back with paraplegia. Radiological examination revealed partial collapse of 6<sup>th</sup> dorsal vertebra. Tissue pieces were collected from diseased vertebra and examined histopathologically. The patient was finally diagnosed as a case of Ewing's sarcoma of a vertebra.*

**Keywords:** Malignant bone tumor, immature neuroectodermal cells, dorsal vertebra.

## Introduction

Ewing's sarcoma (EWS) might be an infrequent malignant tumor of pediatric age-group. It might arise from a neuroectodermal mesenchymal immature cell. Tumor is more common in boys when compared with girls (male/female ratio 2:1). Tumor is very rare in non-caucasians. Most of the Ewing's sarcomas might show reciprocal translocation between 11 and 22 chromosomes. It may result in formation of a fusion gene product EWS/FLI-1 (Friend leukemia virus integration site 1) which might be tumorigenic<sup>[1]</sup>. Moreover, EWS/FLI-1 positive cells might develop growth arrest due to p53 inhibition<sup>[2]</sup>. Tumor might show

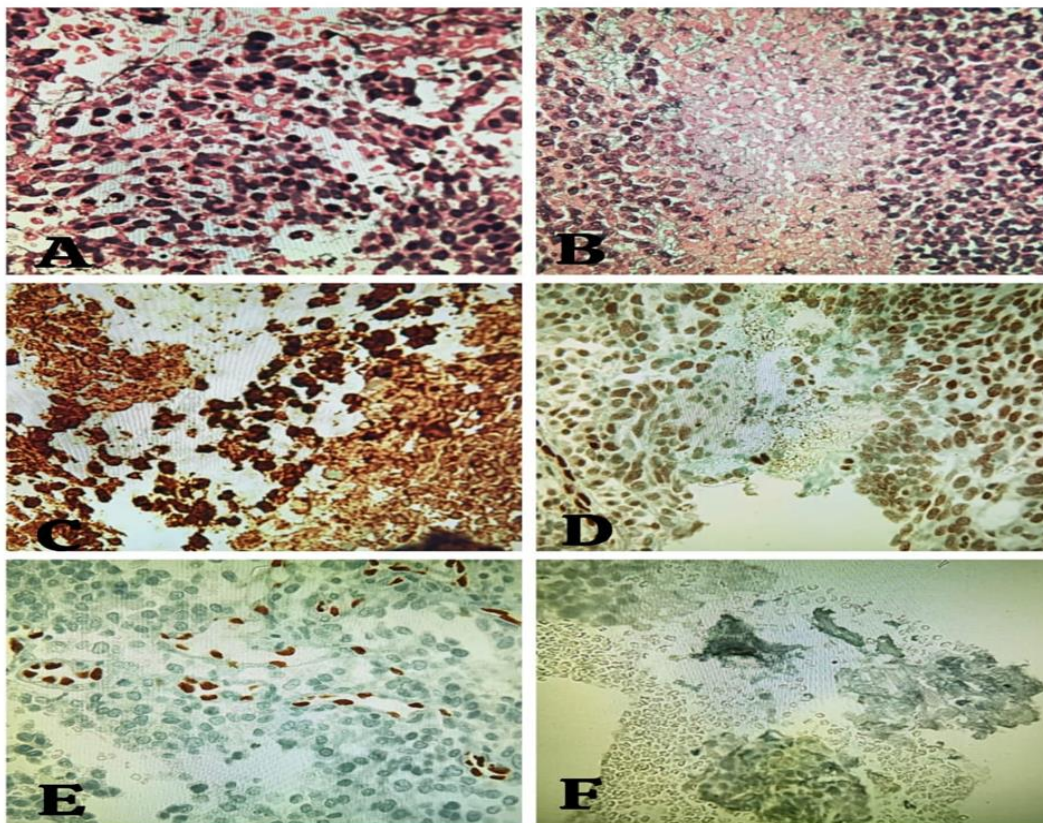
small, uniform round cells with glycogen-filled cytoplasm. PAS might demonstrate plenty of intracellular glycogen. Tumor cells might be twice the size of small lymphocytes. Tumor consisted of blue round cells with high nuclear cytoplasmic ratio with scarcity of mitoses. In addition, the patient had pain and partial collapse of 6<sup>th</sup> dorsal vertebra. Fever and leucocytosis might also follow. She was operated and small pieces of tumor tissue were sent to us for histopathological examination. X-ray examination might show expansile midshaft tumor with cortical destruction and poor demarcation and delicate periosteal reaction. Tumor might invade medullary cavity

without destruction of bony trabeculae<sup>[3]</sup>. Herewith, we report a case of skeletal Ewing's sarcoma in a adolescent girl.

### Case Report

A patient, aged 13 years female complained of pain in dorsal 5<sup>th</sup> and 6<sup>th</sup> vertebrae for last 7 days. MRI revealed partial collapse of 6<sup>th</sup> dorsal vertebra. There was no history of weight-loss. She was operated and multiple brown black soft tissue pieces, measuring 1.2×0.8×0.3 cm were collected for histopathological examination. Sections showed several bony trabeculae and a

small portion of the tumor. Tumor comprised of proliferated small round or ovoid cells with high nuclear cytoplasmic ratio and mild hyperchromatism. Tumor cells were disposed diffusely as well as in sheaths. Areas of coagulative necrosis were also seen. IHC examination revealed strong positive reaction with anti-CD99 and anti-nuclear foetal liver infusion-I (FLI-I) antibodies. Tumor cells failed to react with anti-ERG, anti-synaptophysin, anti-pancytokeratin and anti-CD45 antibodies. The tumor was finally diagnosed as skeletal Ewing's sarcoma.



**Figure 1:** (A) Photomicrograph showed tumor tissue. Tumor comprised of small round cells with anisonucleosis and mild hyperchromatism. Findings were suggestive of Ewing's sarcoma (HE×400). (B) Photomicrograph showed tumor tissue with thick band of coagulative necrosis (HE×400). (C) IHC using anti-CD99 antibody showed strong cytoplasmic positivity (3+) with tumor-associated antigen. (D) IHC using anti-FLI-1 antibody showed strong positivity with tumor cells. (E) IHC using anti-ERG antibody revealed a negative reaction. (F) IHC using anti-synaptophysin antibody also showed a negative reaction.

## Discussion

Ewing's sarcoma was initially reported by James Ewing in 1924<sup>[4]</sup>. Ewing's sarcoma is the second most common malignant bone tumor after osteosarcoma. About 25 cases of Ewing's sarcoma were reported each year in North America. Most of the cases were reported in second decade as the current patient. The oldest patient, reported to be suffering from extra-skeletal Ewing's sarcoma, was a 77-year-old female<sup>[5]</sup>. Upto the year 2018, sixty-nine cases of spinal Ewing's sarcoma were reported in literature. These cases had primary or metastatic vertebral lesion. The patient clinically presented with spinal cord and /or radicular compression<sup>[6]</sup>. Another feature of present case was pain. Pain occurred intermittently and did not disappear during night hours. Another feature of present case was vertebral involvement; current tumor developed in a thoracic vertebra. Six percent cases were known to involve vertebral spine<sup>[1]</sup>. Primary involvement of non-sacral spine is extremely rare<sup>[7,8]</sup>. However present case appeared to be a primary Ewing's sarcoma. Ewing's sarcoma arises from diaphysis. Further, Ewing's sarcoma may have high probability of recurrence. Bone marrow metastasis may occur in <10% of cases<sup>[4]</sup>. Patients with bone marrow metastases may die within 2 years, suggesting poor prognosis<sup>[4]</sup>.

## Conclusion (S)

A 13-year-old female presented as a case of FLI-1 positive Ewing's sarcoma. Most of the cases (80%) of Ewing's sarcoma are believed to be FLI-1 positive. Reciprocal translocation between chromosome 11 and chromosome 22 may result in formation of a fusion protein FLI-1/EWS which may be oncogenic. Primary Ewing's sarcoma involving thoracic vertebra is very rare. Our case had primary vertebral neoplasm with destruction of bony trabeculae. Further, anti-endothelial growth factor antibody might target FLI-1/EWS protein.

## References

1. Bernstein M, Kovar H, Paulussen M, Randall RL, Schuck A, Lisa A et al. Ewing's sarcoma family of tumors: Current management. *The Oncologist* 2006;11:503-519.
2. Lessnick S, Dacwag CS, Golub TR. The Ewing's sarcoma oncoprotein EWS/FLI induces a p53- dependent growth arrest in primary human fibroblasts. *Cancer cell* 2002;1(4):393-401.
3. Schiller AL, Wang BY, Klein MJ. Ewing sarcoma is a primitive neuroectodermal tumor of childhood. *Rubin's Pathology*, 4th edition, Lippincott Williams and Wilkins 2005, P1358-60.
4. Ewing J. Further report of endothelial myeloma of bone. *Proc NY Pathol Soc* 1924; 24:93-100.
5. Cheung CC, Kandel RA, Bell RS, Mathews RE, Danny M, Chazarian D. Extraskeltal Ewing Sarcoma in a 77-years-old women. *Arch Pathol Lab Med* 2001;125:1358-60.
6. Cherraqi A, Lambrabet A, Dokal ID, Lrhorfi N, Belghiti H, Allahi N. Primary Ewing's sarcoma of the spine: About a Case. *Global Pediatric Health* 2022;9:1-5.
7. Yan D, Zhang J, Zhong D. Ewing's sarcoma in the spinal canal of T12-L3: A case report and review of the literature. *Oncology letters* 2019;18:6157-6163.
8. Mishra MN, Sharma R, Chandavarkar V, Premalatha BR. Pathogenesis of Ewing sarcoma: Existing and emerging trends. *Advances in cancer biology-Metastasis* 2(2021); 100008.