



A Case Report of Dissecting Stroke

Authors

Dr Nivethini.N^{1*}, Dr Uthaya Sankar M. K², Dr Rangarajan D.V³

¹Post Graduate Resident, ²Professor and Unit Chief, ³Senior Resident

Department of Internal Medicine, Sri Manakula Vinayagar Medical College and Hospital - Puducherry

*Corresponding Author

Dr Nivethini.N

Abstract

Acute, painful Horner syndrome can be the presenting manifestation of an extracranial internal carotid artery (ICA) dissection, which is important to identify because of the high risk of stroke. Internal Carotid artery dissection (ICAD) has an incidence of 2.6-3.0 per 100,000, whereas spontaneous ICAD accounts for only 2% of all ischemic strokes. ICAD presents as Horner's syndrome in about 36-58% and this is a case of Internal Carotid Artery dissection presenting as Horner's syndrome. ICAD involves tear in the inner lining of the carotid artery, leading to the formation of a blood clot. This can reduce blood flow to the brain, leading to ischemic stroke, but it can also cause dissection of the sympathetic nerves that run alongside the carotid artery, resulting in Horner's syndrome. Therefore, the coexistence of these two conditions in the same patient presents a fascinating clinical scenario. Although Carotid endarterectomy is the main modality of treatment, anticoagulants and antiplatelet can be given.

Keywords: *Internal Carotid artery dissection, Partial Horner's syndrome, Mild Ptosis.*

Case Report

This is a case of 53 years old Male who is an Alcoholic with no co-morbidities presented with Chief Complaints of Headache and Right Eye Pain for 3 days with History of decreased sweating in the right side of the face. General Examination: Conscious, Oriented, Dryness present over Right Eye. Vitals: Pulse Rate - 82 bpm, BP-180/100mmHg measured in Right arm in sitting position Left Arm: 180/100mmHg. Central

Nervous System Examination: Higher Mental Functions - Normal, GCS: 15/15, Cranial Nerve : Optic Nerve:

Visual acuity 6/6 in both eyes, Field of vision restricted superiorly in right eye, Color vision-normal in both eyes. Oculomotor nerve: Extra ocular movements normal in both eyes, Right Eye: Pupil size - 2mm, Light and Accommodation reflex was normal, Ptosis present, Ciliospinal reflex –

Absent. Left eye – Pupil Size 3mm, Light and Accommodation reflex was normal. Motor, Sensory and Cerebellar examination was normal. Cardio vascular system examination: S1 S2 heard, no murmurs. Respiratory system normal vesicular breath sounds heard. Abdomen examination- Soft, Non tender, no organomegaly.

All routine Investigations done which was normal. 2D Echo showed normal study with EF-60%. A provisional diagnosis of Horner's Syndrome was made in view of identifying the site of lesion, Hydroxyamphetamine test was done. Hydroxyamphetamine drops instilled into the eye in which no response in Right eye which arises clinical suspicion of Postganglionic nerve fibres involvement. MRI Brain done showed Right Internal Carotid Artery dissection C2 and C3 segments (Petrous and Lacerum part). Carotid vessel doppler showed atheromatous plaque in Left carotid bulb causing <10% stenosis. Thus, diagnosis was made as Right Internal Carotid Artery dissection with Right Side Partial Horner's Syndrome and Systemic Hypertension.

Patient was initially treated with Salt Restricted diet, Antihypertensive, Dual Antiplatelet and was planned for Carotid endarterectomy.

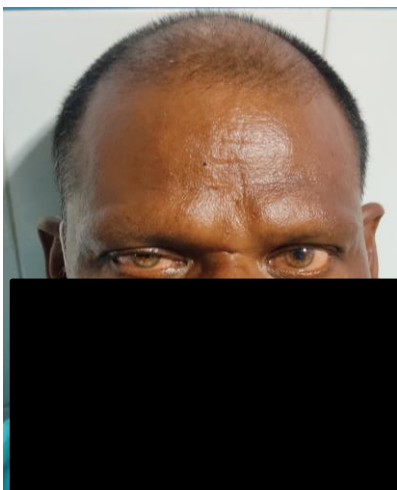


Fig1: Showing Right Eye Ptosis

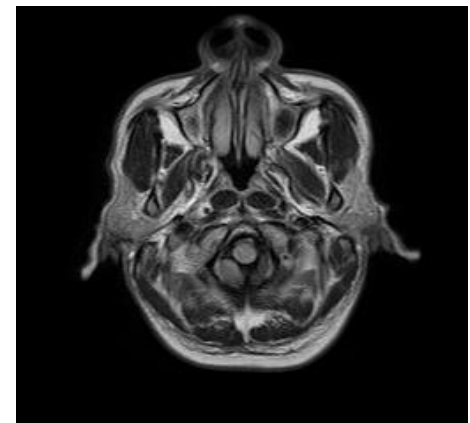
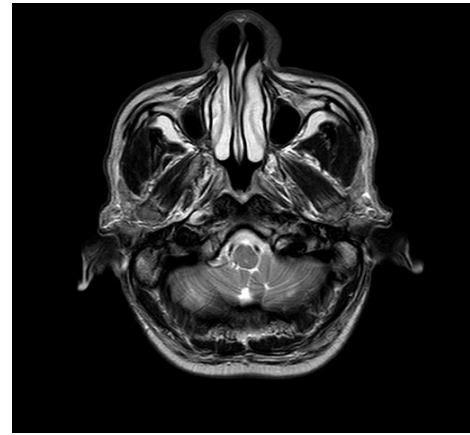


Fig 2,3: MRI Brain done showed Right Internal Carotid Artery dissection C2 and C3 segments (Petrous and Lacerum part).

Discussion

Horner syndrome should always be considered in a patient presenting with anisocoria >5mm, ipsilateral ptosis, dilatation lag of the smaller pupil, Facial flushing, Headache, Loss of Ciliospinal Reflex and a history of anhidrosis.

To localise the lesion (Central, Preganglionic and Postganglionic), Hydroxyamphetamine test can be done. The testing will cause dilatation of the affected pupil in case of preganglionic, because the postganglionic neurons innervating the dilator muscle are intact and have NE stores. If the lesion is Postganglionic, NE stores will be depleted resulting in less dilatation of the denerved affected pupil compared to the contralateral normal eye resulting in anisocoria. ICAD is a Postganglionic (3rd order neuron) involvement.

Symptoms of ICAD include Headache, Anterior neck pain, Scalp tenderness, Transient ischemic attack, Cerebral infarction, Amaurosis fugax,

Cranial nerve palsies, Tinnitus and Horner's syndrome. ICAD presents as Hemiparesis in 10% of the patients.

The gold standard for diagnosing ICAD is conventional arteriography, but MRA is replacing it. Computerized tomographic angiography is more available and may be used for the diagnosis, although there is less experience. Ultrasonography has been increasingly used in the diagnosis of ICAD

The therapeutic modalities available for Internal Carotid artery dissection are Antiplatelet, Anticoagulant and Carotid Endarterectomy.

The prognosis of ICAD is highly variable. It is excellent when it is diagnosed with local signs. Clinical functional outcome depends on the initial stroke severity. The mortality rate is less than 5%. 85–90% of patients will have complete resolution in 3–6 months, and headache resolves in 95% of individuals with appropriate therapy. Symptomatic recurrent ICAD is uncommon (2% during the first month) and mainly occurs in a different artery

References

1. Teixeira JC, Jackson PJ. Internal Carotid Artery Dissection Presenting as Partial Horner's Syndrome and Vertigo. *Military medicine*. 2020 Sep 18;185(9-10):e1840-2.
2. Kikkeri NS, Nagarajan E, Sakuru RC, Bollu PC. Horner syndrome due to spontaneous internal carotid artery dissection. *Cureus*. 2018 Sep 28;10(9).
3. Alonso Formento JE, Fernández Reyes JL, Envid Lázaro BM, Fernández Letamendi T, Yeste Martín R, Jódar Morente FJ. Horner's syndrome due to a spontaneous internal carotid artery dissection after deep sea scuba diving. *Case Reports in Neurological Medicine*. 2016 Jan 1;2016.
4. Wole B, Diel RJ, Stiff HA, Kardon RH. Horner syndrome due to ipsilateral internal carotid artery dissection