



Case Report

Giant Chorioangioma in a Patient with 36 Weeks of Pregnancy: A Case Report

Authors

Bandana Mehrotra¹, Sanjay Mehrotra², Ashok Kumar Kapoor³,

Mithlesh Bhargava⁴, Divya Arora⁵, Rahul Kumar Pandey⁶, Supriya Mehrotra⁷

^{1,3,4,5,7}Pathologist, Department of Pathology, RML Mehrotra Pathology Pvt. Ltd, Nirala Nagar, Lucknow, Uttar Pradesh, India

²Director, RML Mehrotra Pathology Pvt. Ltd, Nirala Nagar, Lucknow, Uttar Pradesh, India

⁶Technologist, Department of Pathology, RML Mehrotra Pathology Pvt. Ltd, Nirala Nagar, Lucknow, Uttar Pradesh, India

Corresponding Author

Dr. Ashok Kumar Kapoor

RML Mehrotra Pathology Pvt. Ltd. B-171, Nirala Nagar, Lucknow- 22602, Uttar Pradesh, India

Abstract

Present report relates to a 40-year-old patient with 36 weeks of pregnancy and non-trophoblastic benign placental neoplasm chorioangioma (placental hemangioma). The incidence of chorioangioma has been described as 0.5 to 1.0 % of all pregnancies. Tumors may be >4 cm in diameter; such tumors are called giant tumors. Smaller tumors are generally asymptomatic. However, clinically-significant chorioangioma occur less frequently; incidence varying from 1 in 3500 to 1 in 9000 pregnancies. Giant chorioangiomas are very rare tumors; only a few cases have been reported. Feto-maternal complications like fetal growth retardation, anemia and hydrops may develop in a patient with chorioangioma. Further, fetal loss may be as high as ~ 40 %. Increased incidence of chorioangiomas may occur at high-altitude pregnancies, suggesting role of hypobaric hypoxia in pathogenesis of chorioangioma.

Keywords: Well-circumscribed benign placental neoplasm.

Introduction

Placental chorioangioma was first reported by Clarke in the year 1798^[1]. It is a benign non-trophoblastic neoplasm. It appeared to arise from a primitive vascular mesenchymal cell. Etiology of chorioangioma is still not clear. Most of the patients are aged >30 years. Tumor is comprised

of numerous small dense capillaries and loose fibrous tissue^[2]. The differential diagnosis may be chorioangiosis. Chorioangiosis is capillary hyperplasia with > 10 capillaries in 10 villi; while normal villus has 5 capillaries/villus. Main difference between chorioangioma and hemangioma is that villi are not seen in

Chorioangioma. Single case of Giant chorioangioma has been described from Indonesia [3]. Chorioangiocarcinoma may be another differential diagnosis. In this lesion, proliferation of trophoblastic tissue is also seen along with chorioangioma - like appearance [4]. Patient was finally diagnosed as Giant chorioangioma.

Case Report

A patient aged 40 years female had a placental tumor. Tumor was round and cut surface showed solid lobulated greyish-white appearance. Tumor was well circumscribed; it measured 9×6×5 cm. Tumor arose from chorionic plate on fetal side. Outer placental surface showed ruptured amniotic

membranes; maternal surface contained blood clots. Umbilical cord measured 25 cm in length. Ultrasonography revealed a tumor arising from fetal side of placenta. She underwent emergency caesarean delivery at 36 weeks gestation. Microscopically, solid sheets of proliferated endothelial cells were seen, forming blood vessels with surrounding stroma (figure 1a). Mild anisonucleosis was seen. Several dilated and congested vessels were seen along with areas of haemorrhage and focal hyalinization. Immunohistochemistry examination revealed strong positivity (3+) of tumor cells with anti-CD 31, anti-CD 34 and anti-Glut-1 antibodies (figure 1a-c).

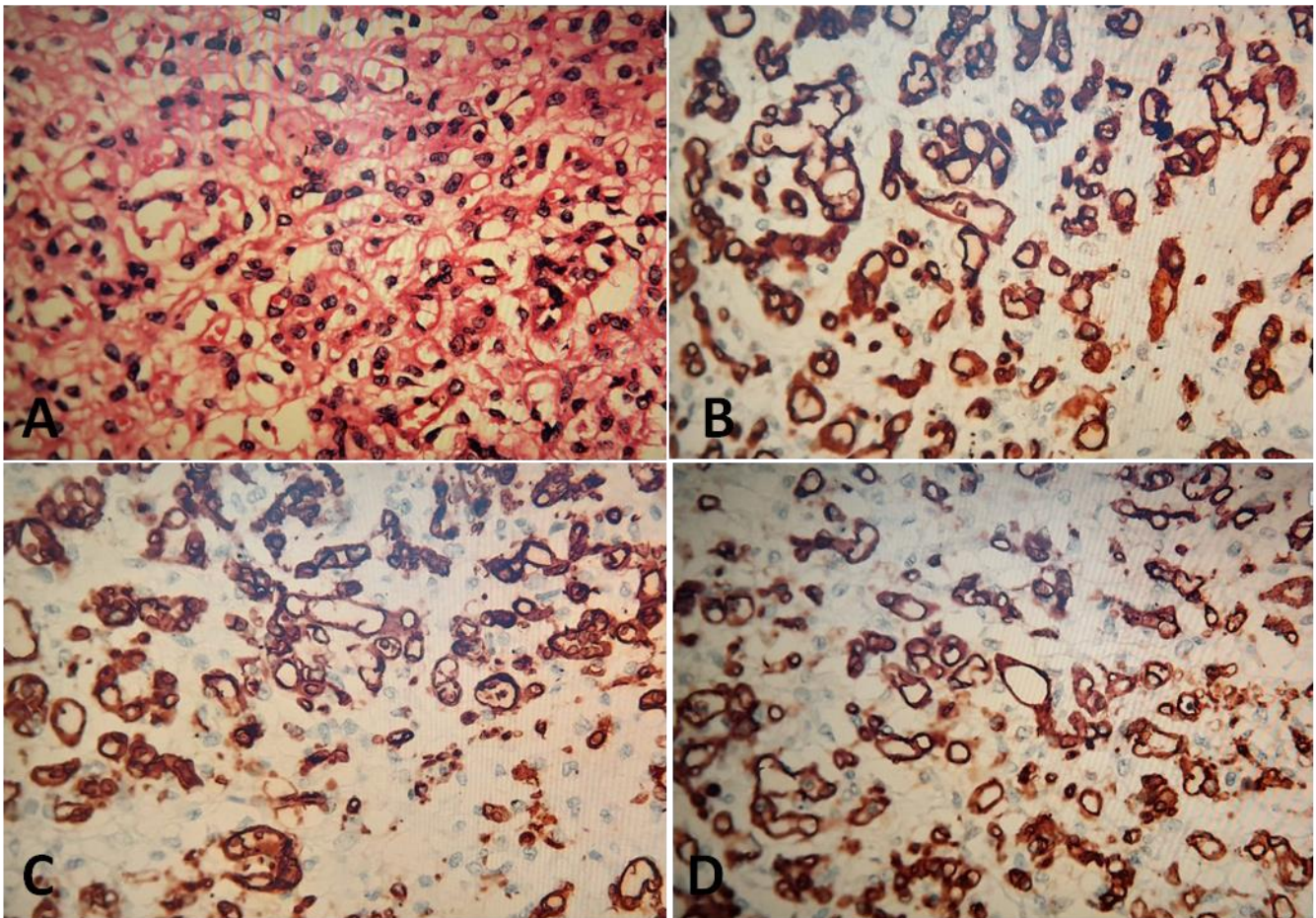


Figure 1: (A) Photomicrograph shows proliferated endothelial cells, forming irregular round spaces of variable size. (B) Tumor cells shows strong positivity (3+) with anti-CD31 antibody. (C) Photomicrograph shows strong positivity (3+) with anti-CD34 antibody. (D) Photomicrograph shows strong positivity (3+) with anti-Glut-1 antibody.

Discussion

Most important feature of current tumor was its size. Giant-sized (>4 cm) tumors appear to be symptomatic while small-sized tumors do not develop symptoms. In addition, giant-sized chorioangiomas may produce fetomaternal complications. Large giant-sized tumors may produce deficiency of nutrients and hypoxia in fetus^[3]. In addition, IHC findings of current tumor showed focal positivity for cytokeratin (\pm) and strong positivity (3+) of endothelial cells with anti-CD 31, anti-CD34 and anti-Glut-1 antibodies. Results of IHC findings suggested the origin of current tumor from blood vessels of chorionic plate and villi^[4,5]. Tumor comprised of proliferated endothelial cells forming capillaries and surrounding fetal mesenchyme. In addition, tumor cells showed mild anisonucleosis. However, aggressive behavior has not been reported with current tumor. Tumor was finally diagnosed as chorioangioma. In addition, 2 prominent feeding vessels were seen in the tumor. Feeding vessels appeared to provide nutrition to rapidly multiplying tumor cells. Another feature of current tumor was 'stealing' phenomenon which might deviate blood from high vascular resistance site to low vascular resistance area, resulting in fetal anemia, congestive heart failure (CHF) and fetal hydrops^[6,7]. Giant-sized tumors may cause several perinatal complications, e.g. arteriovenous shunts might develop which might produce increased blood volume of the fetus leading to polyhydramnios and CHF^[8]. Similar giant tumor with a maximum diameter of 10 cm has been reported^[9]. Further, the incidence of giant chorioangioma might vary from 1/3500 to 1/9000 to pregnancies^[10,11].

Conclusion (S)

Placental pathology confirmed the diagnosis of giant Chorioangioma following delivery at 36 weeks of gestation.

Financial support and sponsorship: Nil

References

- Clarke I: Account of a tumor found in substance of the human placenta. *Philos Trans* 1798 ; 88: 361-8.10.1098 / rstl.1798 : 0016
- Sun X, Zhao H, HaO I, Lu L, GuY: Clinicopathological characteristics of placental chorioangioma: a clinicopathological study of 77 cases. *Ann Diagn Pathol* 2022 ; 57 : 10
- Theresia E, Nurdiati DS , Widodo I. Giant placental chorangioma : The first case report in Indonesia . *Human Pathology: case reports* 2021 ; 23: 200472
- Kataria N, Singh A, Bedi PK. Giant placental chorangioma : A rare case report. *J Clin Diag Res* 2016; 10 (4) ED3 - ED4
- Lez C, Fures Z, Hrgovic S, Bellina J, Fajdie K, Muenstedt. Chorioangioma placenta. *Rare Tumors* 2010 ; 2 (4): 67
- Kesrouani Ak, Safi J, El Haji MA. Rapid evolution of placental chorioangioma: natural progression and outcome. *J Ultras Med* 2013; 32: 545-7
- Hongwei Ma , Zilling L , Jie R. Placental Chorioangioma and pregnancy outcome : A ten year retrospective study in a tertiary referral centre. *Res Square* 2023; p1-15
- Schenone CV, Rodriguez A, Duncan J, Steffensen T, John B, Obican S. Giant placental chorioangioma and severe ductal arch constriction : A case report with a favorable outcome. *Cureus* 2023 ; 15 (4) e38209
- Shiraga A, Ohsuga T, Kawasaki K, Mogami H, Minamiguchi S. A case of placental multiple giant chorangioma leading to neonatal death from fetal hydrops. *Case report. Perinat Med* 2023;12 (1) 2022008
- Dong T, Luo Q. Pregnancy complications and adverse outcomes in placental chorioangiomas-a retrospective cohort analysis. *J Matern Fetal Neonatal Med* 2018; 1: 5

11. Zou J, Ding W; Chen Q, Bai X, Li B.
Safety of vaginal delivery in women with
placental chorioangiomas diagnosed by
prenatal ultrasound: A retrospective cohort
study. *Medicine (Baltimore)* 2022; 101
(29): e 29672