



Spontaneous Esophagopleural Fistula Presenting As Right Sided Hydropneumothorax

Authors

**Dr. Goutam Kumar Paramanik, Asso. Prof. & HOD Dr. Rekha Manjhi,
Asst. Prof. Dr. Aurobindo Behera, Asst. Prof. Dr. Gourahari Pradhan**

Abstract

Introduction: *Esophagopleural fistula (EPF) is an uncommon condition despite the anatomical proximity of the trachea and esophagus. Spontaneous development of a fistula between the esophagus and pleura is rarely described in the literature.*

Case Report: *A 45 years old male was presented with multiple episode of vomiting, retching following intake of alcohol for 1 day associated with retrosternal chest pain radiating to back with sudden onset of dyspnea & dry cough. CXR s/o right lower zone pneumonia with parapneumonic effusion with B/L subcutaneous emphysema, Repeat CXR showed hydropneumothorax (right). Intercostal chest drainage was inserted. UGI endoscopy showed esophageal ulcer in distal part, HRCT thorax with oral contrast showed a fistulous tract of size 2-3 cm in lower 1/3rd of esophagus connecting to right pleural cavity, Right hydropneumothorax with ICT in-situ with B/L lung consolidation with left mild PLEF.*

Conclusion: *Spontaneous development of EPF is an unusual condition entity with nonspecific clinical presentation. CT of chest is a very useful modality for early diagnosis and management of EPF. Management of the EPF depends on site, size, duration, and severity of perforation.*

Introduction

Esophagopleural fistula is an uncommon condition despite the anatomical proximity of the trachea and esophagus. Causes include pneumonectomy for suppurative or tubercular disease and carcinoma of the lung and malignancy of the esophagus. Non malignant fistula is due to trauma or infection.⁽¹⁾ The most common infectious cause is tuberculosis followed by syphilis, mycotic disease and Crohn's disease. Perforation of the esophagus and subsequent fistula formation can occur as a result of foreign bodies, Barrett's ulcer and more rarely Boerhaave's syndrome. Spontaneous development

of a fistula between the esophagus and pleura is rarely described in the literature.

Case Report

A 45 years old male presented to emergency department with sudden onset of vomiting after taking alcohol which was non projectile, non-billious, containing semi digested food particle, non foul smelling, not associated with hematemesis. He developed cough which was sudden in onset, dry in nature, aggravated on taking food or water, associated with chest pain which was dull aching, retrosternal radiating to back and aggravated while coughing or vomiting. There was no history of orthopnea or PND or

pedal edema or loss of appetite or weight loss or fever or pain abdomen. No Past history of any trauma/surgery/instrumentation or similar past history or any other chronic disease. He was an alcoholic.

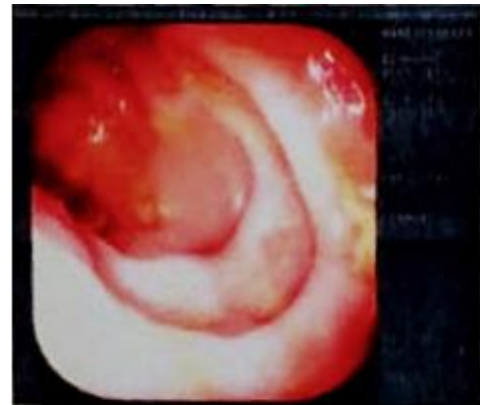
At the time of admission, on examination patient was healthy with BMI of 26.51kg/m², swelling of neck, fullness of bilateral supraclavicular Area, Pulse Rate- 110/min, regular, good volume, SpO₂- 86% in room air, Respiratory Rate- 28/min, abdomino-thoracic, BP- 100/70 mm of Hg, Temperature- 98.2°F, No Pallor/icterus/cyanosis/clubbing/lymphadenopathy/edema, Respiratory system examination revealed decreased movement of lower part of right side of chest, subcutaneous emphysema over neck and b/l chest wall, Vocal Fremitus decreased in right IAA, ISA, Percussion dull over Right 5th, 6th, 7th ICS downwards along MCL, MAL, SL respectively, Decreased breath sounds over right Infrascapular, infra axillary area, fine late inspiratory crepitation over right mammary area, Vocal resonance is diminished over right IAA & ISA.

On day 1 CXR showed B/L subcutaneous emphysema, with pneumomediastinum and right lower lobe pneumonia with parapneumonic effusion. ECG was within normal limit and RAT and RTPCR for COVID-19 was negative. Blood parameters revealed TLC -16, 800, N86L8M5E1, Hb-10. 3, PLT-1.98, LFT & RFT were within normal limit, Viral markers (HIV, HBV, HCV) were non reactive. USG guided 100ml of straw colored pleural fluid was aspirated. Analysis revealed ADA-10, Protein-4.3, albumin-2.4, LDH-470, Neutrophilic, without any atypical cells.

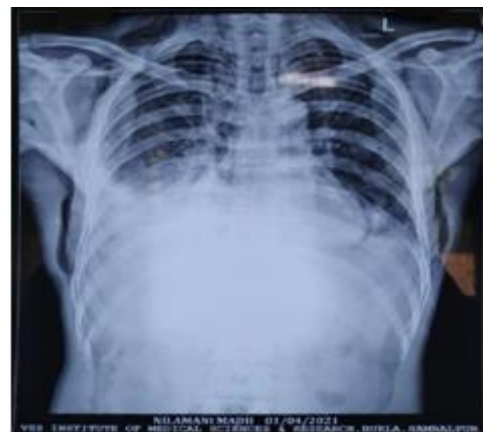On day 6 Pt gradually developed progressive Shortness of breath and increased frequency of cough with production of yellowish foul smelling sputum, Stony dullness and breath sound diminished over right hemithorax. Repeat CXR s/o right side massive hydropneumothorax, Sputum- AFB and CBNAAT were negative for M. Tb, G/S s/o pus cells with no bacteria.

On day 8 Intercostal chest drainage was inserted, pus containing food particles were drained, Pus AFB and CBNAAT were negative for Mycobacterium tuberculosis, G/S showed many pus cells without any bacteria, C/S –no growth Upper GI endoscopy showed Distal oesophageal ulcer over right posterolateral wall at 30cm from incisor, No Growth, No Varix, No Stricture, details could not be visualised as patient was non co-operative. HP study showed nonspecific chronic inflammation. Ryle's tube was inserted endoscopy guided

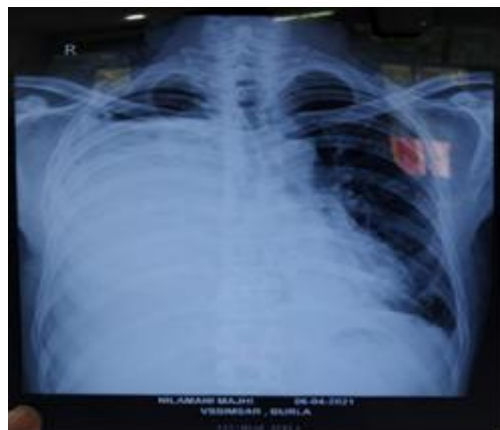HRCT of Thorax with oral contrast showed a fistulous tract of size 2-3 cm in right lower 1/3rd of esophagus connecting to right pleural cavity, oral contrast was noted in right pleural cavity, right hydropneumothorax with ICT in-situ with bilateral lung consolidation with left mild pleural effusion.



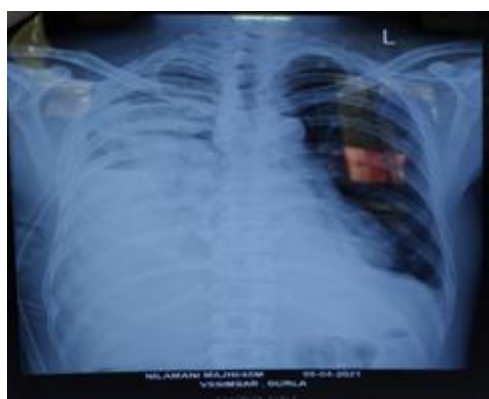Upper GI Endoscopy



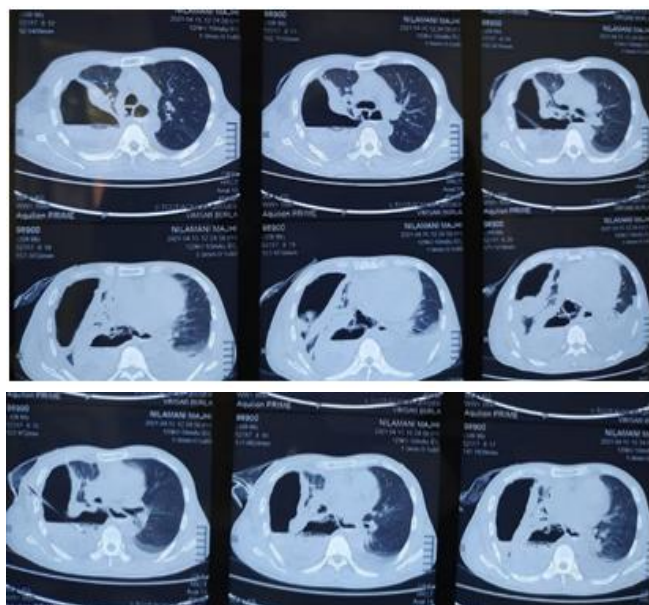
CXR on Day 1



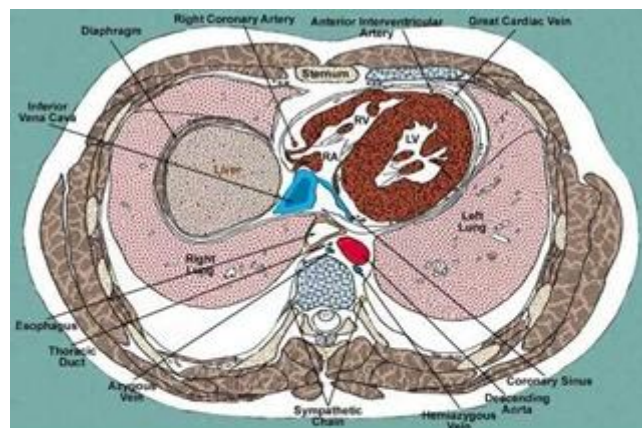
CXR on Day 6



CXR on Day 8



HRCT Thorax with oral contrast



Anatomical relationship between esophagus and pleura

Discussion

EPF is an uncommon complication of iatrogenic trauma (endoscopic instrumentation) or post pneumonectomy.⁽²⁾ A number of possible causes for the development of EPF following pneumonectomy for suppurative disease of the lung have been suggested.⁽³⁾ Anatomically, the esophagus lies much closer to the right hemithorax than to the left, the left being separated from the pleural cavity by the aorta. The site of perforation depends on the cause. The possibility of direct EPF and extent of mediastinitis are determined by the anatomic relationship of the esophagus and the pleura, the amount of mediastinal fat and intervening connective tissue.⁽⁴⁾

The diagnosis of EPF is difficult because the clinical signs and symptoms are nonspecific. Esophageal injury should be considered when a patient presents with retrosternal chest pain, fever, dysphagia and dyspnea, especially when the patient gives antecedent history of instrumentation or surgery. The diagnosis of EPF can be suspected clinically; however, for confirmation imaging is required. The imaging modalities include chest radiograph, ultrasound, barium swallow, contrast-enhanced computed tomography (CT), and magnetic resonance imaging (MRI) with each modality having its advantages, and chest CT is a very useful modality.

EPF rarely heals spontaneously. Leaks of the esophagus are associated with high mortality and the need to be treated as soon as possible. Management depends on site, size, duration, and severity of perforation, mediastinal involvement. Therapeutic options include conservative management with antibiotic therapy, drainage of the empyema, local irrigation, cessation of oral intake by tube feeding gastrostomy or jejunostomy. Followed by definite surgery which includes repair or direct reconstruction of the esophagus. Endoscopic treatment with fibrin glue, clip, suturing, and metallic stents has been described.⁽⁵⁾

We ruled out tuberculosis and malignancy, Patient didn't have any chronic disease or any history of trauma/surgery/instrumentation. So Diagnosis was made as Right side spontaneous esophagopleural fistula. Patient was referred to Dept. Of CTVS, SCBMCH where patient was managed conservatively & improved.

Conclusion

To conclude, spontaneous development of EPF is an unusual condition entity with nonspecific clinical presentation. CT of chest is a very useful modality for early diagnosis and management of EPF. EPF is a fatal condition, timely diagnosis and management can save the patient.

Abbreviations

CXR - Chest Xray, EPF - Esophagopleural Fistula, IAA- Infra Axillary Area, ICT- Intercostal Chest Tube, ISA-Infra Scapular Area, MAL- Mid Axillary line, MCL- Mid Clavicular Line, PND- Paroxysmal Nocturnal Dyspnea, PLEF- Pleural Effusion, SL - Scapular Line, UGI - Upper GI Endoscopy

References

1. Wychulis AR, Ellis FH, Jr, Andersen HA. Acquired nonmalignant esophagotracheobronchial fistula. Report of 36 cases. *JAMA*. 1966;196:117–22. [PubMed] [Google Scholar]

2. Liu PS, Levine MS, Torigian DA. Esophagopleural fistula secondary to esophageal wall ballooning and thinning after pneumonectomy: Findings on chest CT and esophagography. *AJR Am J Roentgenol*. 2006;186:1627–9. [PubMed] [Google Scholar]
3. Takaro T, Walkup HE, Okano T. Esophagopleural fistula as a complication of thoracic surgery. A collective view. *J Thorac Cardiovasc Surg*. 1960;40:179–93. [PubMed] [Google Scholar]
4. Wechsler RJ, Steiner RM, Goodman LR, Teplick SK, Mapp E, Laufer I. Iatrogenic esophageal-pleural fistula: Subtlety of diagnosis in the absence of mediastinitis. *Radiology*. 1982;144:239–43. [PubMed] [Google Scholar]
5. Vandenplas Y, Helven R, Derop H, Malfroot A, De Backer T, Beyens T, et al. Endoscopic obliteration of recurrent tracheoesophageal fistula. *Dig Dis Sci*. 1993;38:374–7. [PubMed] [Google Scholar]