



Role of Plasmapheresis in Acute Yellow Phosphorus Poisoning

Authors

Dr Aparna Jayara and Dr Pratit Samdani

Introduction

There are three major forms of elemental Phosphorus present in environment – white, red and black. Red phosphorus causes discoloration of white phosphorus leading to formation of yellow phosphorus.¹ Yellow phosphorus is used in many industrial products like rodenticides, firework and fertilizers.² Its easy availability makes it impossible to prevent and control the incidence of phosphorus poisoning. Fatal dose of yellow phosphorus is 1mg/kg.³

In our case report we are presenting a case of 41year old male who developed acute liver dysfunction due to yellow phosphorus poisoning and was well managed with plasmapheresis.

Case Report

A 41-year-old male presented with ingestion of rodenticide poison in the form of a 15gm of paste containing 3% phosphorous. On evaluation, patient was hemodynamically stable with sinus tachycardia of 120/min. There was no evidence of hepatic encephalopathy. His INR on admission was 1.61. Arterial blood gas (ABG) analysis was suggestive of compensated metabolic acidosis with serum bicarbonate of 11mEq/L. Later, on the same day patient developed hypotension and was started on vasopressor (i.e. noradrenaline infusion).

He was given full therapeutic dose of N -Acetyl Cysteine (NAC) i.e.150mg/kg in 200 ml D5 over 1hour (as bolus), 50mg/kg in 500ml D5 over 4 hours, 100mg/kg in 1000ml D5 over 16 hours. Along with it, he was given Pantoprazole infusion, injection vitamin K and injection sodium bicarbonate infusion.

Abdominal sonography done on day 3, showed mildly thickened and oedematous gall bladder wall with pericholecystic fluid (image 1).

Abdominal sonography shows mildly thickened and edematous GB wall with pericholecystic fluid

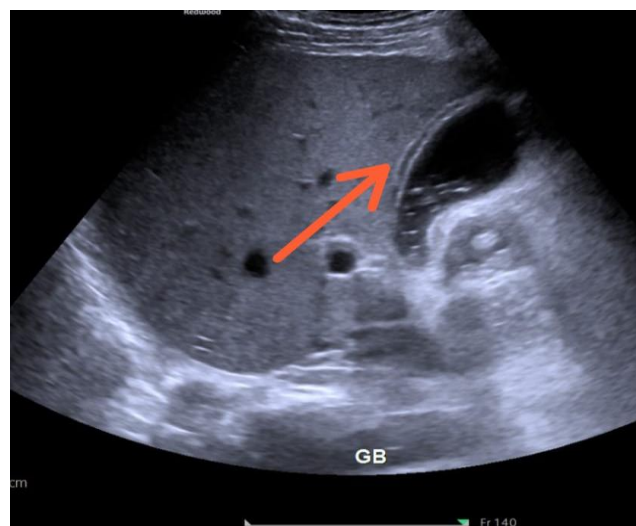


Image 1

On day 3 of toxin ingestion, his INR increased to 2.35. His SGPT was 61 U/L, SGOT was 78U/L. Hispotassium level was 2.5 mmol/L.

2D Echocardiography was done, in which his Left Ventricular Ejection Fraction was 20 % with marked generalized Left Ventricular hypokinesia and severe LV diastolic dysfunction.

On day 4, his INR further increased to 3.56, SGPT and SGOT increased to 1142U/L and 713U/L respectively.

On day 5, his total leukocyte count (TLC) decreased to 1,500/ μ L and his platelet count decreased to 81000/ μ L.

He was given 3 plasma exchange sessions on 5th, 6th and 7th day of his toxin ingestion.

On 6th day, after 2 cycles of plasmapheresis, his INR reduced to 1.9. TLC improved to 2,060/ μ L, and SGPT and SGOT reduced to 711 and 1440 U/L respectively.

His Noradrenaline infusion was completely tapered off on day 8, after 3rd cycle of plasma exchange. His 2 D echo repeated on day 8 which showed his ejection fraction normalized to 45 to 50 % with normal chamber dimensions

Patient was shifted to ward on day 10 of hospital admission.

Patient's Investigations on admission and on subsequent days are tabulated in chart (table 1).

Table 1

	D1	D2	D3	D4	D5	D6	D7	D8	D9	D10
HB (gm%)	14.4	14.8	14.2	13.5	14.4	13	12.1	10.3	10.5	11.5
WBC (/ μ L)	6580	7530	6850	2880	1590	2060	8500	9800	11310	13110
PLT (/ μ L)	3,17,000	2,70,000	2,00,000	1,37,000	81,000	70,000	83,000	1,14,000	1,39,000	1,95,000
INR	1.35		2.35	3.56		1.90			0.98	0.99
POTASSIUM (mmol/L)	4.86	3.72	2.5	2.67	3.33	3.28	2.82	4.31	3.85	5.14
SGOT (U/L)	45	88	78	1142	2892	1440	327	165	133	107
SGPT(U/L)	44	66	61	713	1443	711	315	237	205	189
BILIRUBIN (mg/dL)	0.30	0.43	0.46	1.02	2.97	3.28	4.41	5.05	4.97	3.10
LACTATE(mmol/L)	6.8	2.0	1.2		1.7	1.5	1.1	0.6	0.9	0.8

Discussion

Yellow Phosphorus causes toxicity by an exothermic reaction which leads to free radical production and affects multiple organs.⁴

Fernandez and Canizares in a case series of 15 patients in 1995 and Nalabothu et al in 2015 reported that yellow phosphorus ingestion carries a high mortality.^{5,6}

Usually during the first 48–72 h, only minimal gastrointestinal symptoms are manifested but subsequently acute liver failure ensues, progressing to multi-organ failure and death in extreme cases.^{3,7}

In our patient also, presenting symptoms were typically GI symptoms i.e. abdominal pain and vomiting. On evaluation he had tachycardia (pulse of 120 beats/min), a respiratory rate of 20 counts/min, and a blood pressure of 112/72mmHg in the supine position. Glasgow coma scale score was 15 with ABG showing compensated metabolic acidosis.

In Yellow Phosphorus poisoning, cardiac failure may ensue because of fluid and electrolyte loss (secondary to electrolyte abnormalities such as hypocalcemia and hyperkalemia) due to vomiting or diarrhoea or due to direct cardiac toxicity.^{8,9}

In Our patient hypotension developed after admission and pump function of heart dropped to 20% with generalized LV hypokinesia. It was managed with IV fluids and vasopressors.

There is no specific antidote for yellow phosphorus poisoning. Gastric lavage with potassium permanganate converts the phosphorus to relatively harmless oxides.^[5] Careful monitoring of liver and kidney function is required. Liver transplantation has been done in suitable candidates for acute hepatic failure.¹⁰ Studies have shown no clear benefit from N-acetyl cysteine, corticosteroids, or exchange transfusion.¹¹

Our patient was given N-acetyl cysteine on the day of admission but his liver function and INR

kept on deteriorating, a sharp increase being seen on 4th day, so from 5th day to 7th day he was given 3 cycles of plasmapheresis and by the second cycle of plasmapheresis i.e. on 6th day his laboratory investigations including INR started coming back to normal, and his general condition started improving. Plasmapheresis was given by replacing full plasma volume (calculated on the basis of body weight and hematocrit) with fresh frozen plasma.

A study by Varghese J et al¹², Matthew J et al¹³ and Angraje S et al¹⁴ also support therapeutic plasma exchange in management of yellow phosphorus poisoning with remarkable improvement in outcomes.

Conclusion

Yellow phosphorus poisoning is a big threat as suicide weapon because of its wide use in manufacture of multiple industrial products. Development of resistance of rodents to warfarin makes use of yellow phosphorus more prevalent. Though the ideal way to deal with this problem will be to discourage its use as an ingredient of rodenticide and to look for other alternatives. Clinicians should be aware of its toxicity and use of plasmapheresis in early stages should be encouraged in management of acute yellow phosphorus poisoning.

References

1. Brent J, Wallace KL, Burkhart KK. Phosphorus. In: Brent J, Wallace KL, Burkhart KK, Phillips SD, Donovan JW, editors. *Critical Care Toxicology – Diagnosis and Management of the Critically Poisoned Patient*. Philadelphia, PA: Elsevier Mosby; 2005. pp. 851–61. [Google Scholar]
2. Tenenbein M. Position statement: Whole bowel irrigation. American Academy of Clinical Toxicology; European Association of Poisons Centres and Clinical Toxicologists. *J Toxicol Clin Toxicol* 1997;35:753–62. [PubMed] [Google Scholar]
3. Mauskar A, Mehta K, Nagotkar L, Shanbag P. Acute hepatic failure due to yellow phosphorus ingestion. *Indian J Pharmacol* 2011;43:355-6. [PUBMED] [Full text]
4. Mishra AK, Devakiruba NS, Jasmine S, Sathyendra S, Zachariah A, Iyadurai R. Clinical spectrum of yellow phosphorous poisoning in a tertiary care centre in South India: A case series. *Trop Doct* 2016. pii: 0049475516668986
5. Fernandez OU, Canizares LL. Acute hepatotoxicity from ingestion of yellow phosphorus-containing fireworks. *J Clin Gastroenterol* 1995;21:139-42.
6. Nalabothu M, Monigari N, Acharya R. Clinical profile and outcomes of rodenticide poisoning in tertiary care hospital. *Int J Sci Res Publ* 2015; 5:1-12. Available from: <http://www.ijsrp.org/research-paper-0815/ijsrp-p4442.pdf>. [Last accessed on 2016 Jan 05]. †
7. Karanth S, Nayyar V. Rodenticide-induced hepatotoxicity. *J Assoc Physicians India* 2003;51:816-7. [PUBMED]
8. Ravikanth R, Sandeep S, Phillip B. Acute Yellow Phosphorus Poisoning Causing Fulminant Hepatic Failure with Parenchymal Hemorrhages and Contained Duodenal Perforation *Indian J Crit Care Med*. 2017 Apr; 21(4): 238–242.
9. Talley RC, Linhart JW, Trevino AJ, Moore L, Beller BM. Acute elemental phosphorus poisoning in man: Cardiovascular toxicity. *Am Heart J*. 1972;84:139–40. [PubMed] [Google Scholar]
10. Santos O, Restrepo JC, Velasquez L, Castano J, Correa G, Sepulveda E, et al. Acute liver failure due to white phosphorus ingestion. *Ann Hepatol*. 2009;8:162–5. [PubMed] [Google Scholar]
11. Marin GA, Montoya CA, Sierra JL, Senior JR. Evaluation of corticosteroid and

exchange-transfusion treatment of acute yellow-phosphorus intoxication. *N Engl J Med*. 1971;284:125–8. [PubMed] [Google Scholar]

12. Varghese J, Joshi V, Bollipalli MK, Malleeswaran S, Patcha R, Nair H, Vij V, Sachan D, Subramanian P, Jain M, Venkataraman J. Role of therapeutic plasma exchange in acute liver failure due to yellow phosphorus poisoning. *Indian J Gastroenterol*. 2020 Dec;39(6):544-549. doi: 10.1007/s12664-020-01095-y. Epub 2021 Jan 6. PMID: 33409946; PMCID: PMC7787244.
13. Mathew J, Gnanaraj J, Basavarajegowda A, Venkateswaran R. Plasmapheresis in lethal yellow phosphorus poisoning: a scope for recovery. *BMJ Case Rep*. 2021 Apr 21;14(4):e239676. doi: 10.1136/bcr-2020-239676. PMID: 33883110; PMCID: PMC8061805.
14. [https://www.kireports.org/article/S2468-0249\(20\)30532-5/pdf](https://www.kireports.org/article/S2468-0249(20)30532-5/pdf) cited on 18th nov 2021.