



A Comparative Study on Efficacy of Prolene Seton and Silk Seton in Management of Fistula in Ano in a Tertiary Care Centre

Authors

**Dr VT Arasu M.S.¹, Dr Japhereena M.S.², Dr G Ganesh Kumar M.S.³,
Dr M. Ganesan M.S.⁴**

¹Professor of General Surgery, Chengalpattu Medical College

²Postgraduate, Department of General Surgery, Chengalpattu medical college

³Assistant Professor, Department of General Surgery, Chengalpattu Medical College

⁴Assistant Professor, Department Of General Surgery

Abstract

Fistula in ano is a chronic abnormal communication usually lined to some degree by granulation tissue. It extends from the anorectal lumen to the skin of the perineum. Fistula in ano is one of the common surgical problems encountered these days with a prevalence of 8.6 to 10/100,000 of the population per year and male: female ratio of 1.8:1^[1]. Perianal fistulas most commonly occur following episodes of anorectal sepsis.

Introduction

They are classified based on the relation of the fistulas tract to the sphincter into four distinct groups by Park namely; intersphincteric, transsphincteric, suprasphincteric and extrasphincteric^[2]. The main objective in the treatment of this condition is to drain the necrotic tissue, eliminate the fistulous tract and to preserve the sphincter integrity^[3]. There are numerous novel modalities now available for the management of anal fistulas. Our study focuses on the use of cutting seton.

A seton is a type of foreign material inserted through the fistulous tract and used in the management of high anal fistulas. Hippocrates first detailed the use of this in the treatment of anal fistulas^[4]. With newer advancements, various materials are now being tried in the management of anal fistulas by the Seton technique.

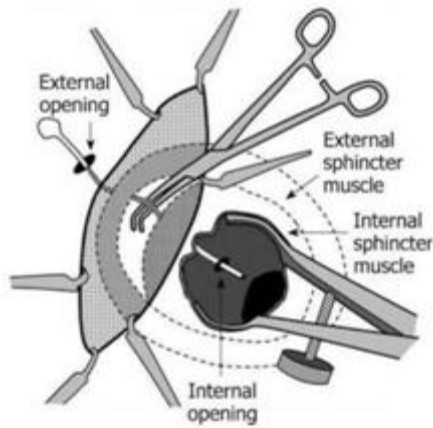
Aims and Objective

The objective of this study is to comparing the use of silk vs. prolene materials in the management of anal fistulas by the cutting Seton technique. The parameters taken into consideration in evaluating the outcome of the study are: rate of wound healing, occurrence of infection, mean hospital stay, Seton failure, sphincter incontinence and recurrence.

Management of Fistula in Ano

The main principles involved in the management of fistula in ano includes

- Drainage of infection or perianal sepsis
- Eradication of the fistulous tract with the preservation of the sphincter continence
- Closure of the internal opening



The management of various fistulae in ano depends on their types in relation to the external anal sphincter. Low fistulae can be treated easily by the conventional laying- open technique.

High anal fistulae on the other hand are of very low incidence and are difficult to manage with the conventional laying open technique as the high anal fistulae involve the external sphincter complex to a greater extent and thereby posing the risk of sphincter incontinence while laying open the entire fistulous tract. Therefore the mainstay of treatment in high anal fistulae are the use of sphincter sparing surgical techniques^[11].

Ligation of Intersphincteric Fistulous Tract Seton Treatment

Mechanism of action of Seton includes

- It helps in draining and pus and controlling the ongoing sepsis before the management with any other definitive treatment
- It helps as a marker for the sphincter sparing surgeries like fistula plug, fibrin glue, ligation of the intersphincteric fistula tract. It also aids in the fibrosis of the fistulous tract.
- It promotes the slow transection of the external anal sphincter muscle by the process of progressive migration thereby resulting in the pressure necrosis with minimal separation of the cut ends.

Types of Seton

- Medicated seton
- Drainage seton
- Cutting seton

Medicated Seton

The use of medicated Seton was first developed in the ancient times when fistula in ano was management with the help of seton made from a caustic chemical from plant extract known as “kshara- sutra”.

Various studies comparing the use of these setons with conventional laying open technique of fistulotomy concluded that chemical setons were more painful when compared to fistulotomy and there was a significant difference in the duration of wound healing, complications or functional outcomes.

Drainage Seton

Loose seton is tied long the fistulous tract from the external opening and kept in place to drain the ongoing perianal abscess. It is used in staged procedure to eradicate ongoing infection before proceeding with the definitive treatment.

Cutting seton

In this technique, seton is placed within the fistulous tract and tied around the external anal sphincter. Intermittent tension is applied on a regular basis causing the gradual cutting sphincter along with simultaneous fibrosis happening above the seton thereby reducing the rate of occurrence of sphincter Incontinence. Often cutting seton is used in staged procedure following conventional fistulotomy^[18].

Tyler KM et al in their study “successful sphincter sparing surgery for all anal fistulas” emphasised the need for sphincter sparing surgical intervention by staged procedures for the management of complex fistula in ano to minimize the occurrence of faecal incontinence and successful treatment of the fistulas^[19].

Kamrava at al in their study “a decade of selective use of adjustable cutting seton in combination with fistulotomy for anal fistulas” inferred that cutting seton in combination with partial fistulotomy is essential tool in treating fistulas that involve the sphincter complex. He also stated the usage of heavy silk ligatures with patient controlled tension in cutting seton technique^[20].

Mentes BB et al in their study on “elastic one stage cutting seton in te treatment of high anal fistulas – preliminary results” showed that the use of elastic seton contributed to the slow and stable cutting of the sphincter while maintaining the sphincter continence. He also suggested that elastic seton reduced the need for cumbersome postoperative adjustments thereby increasing the patient compliance in the management of anal fistulas with setons^[21].

P. J. Shouler et al in his study “Fistula-in-ano is usually simple to manage surgically” suggested that surgery is the mainstay in the management of fistula in ano^[22]. Sygut A et al in thier study “late results of treatment of anal fistulas” studied outcomes of various surgical modalities used for the management of fistulas under the following parameters namely; time for wound healing, duration of hospital stay, recurrence rate and incidence of sphincter dysfunction. He concluded that the late outcomes of these procedures largely depends on the type of primary fistulas^[23]. Theerapol A et all in their study “routine use of seton for the treatment of anal fistulae” suggested that usage of seton as a routine procedure is safe, cheap and effective regardless of its type. He also suggested that seton has a high patient satisfaction as it does not leave an open wound^[24].

Methods and Methodology

This is a randomised, comparative, prospective observational study of 84 cases of fistula in ano presenting in the surgical opd of chengalpattu medical college hospital, chengalpattu, tamil . The 84 patients were categorized into two groups of 42 each. One set of patients were managed with silk seton and the other group was managed with prolene seton.

Inclusion Criteria

- Men and women between 20- 65 years of age.
- Patients giving informed consent for the procedure and to participate in the study.
- Patients presenting with history of recurrent pus discharge in the perianal

region.

- Clinically evident external opening.
- Patients with trans-sphincteric anal fistulae.

Exclusion Criteria

- Denial of consent.
- Age less than 20 years.
- Patients with signs of active inflammation.
- Patients with simple anal fistulae.
- Patients who are unfit for surgery.
- Patients on medications such as immunotherapy and long term steroids.
- Patients with other anorectal diseases, carcinoma rectum, inflammatory bowel disease and crohn’s disease.

Clinical History

- Perianal discharge
- Pain
- Swelling
- Bleeding
- Skin excoriation
- External opening
- H/o perianal previous abscess

The following history are suggestive of associated complex fistula in ano

- Inflammatory bowel disease
- Diverticulitis
- Radiation exposure to prostate or rectal cancer
- Tuberculosis
- Steroid therapy
- Immunodeficiency status

Digital rectal examination

- Look for external opening
- Palpate the fibrous tract or cord beneath the skin
- Look for any induration
- Sphincter tone should be checked
- Look for internal opening

Clinical history was collected and examination was done on all opd patients presenting with symptoms and signs of fistula in ano including per rectal and proctoscopic examination. All routine blood investigations were sent and analysed for fitness for surgery under spinal anaesthesia.

Preoperative evaluation of the fistulous tract was performed using MRI fistulogram in all patients with perianal fistulas.

The objective of preoperative evaluation of the fistulous tract are

- To determine the relationship of the fistulous tract with the sphincter complex
- To identify any secondary fistulous tracts and abscess cavities. failure to detect and eradicate these will precipitate therapeutic failure and relapse.

After obtaining the necessary consents the patients both the were then operated with cutting setons of silk and prolene respectively. Silk and prolene seton are inserted in their respective groups of patients using the following technique. The fistulous tract was gently probed with a small blunt tipped malleable probe. The portion of the tract outside the sphincter was laid open and curetted as were any lateral secondary tract.

The silk/ prolene material was tied to the tip of the probe and inserted through the remaining tract in a double stranded fashion and delivery out around the striated muscle as seton. The seton was then tied onto the sphincter with multiple knots. Post operatively, sitz bath was advised after each bowel movements. The patients were educated to pull the seton thread with gentle pressure after each sitz bath till the seton dropped. The patients are then followed up monthly for the first 6 months and reviewed at the end of 1 year for long term follow up. The outcome of study was analysed using the following parameters – mean duration of hospital stay,

- mean duration for wound healing,
- occurrence of wound infection,
- seton failure due to premature seton dislodgement or slippage,
- occurrence of incontinence and recurrence of fistulas on long term followup.

The data was analysed using spss version 20. Continuous variables were analysed as proportions and percentages.

Image 1: Pre-Op Picture of the External Opening in a Patient with Fistula in Ano

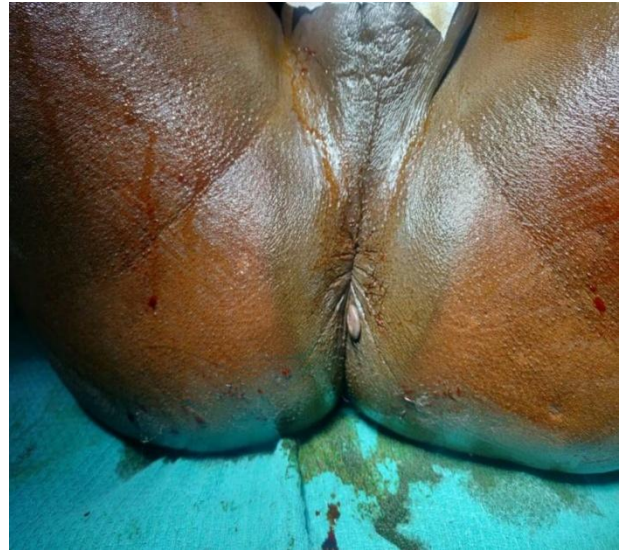

Image 2: Technique of Probing Using Malleable Metal Probe

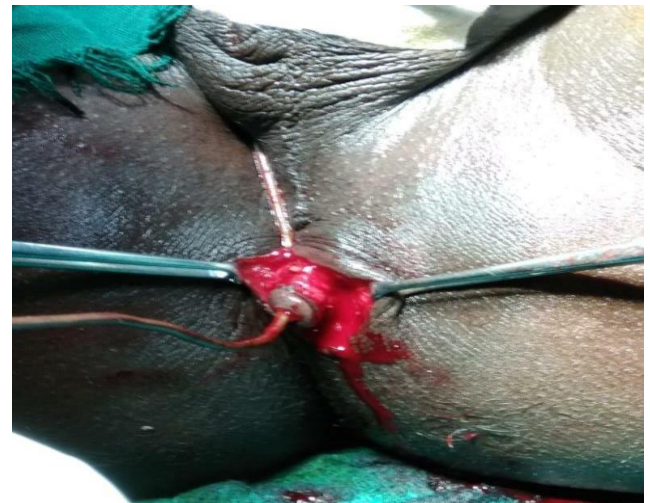


Image 3: Placement of Prolene Seton

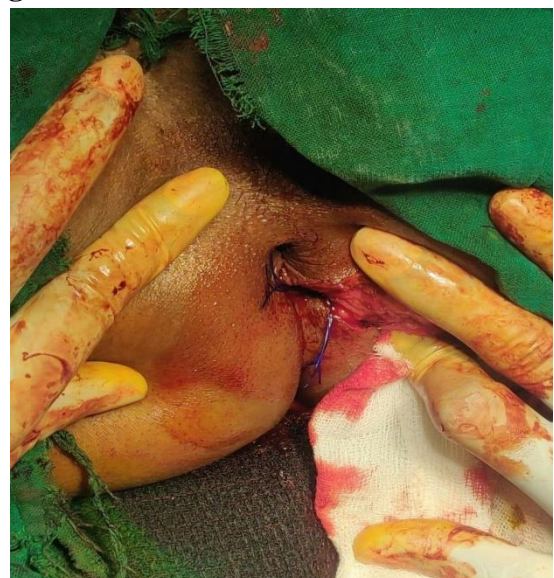

Image 4: Placement of Silk Seton

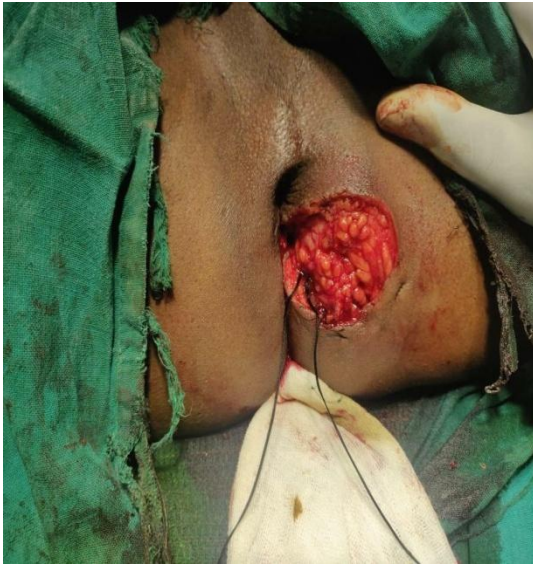

Image -7: Stages of Wound Healing with Seton

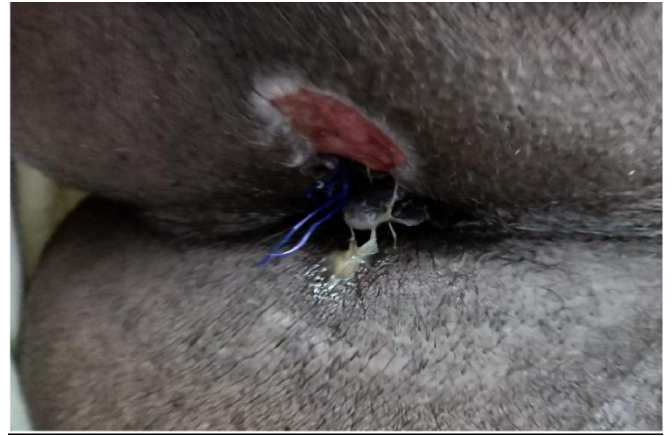

Image 5: Fistula with Multiple External Openings

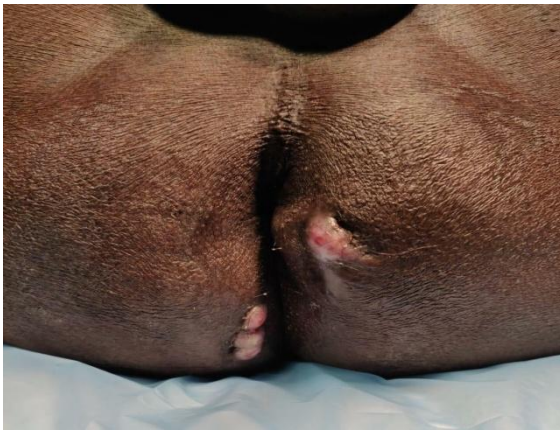

Image 8: Stages of Wound Healing Post Seton in Patients with Fistula in Ano

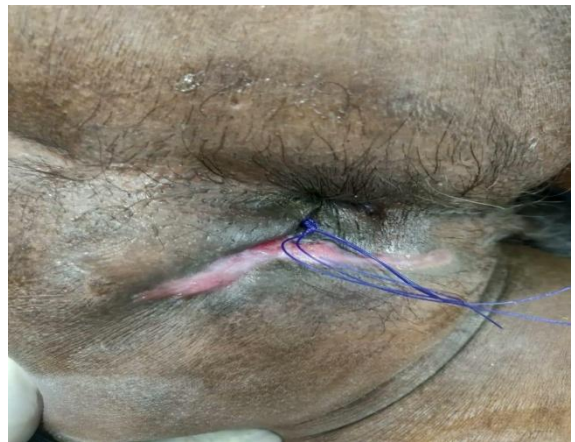

Image 6: Seton Placement in Fistula with Multiple External Openings

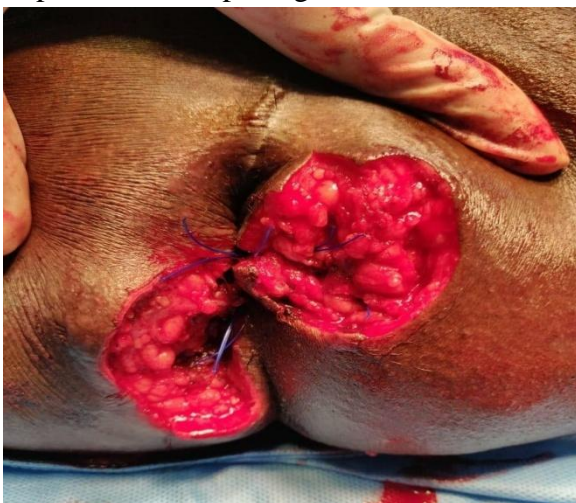
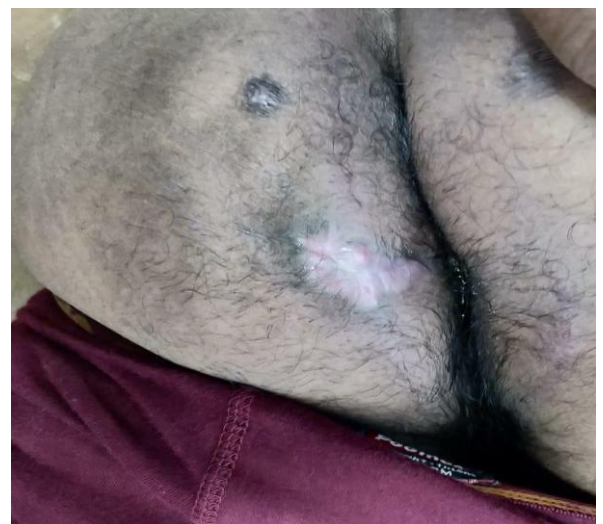
Image 9: Stages of Wound Healing Post Seton in Patients with Fistula in Ano



Observation and Results

The outcome of silk and prolene materials as seton in the management of fistula in ano were analysed by comparing the following parameters namely

- Mean hospital stay,
- Occurrence of postoperative infections,
- Mean duration of wound healing,
- Seton failure,
- Occurrence of sphincter incontinence
- Rate of recurrence.

Data Analysis

This study has undergone descriptive as inferential statistical analysis. All continuously measured results are presented as mean ± SD (min-max) and categorically measured results are represented in number (%). Consideration of significance is at 5% level of significance.

Mean Hospital Stay

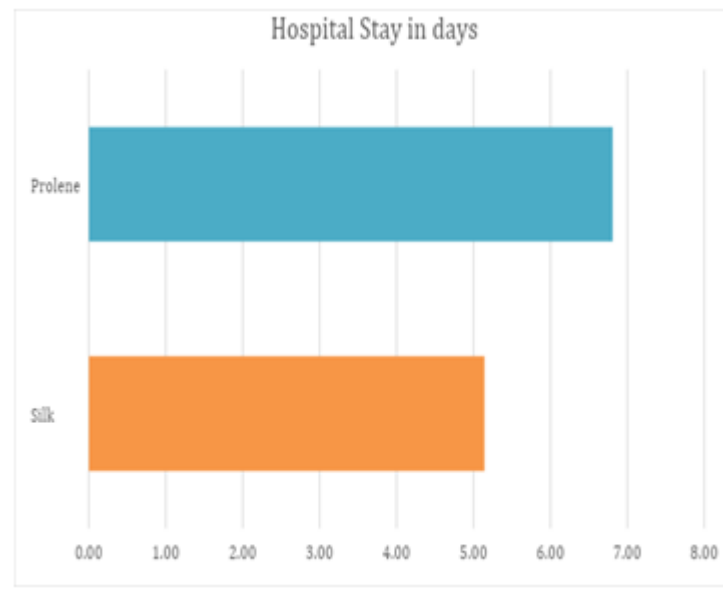
In this study it was noted that the mean hospital stay among those operated with silk seton was 15.14 ± 0.52 days while those treated with prolene seton was 6.80± 1.79 days. Our analysis showed a statistically significant duration of prolonged hospital stay among those treated with prolene seton.

This need for prolonged hospital stay was noted among those on prolene seton as they complaints of post operative pain at the operated site. Hence requiring adequate analgesics and reassurance until they were acclimated to the seton thread.

Table 1: Mean Duration of Hospital Stay in Days

Group	N	Mean	Std. Deviation	Std. Error Mean	T value	P value
Silk	42	5.1429	.52132	.08044	5.771**	p<0.001
Prolene	42	6.8095	1.79753	.27737		

Graph 1: Comparison of Mean Duration of Hospital Stay among those with Silk and Prolene Seton Wound Infection



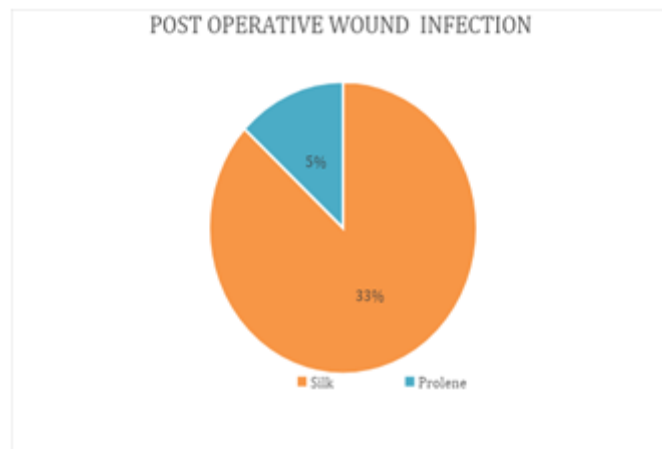
Among the 42 patients with silk seton, it was noted that 14(33.3%) developed post operative wound infections while only 2 (4.8%) of the 42 with prolene seton developed postoperative

wound infection. Showing that silk has a statistically significant tendency to cause wound infections when compared to prolene seton.

Table 2 : Occurrence of Post Operative Wound Infection

	group		Total
	Silk	Prolene	
Count No	28	40	68
% within group INF	66.7%	95.2%	81.0%
Count Yes	14	2	16
% within group Total	33.3%	4.8%	19.0%
Count Total	42	42	84
% within group	100.0%	100.0%	100.0%

Graph 2: Comparison of Incidence of Postoperative Wound Infection among the Silk and Prolene Seton Groups



Seton Failure

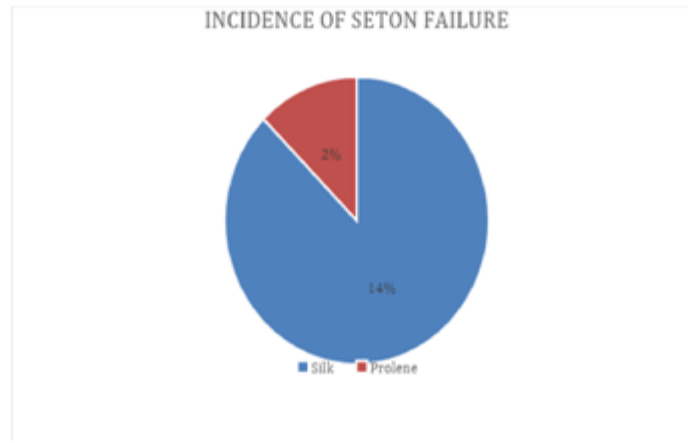Seton failure was analysed among the two groups on the basis of slippage of material or premature dislodgement. It was noted that 6 out of the 42 patients with silk seton showed seton failure

mainly due to cumbersome and imprecise tightening of seton by the patients. Among those with prolene seton 1 out of the 42 had seton failure due to slippage of knot.

Table 3 : Incidence of Seton Failure

			Group		Total
			Silk	Prolene	
SF	No	Count % within group	36 85.7%	41 97.6%	77 91.7%
	Yes	Count % within group	6 14.3%	1 2.4%	7 8.3%
Total		Count	42	42	84
		% within group	100.0%	100.0%	100.0%

Graph 3: Comparison of Incidence of Seton Failure among Those with Silk and Prolene Seton



Wound Healing

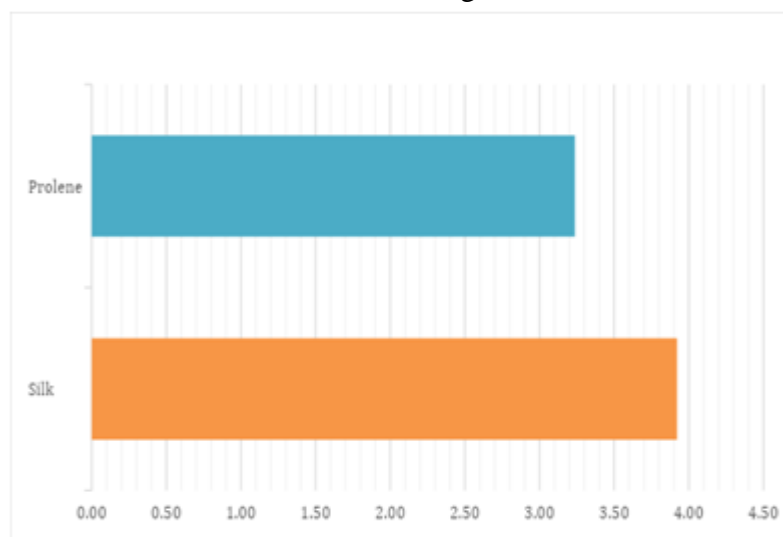
The mean duration of wound healing was noted to be 3.92 ±1.26 months among those with silk seton and those with prolene seton had mean duration of wound healing of 3.23± 0.58 months. Our analysis

showed that those with silk seton took a statistically significant duration more for complete wound healing when compared to those with prolene seton.

Table 4: Mean Duration of Wound Healing in Months

Group	N	Mean	Std. Deviation	Std. Error Mean	T value	P value
Silk	42	3.9211	1.26024	.20444	3.031**	p<0.001
Prolene	42	3.2368	.58974	.09567		

Graph 4: Comparison of Mean Duration of Wound Healing Between Silk and Prolene Seton



Recurrence and Incontinence

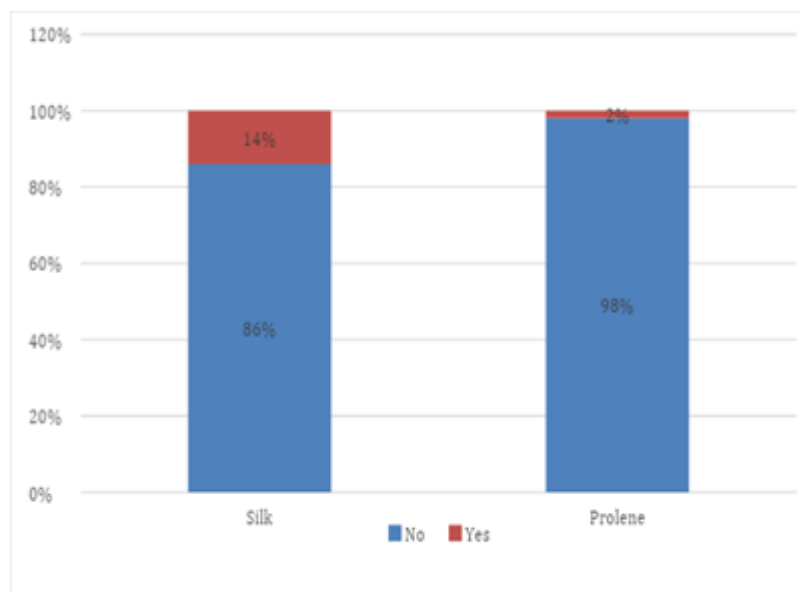
On long term following of patients, recurrence was noted more among those treated with silk seton. 6 of 42 patients (14.3%) with silk seton developed recurrence where recurrence of fistula was noted in only 1(2.4%) patient with prolene seton. This high recurrence with silk could be

attributed to high increased rate of post operative wound infections acting as nidus for further cryptoglandular abscess formation thereby leading to fistula formation. Sphincter incontinence to neither flatus nor stools were reported among any of the patients within the study group during their period of followup.

Table 5: Incidence of Recurrence of Fistula in Ano

		Count	group		Total
			Silk	Prolene	
REC	No	36	41	77	
		85.7%	97.6%	91.7%	
	Yes	6	1	7	
		14.3%	2.4%	8.3%	
Total		42	42	84	
		% within group	100.0%	100.0%	100.0%

Graph 5: Comparison of the Occurrence of Recurrence following those Managed With Silk and Prolene Seton



Discussion

Fistula in ano is one of the common surgical conditions faced since ancient times. Age old seton is still used as a successful treatment for the management of transsphincteric fistula in ano. The materials most commonly used for seton are non absorbable sutures like prolene and SILK. The seton is left in place and tightened intermittently to allow gradual division of sphincter^[26]. These strings like materials work by causing inflammation and fibrosis of the fistulous tract by allowing slow transection of the external sphincter muscle as a result of pressure necrosis^[27]. Silk is a braided non-absorbable natural suture used as a mainstay material was many years. It has adequate knot security but the least tensile strength of all

non absorbable sutures^[28]. It poses the disadvantage of high tissue reactivity and poor microbe- resistance property^[29]. Silk sutures when used for tissue ligations were shown to have poor wound healing and severe tissue reaction. This was attributed to the property of silk causing a high affinity to the adherence of bacteria to silk sutures^[30]. The delayed wound healing was justified by the slow pace in the formation of fibroblasts and new capillaries in the vicinity of silk sutures^[31]. Prolene (polypropylene) was the first synthetic non- absorbable suture material used. Prolene has the property of high tensile strength and lesser tissue reactivity. The major disadvantages of prolene include - high memory, poor knot security and lack of elasticity^[32].

Conclusion

The use of seton is an effective means of management of transphincteric anal fistulae with preservation of sphincter continence and minimal recurrence. They are cheap, durable and easily accessible means of TREATMENT. Prolene seton though seems to have a higher incidence of postoperative pain and thereby increasing the mean hospital stay and need for adequate analgesics, it has proven to have better results in terms of early wound healing and lesser incidence of wound infections and seton failure in comparison to silk seton.

References

1. Abraham Jebakumar et al “A comprehensive study of fistula in ano” International Archives of Integrated Medicine 2016, 3(8):66-72.
2. Andreas Ommer et al “cryptoglandular anal fistulas” Dtsch Arztebl International 2011;108(42):707-713.
3. Ramachandra M. et al “a comprehensive study in the management of fistula in ano using various modalities. International Surgery Journal 2018june 5(6): 2223-2227.
4. Gokulakrishnan Subhas “seton in the treatment of Anal Fistulas: review of variations in materials and techniques” Digestive Surgery 2012; 29:292-300.
5. Textbook of Gray’s anatomy - anatomical basis of clinical practice 2120- 2125.
6. Carol Ann Vasilensky et al, “Benign Anorectal abscess and fistula. The ASCRS textbook of colon and rectal surgeries pages 192-214.
7. Murtaza Akhtar et al, “Fistula in Ano -an overview, JIMSA january- march 2012 volume 25 No.1
8. John Morris et al, “MR imaging classification of perianal fistulas and its implication for patient management, Radiographics, 2000 No.3, vol. 20 pg 623-635.
9. Pradeep Shashjirao Sindhe et al “ Substantiating accuracy of Goodsall’s rule in fistula in ano (Bhagandar) with anatomical consideration”. Indian Journal of Health Sciences and Biomedical Research KLEU, 2018; 11:151-154.
10. Juan L Poggio et al, “fistula in ano treatment and management : Approach consideration, Fistulotomy, seton placement. <http://emedicine.emedscape.com/article/190234-treatment>.
11. Ayaz Ahmad Memon, “treatment of complex fistula in ano with cable tie seton : a prospective case series”. International Scholarly Research Network, Vol 2011 Article ID 636952 pages 5. doi10.5402/2011/636952.
12. Resit Inceoglu “Fistulotomy and drainage of deep postanal space abscess in the treatment of posterior horseshoe fistula. BMC Surgery Article No: 10(2003)
13. Elsebai et al “fistulectomy versus fistulotomy in the management of simple perianal fistula” Menoufia Medical Journal 2016, vol 29 issue 3, pages 564-569.
14. Ladan Ghahramani et al., “Late results of endorectal flap in the management of high type perianal fistula”. Middle East Journal of Digestive Disease. Vol. 4 No.3 july 2012, 163-167.
15. Gokturk Maraclan et al “Long term results in the treatment of fistula in ano with fibrin glue : a prospective study”. Journal of the Korean Surgical Society, 2011 september 81(3), 169-175.
16. Ferdinand Kocherling et al “treatment of fistula in ano with fistula plug - a review under special consideration of technique”, Frontiers in Surgery 2015 2:55
17. Chowdri NA et al “ligation of the intersphincteric fistula tract technique for fistula in ano”. Clinicals in Surgery 2017 2:1561
18. Mohammad Ali Sutar et al., “Role of seton

- in the management of fistula in ano” International Journal of Contemporary Medical Research 2016;3(6) 1710-1713.
19. Tyler KM. “Successful sphincter sparing surgery for all anal fistula” Journal of Disease of Colon and Rectum. 2007 october 50(10), 1535-1539.
 20. Kamrava A et al. “A decade of selective use of adjustable cutting seton combined with fistulotomy for anal fistula”. The Journal of Americal Surgeon. 2011 october 77(10); 1377-1381.
 21. BB Menten et al “Elastic one- stage cutting seton for the treatment of high anal fistulas - priliminary results”. Tech Coloproctol (2006) 8:159-162.
 22. PJ Shouler et al “Fistula in ano is usually simple to manage surgically”. International Journal of Colorectal Disease (1986) 1:113-115.
 23. A Sygut et al “Late results of treatmebt of anal fistulas”. Journal of Colorectal Disease. Vol 9, Issue 2, February 2007 151-158.
 24. Therapol A et al, “Routine use of seton for the traetment of anal fistulas”. Singapore Medical Journal 2002 June; 43(6): 305-307.
 25. Christopher J Skilbeck et al, “Sutures , ligatures ad knots”Surgery (oxford) ISSN, 0263-9319. Vol 29, Issue 2, 63-66
 26. Ahmad Izadpanab et al, “Pulling seton: combination of mechanisms”. Advanced Biomedical Research, 2016, 5:68.
 27. Mohamed Mogahed et al, “Cutting seton as surgical management of high anal fistula”. Al-AzharAssiut Medical Journal Vol13 No.2. April 2015 10-14.
 28. Neil A et al, “Suture material- 1980 : Properties, uses and abuses”. International Society of Tropical Dermatology. Vol21 September 1982, No.7, 373-378.
 29. G. Thilagavathi et al, “Silk as suture material”. Advances in Silk Sciences and Technology. 2015; 219-232.
 30. Firat Selvi et al, “Effects of different suture material on tissue healing”. Journal of Istanbul University: Dent 2106; 50(1): 35-42.
 31. Fawad JAved et al, “Tissue reaction to various suture materials used in oral surgical interventions”. International Scholarly Research Network Dentistry. Vol 2012, Article Id 762095-6 pages
 32. Mohan H. Kunder et al, “Suture and Suturing techniques in skin closure”. Indian Journal of Dermatol Venereol Leprol, July- August 2009;75:425-434.