



## Clear Cell Renal Cell Carcinoma with Sarcomatoid Differentiation: A Case Report

Authors

**Dr Supriya Verma<sup>1</sup>, Dr Sarita Asotra<sup>2\*</sup>, Dr V Anish Chandran<sup>3</sup>**

<sup>1</sup>Senior Resident, Department of Pathology, Indira Gandhi Medical College, Shimla

<sup>2</sup>Associate Professor, Department of Pathology, Indira Gandhi Medical College, Shimla

<sup>3</sup>Junior Resident, Department of Pathology, Indira Gandhi Medical College, Shimla

\*Corresponding Author

**Dr Sarita Asotra**

Associate Professor, Department of Pathology, Indira Gandhi Medical College, Shimla,  
Himachal Pradesh- 171001, India

### Abstract

Renal cell carcinoma (RCC) with sarcomatoid differentiation belongs to most aggressive clinicopathologic type of RCC. It is associated with poor prognosis and therapeutic outcome. We report a case of clear cell renal cell carcinoma with sarcomatoid differentiation involving left kidney in a 51 year old female. Immunohistochemistry was performed for exact characterization. The importance of this case report is identification and reporting of sarcomatoid component in renal cell carcinoma as it confers more propensity of metastasis and hence less chances of survival.

**Keywords:** renal cell carcinoma (RCC), sarcomatoid differentiation, poor prognosis.

### Introduction

RCC with sarcomatoid differentiation is an aggressive form of RCC characterized by high propensity of metastasis and poor outcome with limited therapeutic options<sup>[1]</sup>. We report a case of clear cell renal cell carcinoma with sarcomatoid differentiation in a 51 year old female.

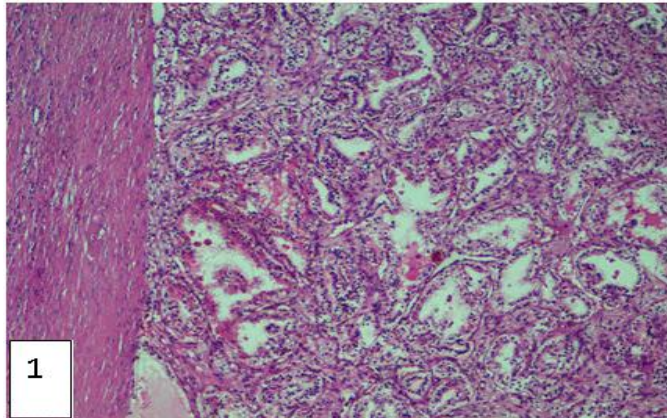
### Case Report

A 51 years old female presented with complaints of pain in left lumbar region, hematuria and burning micturition. Patient was non diabetic and non hypertensive. USG abdomen revealed enlarged kidney measuring 12.7×5.9 cm with large heteroechoic mass involving mid and lower pole of left kidney measuring 7×6×5.7 cm partially extending into renal sinus and reaching upto renal hilus. Pelvicalyceal system was not dilated. Urine cytology revealed albumin, pus cells and RBCs. Serum creatinine was increased

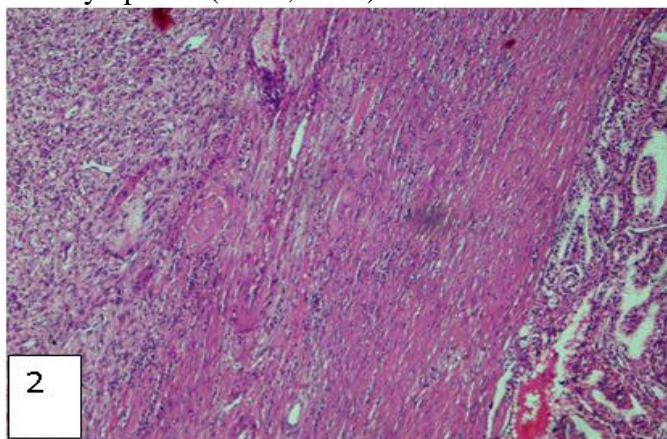
and uric acid was within normal limits. Patient underwent left radical nephrectomy. The specimen was sent for histopathological examination. Immunohistochemistry was also performed for confirmation and exact characterization.

Sections from tumour showed round to polygonal tumour cells with round vesicular nuclei, conspicuous to prominent nucleoli, occasional mitotic activity, moderate to abundant clear to pale eosinophilic cytoplasm arranged in acini, nests, pseudopapillae [Figure 1] and separated by fibro vascular septa [Figure 2]. In addition, sarcomatoid areas were seen comprising less than 50% of tumour [Figure 3] and showing atypical spindle cells with mild pleomorphism in poorly formed fascicles arranged around vessels [Figure 4]. Mitotic index was 5 per 10 HPF (high power field). Focal areas showed hemorrhage, necrosis, lymphocytic infiltrate, mast cells, marked hyalinization and dystrophic calcification. Renal

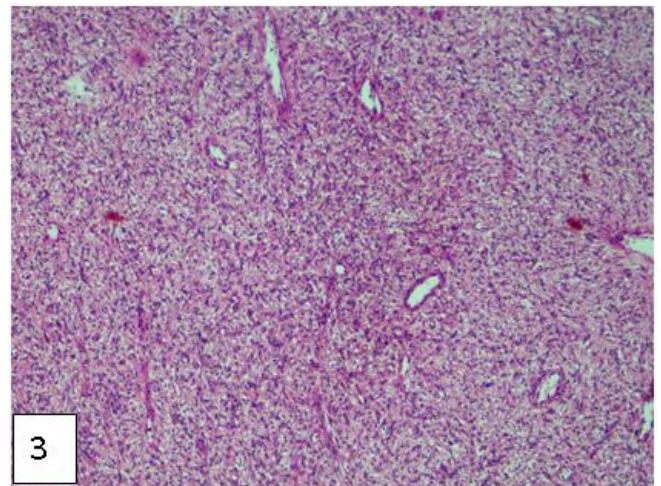
capsule, perinephric fat, hilar vessels and ureter were free from tumour invasion. Immunohistochemistry showed positivity for vimentin in sarcomatous component [Figure 5A & 5B] and CD10 in epithelial component [Figure 6A & 6B].



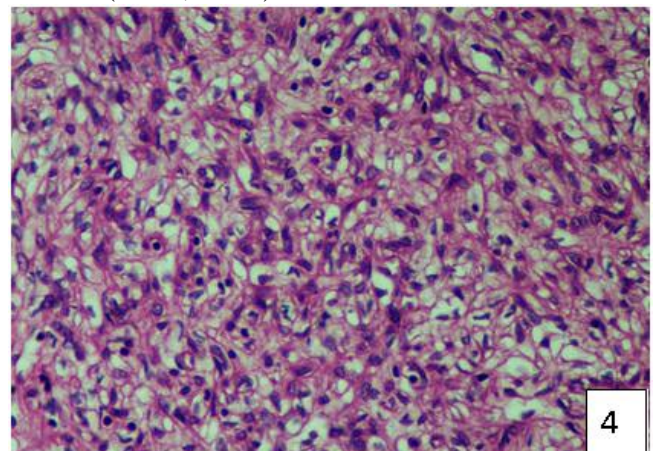
**Figure 1:** Photomicrograph showing tumor epithelial cells arranged in acini and nests with clear cytoplasm (H&E, x400)



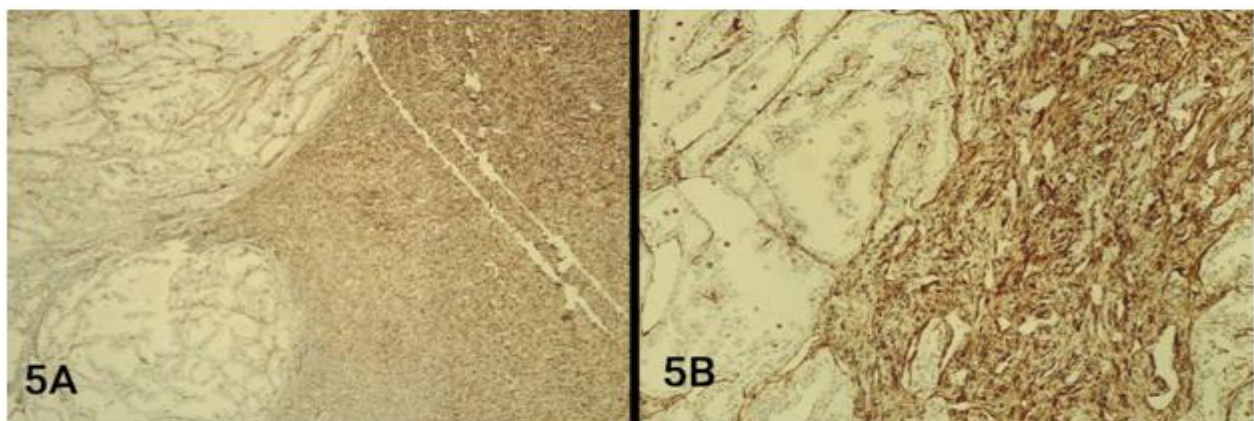
**Figure 2:** Photomicrograph showing tumour epithelial cells (right) separated by fibrovascular septa and a focus showing sarcomatoid component (left) (H&E, x100)



**Figure 3:** Photomicrograph showing sarcomatoid component occupying less than 50% of the tumour (H&E, x100)

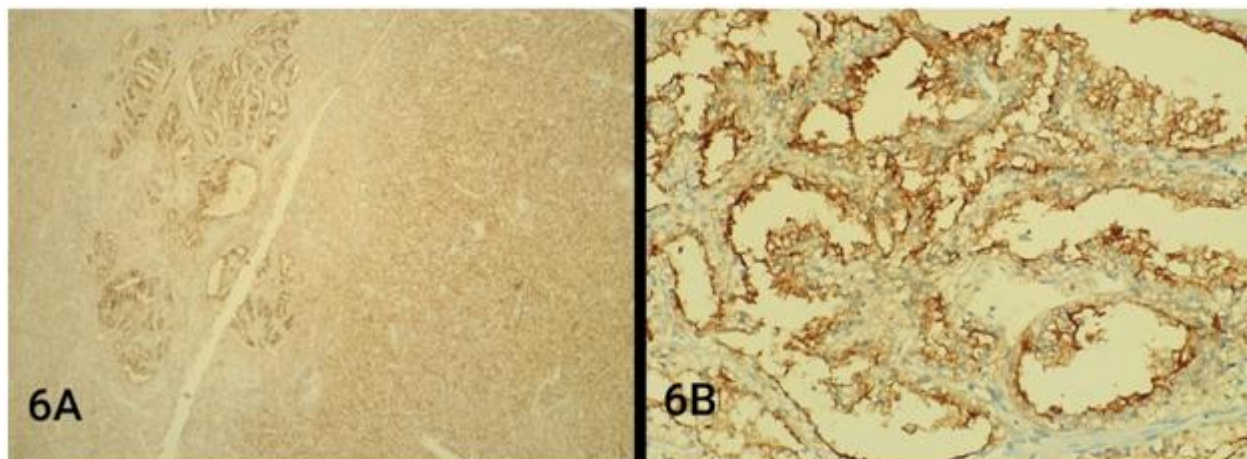


**Figure 4:** Photomicrograph showing sarcomatoid component with atypical spindle cells having mild pleomorphism (H&E, x400)



**Figure 5A & 5B:** Immunohistochemistry: Vimentin showing cytoplasmic positivity in sarcomatous component





**Figure 6A & 6B:** Immunohistochemistry: CD 10 showing membrane positivity in neoplastic epithelial cells

### Discussion

RCC with sarcomatoid differentiation belong to the most aggressive clinicopathologic phenotypes of RCC. It is characterized by high chances of metastasis and limited therapeutic modalities, as it is resistant to already established systemic targeted therapy. Most studies report a poor median survival of 5 to 12 months<sup>[1]</sup>.

Sarcomatoid differentiation is seen in 5-8% of clear cell RCC, 8-9% of chromophobe RCC and 2-3% of papillary RCC<sup>[2,3]</sup>. The term "sarcomatoid RCC" is not a distinct morphogenetic subtype of RCC as it occurs with all histologic subtypes. It originates from epithelial-mesenchymal transition and thus shows both epithelial (carcinoma) and mesenchymal (sarcomatoid) components on morphological and immunohistochemical level<sup>[4]</sup>. This feature differentiates it from primary sarcoma of kidney<sup>[5]</sup>.

The presence of even a small component of sarcomatoid differentiation was shown to independently predict poor survival and outcome compared to RCC without sarcomatoid features. Thus, it is very important to describe this differentiation in surgical pathology report<sup>[6]</sup>. Dall'Oglio MF et al compared outcome of individuals with pure sarcomatoid tumour with that of sarcomatoid differentiation in clear cell carcinoma. Although sarcomatoid RCC is commonly associated with high grade tumours, it can also be seen with low grade tumours<sup>[7]</sup>. However, greater than 50% of this component is

associated with worse survival which is contested by Bertoni et al. He also states that patients with low Fuhrman nuclear grade and less than 5% of sarcomatoid differentiation have much better chances of cure<sup>[8]</sup>. The frequency of sarcomatoid tumours with high Fuhrman's nuclear grade is 64-100%<sup>[3]</sup>.

In early half of 20<sup>th</sup> century, renal tumors with sarcoma like features were characterized by pathologists as "renal sarcomas". Later many pathologists began to recognize classic RCC characteristics in many of these tumours. It led to a change in nomenclature of renal sarcomas to a different term "carcinosarcoma" of kidney. Eventually, the term "sarcomatoid RCC" was established and was considered a separate histologic type because of its highly aggressive nature. However, a separate subtype for sarcomatoid carcinoma was challenged by pathologists with recognition of sarcomatoid changes in association with almost every histologic type of renal tumour<sup>[9]</sup>.

Histologic characteristics of sarcomatoid RCC show features similar to sarcomas with spindle like cells, high cellularity and cellular atypia. Regions of sarcomatoid differentiation do not have noticeable epithelial components. Common histologic patterns can resemble fibrosarcoma or malignant fibrous histiocytoma, osteoid or chondroid differentiation. Additional poor prognostic factors such as necrosis and microvascular invasion are present in 90% and

30% cases respectively<sup>[6]</sup>. Majority of tumours have a variable carcinoma component. If absent, the pathologist should consider cutting additional tumour blocks for a more thorough assessment.

Among epithelial component, clear cell RCC is most commonly associated with sarcomatoid differentiation (greater than 80% cases). Undifferentiated RCC accounts for 2-10 % of sarcomatoid RCC<sup>[10]</sup>. However, some studies have shown that chromophobe RCC has highest association with sarcomatoid features<sup>[11]</sup>.

It is important to differentiate between classic sarcoma and sarcomatoid RCC. Primary renal sarcomas are extremely rare in adults accounting for less than 1% of renal malignancies and most of them are leiomyosarcoma which contain smooth muscle components that are rarely seen in sarcomatoid RCC<sup>[12]</sup>. In addition, primary renal sarcomas should not contain any classic areas of RCC<sup>[6]</sup>. Other mimickers of sarcomatoid RCC are sarcomatoid urothelial tumours. They may be distinguished by presence of flat in situ areas and / or squamous differentiation.

For confirmation of diagnosis of sarcomatoid RCC, additional tests like electron microscopy and immunohistochemistry (IHC) may be performed. Electron microscopy show epithelial components (such as desmosomes or basal lamina) which may not be observed by classic light microscopy<sup>[13]</sup>. IHC for common epithelial and mesenchymal markers may distinguish sarcomatoid RCC from sarcoma. A review by Delong and colleagues demonstrated that sarcomatoid areas express cytokeratin AE1/AE3 and vimentin in 97% and 56% of cases respectively<sup>[14]</sup>. Classic markers of mesenchymal tissue and sarcomas, eg-desmin and actin are infrequently expressed in sarcomatoid RCC.

Kanamaru and colleagues demonstrated that sarcomatoid component had a higher Ki-67 expression level and proliferative activity than the carcinoma<sup>[15]</sup>.

RCC with sarcomatoid differentiation are large, with mean tumour size of 9- 10 cm and 90% are symptomatic. Metastatic rate is extremely high at

presentation with 45- 84% having evidence of systemic disease<sup>[16]</sup>. Most common sites of metastasis are lungs, bone, lymph nodes, liver and brain<sup>[7]</sup>.

Sarcomatoid RCC is often treated by surgery as conventional RCC because there is no reliable test to diagnose sarcomatoid differentiation preoperatively. It appears that sarcomatoid RCC shows less desirable response to systemic therapy than RCC with non- sarcomatoid differentiation. Some authors suggest that immunotherapy has less favorable results than chemotherapy and anti-angiogenesis targeted therapy. Surveillance after radical treatment should be based upon risk stratification in these tumors<sup>[18]</sup>.

### Conclusion

RCC with sarcomatoid differentiation is an aggressive tumor associated with disease progression and poor prognosis. Aggressive treatment strategies and close surveillance are required while dealing with these tumors.

### References

1. Renate Pichler, Eva Comp erat, [...], and Manuela Schmidinger. Renal Cell Carcinoma with Sarcomatoid Features: Finally New Therapeutic Hope?. *Cancers (BaseI)*.2019 Mar; 11(3): 422.
2. Jones TD, Eble JN, Wang M, Macclenny GT, Jain S, Cheng L. Clonal divergence and genetic heterogeneity in clear cell renal cell carcinomas with sarcomatoid transformation. *Cancer*. 2005;104:1195-1203. transformation. *Cancer*. 2005; 104:1195–1203.
3. Cheville J.C., Lohse C.M., Zincke H., Weaver A.L., Leibovich B.C., Frank I., Blute M.L. Sarcomatoid renal cell carcinoma: An examination of underlying histologic subtype and an analysis of associations with patient outcome. *Am. J. Surg. Pathol*. 2004;28:435–441.
4. Mikami S., Katsube K., Oya M., Ishida M., Kosaka T., Mizuno R., Mukai M.,

- Okada Y. Expression of Snail and Slug in renal cell carcinoma: E-cadherin repressor Snail is associated with cancer invasion and prognosis. *Lab Investig.* 2011; 91: 1443–1458.
5. Delahunt B., Cheville J.C., Martignoni G., Humphrey P.A., Magi-Galluzzi C., McKenney J., Egevad L., Algaba F., Moch H., Grignon D.J., et al. The International Society of Urological Pathology (ISUP) grading system for renal cell carcinoma and other prognostic parameters. *Am. J. Surg. Pathol.* 2013;37:1490–1504.
  6. De Peralta-Venturina M., Moch H., Amin M., Tamboli P., Hailemariam S., Mihatsch M., Javidan J., Stricker H., Ro J.Y., Amin M.B. Sarcomatoid differentiation in renal cell carcinoma: A study of 101 cases. *Am. J. Surg. Pathol.* 2001;25:275–284.
  7. DALL'OGGIO, Marcos F. et al. Sarcomatoid differentiation in renal cell carcinoma: prognostic implications. *Int. braz j urol.* [online]. 2005, vol.31, n.1 [cited 2020-07-16], pp.10-16.
  8. Bertoni F, Ferri C, Benati A, Bacchini P, Corrado F: Sarcomatoid carcinoma of the kidney. *J Urol.* 1987; 137: 25-8.
  9. Brian Shuch, Gennady Bratslavsky, [...], and Ramaprasad Srinivasan. Sarcomatoid renal cell carcinoma: A comprehensive review of the biology and current treatment strategies. *Oncologist.* Jan 2012;17(1):46-54.
  10. Shuch B, Said J, La Rochelle JC et al. Cytoreductive nephrectomy for kidney cancer with sarcomatoid histology –is upfront resection indicated and,if not, is it avoidable? *J Urol.*2009;182:2164-2171.
  11. Akhtar M, Tulbah A, Kardar AH et al. Sarcomatoid renal cell carcinoma: The chromophobe connection. *Am J Surg Pathol.*1997;21:1188-1195.
  12. Vogelzang NJ, Fremgen AM, Guinan PD et al. Primary renal sarcoma in adults. A natural history and management study by the American Cancer Society, Illinois Division. *Cancer.* 1993;71:804-810.
  13. Bonsib SM, Fischer J, Plattner S et al. Sarcomatoid renal tumors. Clinicopathologic correlation of three cases. *Cancer.* 1987;59:527-532.
  14. DeLong W, Grignon DJ, Eberwein P et al. Sarcomatoid renal cell carcinoma. An immunohistochemical study of 18 cases. *Arch Pathol Lab Med.* 1993;117:636-640.
  15. Kanamaru H, Li B, Miwa Y et al. Immunohistochemical expression of p53 and bcl-2 proteins is not associated with sarcomatoid change in renal cell carcinoma. *Urol Res.* 1999;27:169-173.
  16. Mian BM, Bhadkamkar N, Slaton JW et al. Prognostic factors and survival of patients with sarcomatoid renal cell carcinoma. *J Urol.* 2002;167:65-70.
  17. Cangiano T, Liao J, Nitoh J et al. Sarcomatoid renal cell carcinoma: Biologic behaviour, prognosis, and response to combined surgical resection and immunotherapy. *J Clin Oncol.* 1999; 17:5523-528.
  18. Cleveland P, Tang V. Sarcomatoid renal cell carcinoma. *Uro Onco.*2017;21(6).