



Rhinosporidiosis of Penile Shaft: A Rare Case Report

Authors

Dr Abhilasha Sharma¹, Dr Namita Goyal², Dr Sunita Bhargava³

Department of Pathology, RNT Medical College, Udaipur (Rajasthan)

Corresponding Author

Dr Abhilasha Sharma

Department of pathology, RNT medical college, Udaipur, Rajasthan

Email- abhilasha13886@gmail.com

ABSTRACT

Rhinosporidiosis is a chronic granulomatous disease caused by Rhinosporidium seeberi (earlier described as a fungus, now reclassified in its own class Mesomycetozoea). India and Sri Lanka are the endemic regions for rhinosporidiosis due to temperate climate and widespread custom of bathing in pond water. .

Nose and nasopharynx are involved in most (74.6%) of the cases, followed by eyes (19%). Lesions of rare sites have been reported such as bone, vagina, vulva, oropharynx, buccal mucosa, tongue, paranasal sinuses, skin and subcutaneous tissue, urethra, trachea, larynx and bronchus. Here we present a rare case report of rhinosporidiosis of penile shaft.

Keywords-- Rhinosporidiosis, penile shaft

INTRODUCTION

Rhinosporidiosis was discovered by Malbran, as a sporozoon in 1892. The same organism was first published by Seeber in 1900 and Ashworth described its lifecycle in 1923 and established the name rhinosporidiosis.^[1] It is a chronic disease, with frequent recurrence after surgery, and occasional dissemination from the initial focus which is most commonly seen in upper respiratory sites. Though it has a global distribution, 90% cases are from Asia, mainly from south India, Sri Lanka and Pakistan and less than 5% cases are from Africa and the western countries.

Rhinosporidiosis mostly affects adult men and is possibly transmitted to human subjects by means of direct contact with spores of *R. seeberi* through dust, infected clothing, or fingers and through swimming

in stagnant water contaminated with the spores. Though the mode of infection is not clearly established, frequent bathing in contaminated stagnant water seems to be the cause of infection on a traumatized mucosa. It is not contagious and till now there is no evidence of transmission of the disease from man to man or animal to man. The question of sexual transmission was raised by Symmers of vulval rhinosporidiosis in a female and urethral rhinosporidiosis in a male, both of whom were sexual partners, but it has not been documented by any other author.

CASE REPORT

A 40 yr old male patient presented with a discrete, friable, painless, slow growing sessile mass in the middle of shaft of penis of 1 year duration. The

lesion measured 2.5×2cm, surface was irregular, raw and reddish in color with yellowish pin head sized spots. There was history of bleeding from the mass off & on. There was no history of weight loss, trauma or recurrence. Systemic examination was unremarkable. There was no lymphadenopathy. The routine blood investigations and urine examination were within normal limits. ENT evaluation revealed no evidence of rhinosporidiosis in upper respiratory tract. Biopsy was taken with a clinical suspicion of squamous cell carcinoma or papilloma. Grossly, multiple grey-white to grey-brown soft tissue pieces measuring 1.5cm in all, were received and processed for H & E staining.

Histopathological sections showed multiple sporangia in various stages of maturity, enclosed in a bilamellar thick chitinous wall. The sporangia were 50-1000µm in diameter, containing numerous endospores of diameter 5-10µm. Overlying epithelium was hyperplastic and loose fibrovascular stroma was infiltrated by lymphocytes, macrophages, plasma cells and even polymorphonuclear leucocytes.

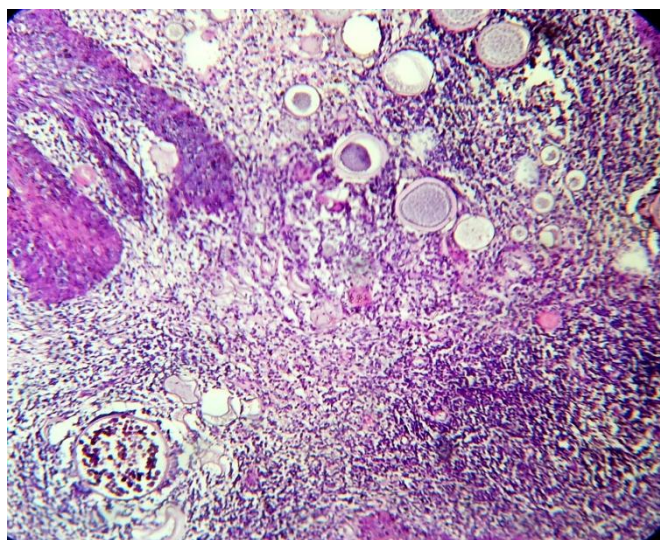


Figure 1: Section showing mature and immature sporangia along with chronic inflammatory infiltrate (H & E 100X)

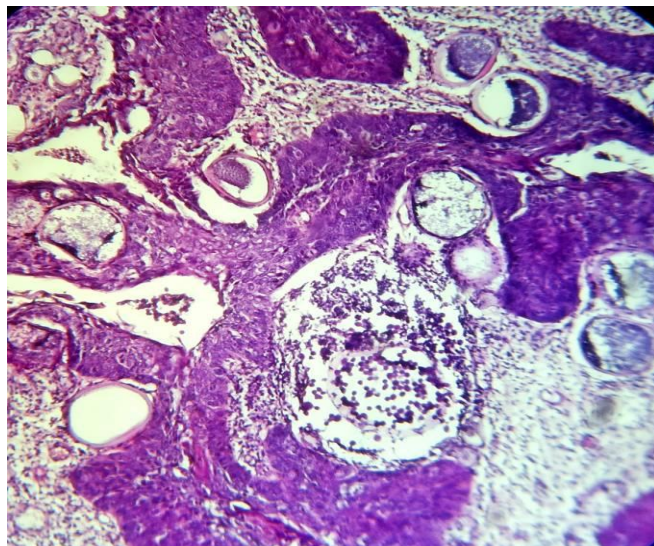


Figure 2: Section showing mature and immature sporangia along with hyperplastic squamous lining (H & E 400X)

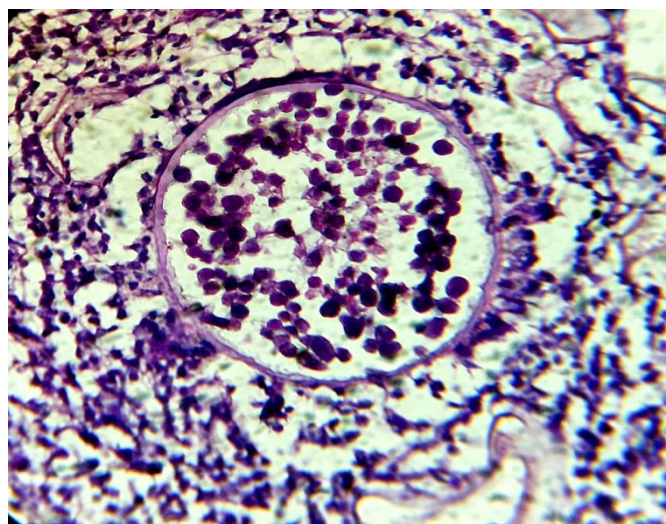


Figure 3: Section showing mature sporangia with endospores surrounded by chronic inflammatory cells (H & E 400X)

DISCUSSION

R. seeberi is no longer considered as a classic fungus. The taxonomic relationship of *Rhinosporidium seeberi* with other organisms remained controversial for more than a century. Recently, molecular studies have suggested *R. seeberi* to be a protistal microbe in the newly described class Mesomycetozoa which lies between animals and fungi. Invasion by this fungus is universal, but it is endemic in India and Sri Lanka. [2]

Rhinosporidiosis is prevalent in India and Sri Lanka due to common practice of bathing in river and pond water. Rhinosporidiosis is more prevalent among males in the age group of 10-40 years. Ground water is considered to be the natural habitat of *R. seeberi*. Mode of infection is supposed to be transepithelial inoculation of organism in traumatized epithelium^[3] Nose and nasopharynx are the commonest sites, followed by conjunctiva, maxillary sinuses, penis, and urethra.

Nasal rhinosporidiosis is easier to diagnose clinically because of its typical polypoid presentation with a granular red surface with pinheaded spots. In contrast diagnosis of extranasal rhinosporidiosis is difficult on the basis of clinical presentation because it may be confused with benign cystic lesions, soft tissue tumors and papillomas.

There are primarily three modes of spreads of the lesions viz. autoinoculation, hematogenous, and direct inoculation. Trophocyte of *R seeberi* gives rise to mature sporangium which are seen as white punctuate dots through submucosa. From mature sporangium, endospores (the infective unit) are released and they usually produce the classic lesion of rhinosporidiosis upon entry through a breach in the epithelium on the mucosal surface of the body.^[4] Diagnosis of rhinosporidiosis should be kept in mind in all granulomatous lesions involving the mucous membranes in the endemic areas.

Microscopically, demonstration of endospores of 5-10 μm and sporangium of 50-1000 μm in the histopathological sections clinches the diagnosis.

Rhinosporidiosis lesions may be confused with other fungal lesions in cytology as well as histology. It should be differentiated from myospherulosis (subcutaneous spherulocytic disease), *Coccidioides immitis* and *Chrysosporium parvum* var. *crescens*. Special stain like Gomori methanamine silver, Gridley's and PAS stain, mucicarmine stains help to distinguish them from other organisms. *C. immitis* have similar thick spherical wall with endospores inside, but sporules are smaller (20-80 μm vs. 50-100 μm in rhinosporidiosis) and arthroconidia and hyphae may be present in *C. immitis* lesions.

Endospores of *R. seeberi* are longer in size and numerous in contrasts to *C. immitis*.

Surgical excision of the lesion with diathermy coagulation of the base is the only treatment in rhinosporidiosis Endoscopic resection and electro-fulguration of the base is an alternative treatment.^[5]

Follow-up is mandatory because of high recurrences with incidences of 3.6 to 25%. The recurrences are mainly due to inadequate excision or re-infection.

CONCLUSION

Our literature search did not find any case of rhinosporidiosis affecting the penile shaft; however we encountered few case studies affecting the external urethral meatus.

We report this case for its rarity of occurrence in this anatomical location. The clinicians need to keep a high index of suspicion when patients present with such lesions in an endemic geographic location such as southern India, even in the absence of mucosal lesions.

REFERENCES

1. Pal S, Chakrabarti S, Biswas BK, Sinha R, R akshit A, Das PC. Cytodiagnosis of extra-nasal rhinosporidiosis. Journal of Laboratory Physicians 2014 ; 6 (2)
2. Daharwal A, Banjara H, Singh D, Gupta A, Singh S. A rare case of laryngeal Rhinosporidiosis. Journal of laryngology and voice 2011; 1(1)
3. Sinha A, Phukan JP, Bandyopadhyay G ,Sengupta S, Bose K, Mondal RK, Choudhuri M K. Clinicopathological study of rhinosporidiosis. Journal of Cytology 2012 ; 29 (4)
4. Mukhopadhyay S, Datta H, Sen D . DALK in Intracorneal Rhinosporidiosis. Middle East African Journal of Ophthalmology 2014 ; 21 (4)
5. Pal DK, Moulik D, Chowdhury MK. Genitourinary Rhinosporidiosis. Indian J Urol 2008; 24 (4)