



Atypical Presentation of *Pediculus Humanus Capitis* Infestation with Periorbital Swelling

Authors

Dr Ankit Soni¹, Dr Sheeba Maqsood², Dr. Garima Vasudev³

Institute of Ophthalmology, Aligarh Muslim University, Aligarh, Uttar Pradesh, India

Corresponding Author

Dr. Ankit Soni

A10/18, Soni Medical Agencies, Prahladghat, Varanasi, Uttar Pradesh (221001), India

(+91-7838526297, 8958758680, 0542-2435885)

Email: a.soni23@yahoo.com

Abstract

Head louse infestation caused by *Pediculus humanus var. capitis*, usually presents with itching of the scalp as the chief symptom, whereas presence of viable nits confirms the diagnosis. Secondary bacterial infection with impetiginization with cervical and occipital lymphadenopathy can complicate the clinical scenario with physician misdiagnosing pediculosis to a primary bacterial infection. We report an extremely rare presentation of Head louse infestation (*Pediculosis capitis*) as periorbital swelling in a young girl. A 16-year-old girl presented with painless periorbital puffiness around both her eyes. Ocular bio microscopy and dilated ophthalmoscopy were unremarkable. The hair on her head appeared ropy, dry, teeming with lice and nits. She underwent counseling, received oral antibiotic, encouraged to have repeated head wash and improve her personal hygiene. Specific anti-lice treatment along with combing with a fine toothed comb was advised. After treatment, periorbital swelling subsided, the hair was of normal texture with healthy underlying scalp and no evidence of lice or nits. *Pediculus humanus capitis* is a common health concern in the pediatric age group and it can also rarely present as periorbital swelling in humans.

Keywords- *Pediculosis capitis*, periorbital swelling, *Pediculus humanus capitis*

Introduction

It is the pubic lice which usually infest the lids and lashes leading to phthiriasis palpebrum¹. Periorbital swelling due to insect infestation has been reported due to dirofilariasis, *Oestrus ovis*². Dirofilariasis is a zoonotic infection, which is occasionally seen in humans and rarely found as a subcutaneous orbital swelling. The sheep blot fly larva of *Oestrus ovis* is a mammalian parasite of skin, nose, ears and eyes³. When the larvae infest

and feed on the structures of the eye, the condition is termed ophthalmomyiasis. Symptoms include severe local inflammation, positive foreign body sensation, erythema and lacrimation. We report, probably, the first case of bilateral periorbital swelling due to head lice. No literature on *Pediculus humanus capitis* associated with swelling around the eye was found even after extensive search on PubMed and Google.

Case Report

A 16 year old spectacled girl, a boarding student, presented with painless periorbital puffiness around both her eyes of 2-3 days duration. She appeared to be conservatively dressed with her head well covered (Figure1). With her glasses (OD: -6.00-2.00x75 and OS: -5.00-1.25x180) her vision was 20/20 OU. Ocular biomicroscopy and dilated ophthalmoscopy were unremarkable; cycloplegic refraction confirmed her prescription as appropriate. There was no phoria or tropia.

The periorbital swelling was diffuse, non-tender, transilluminant with no change in local temperature. Closer inspection revealed pitting marks of foot plates of her spectacles astride the nasal bridge. No local lymphadenopathy was detected.

On careful examination, mild crusting with dotted pigmentary change and occasional fine bleeding points were noticed around the hair line on forehead. There was reluctance on the part of patient to uncover her head. With gentle encouragement she agreed to expose her head. The hair on her head appeared ropy, dry, rough, and congealed into strips; while the hair was teeming with lice and nits (Figure 2). We observed a faint stale odour. Careful inspection revealed numerous bleeding points on her entire scalp. On direct questioning, we learnt that her parents were abroad and that she had not left the hostel for over a year.

Dermatological and psychiatric consultations were sought. A diagnosis of *Pediculus humanus capitis* infestation with secondary skin infection was made. She underwent counseling and received oral antibiotic. She was encouraged to have repeated head wash and improve her personal hygiene. Although specific anti-lice treatment with permethrin 1% was advised, she opted to use the locally popular herbal product, along with combing with a fine toothed comb. On reviewing a week later, the periorbital puffiness had subsided, and the lice load was markedly reduced (Figure 3). She was advised to continue the anti-lice measures over the next two weeks and at

last follow up one month later the hair was of normal texture with healthy underlying scalp and no evidence of lice or nits (Figure 4).

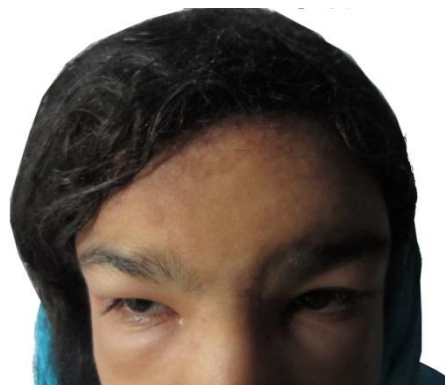

Figure 1: Crusting with pigmentary changes around hair line. Note the dry rough appearance of the hair.

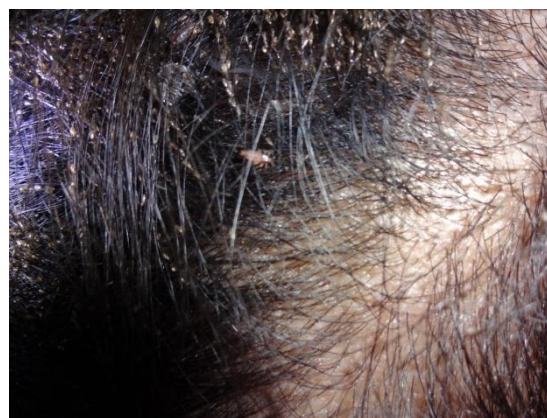

Figure 2: Lice and nits on scalp.

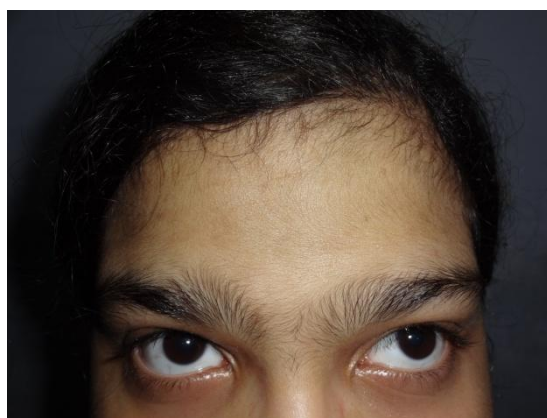


Figure 3: Periorbital swelling decreased after 1 week.

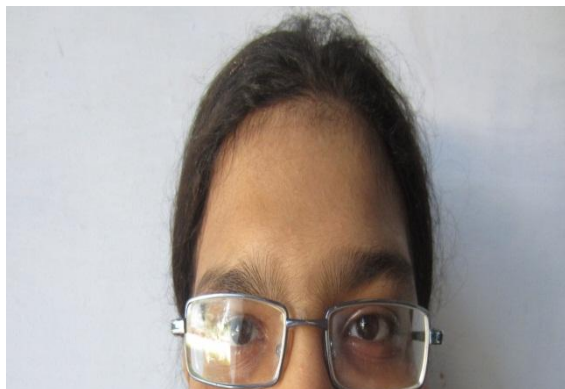


Figure 4: After one month follow up showing normal texture of hair with healthy underlying scalp and no evidence of lice or nits.

Discussion

Head louse infestation, or pediculosis capitis, caused by *Pediculus humanus var. capitis*, is a common health concern in the pediatric age group⁴. It presents chiefly with itching and the presence of lice and nits confirms the diagnosis. Secondary bacterial infection with impetiginization with cervical and occipital lymphadenopathy can occasionally complicate the clinical setting; and on occasion supervene with the pediculosis infestation being missed.

Our patient probably had a high load of the lice over a prolonged period, where itching lead to secondary mild bacterial infection. The associated inflammation lead to edema which gravitated down to present as periorbital edema since the lid skin has loose connective tissue which permits such an event. Screening and treatment of all close contacts is necessary for an adequate management of pediculosis. Local application of neurotoxic pediculicidal agents such as permethrin 1% lotion, malathion (0.5%) or lindane shampoo is usually advised and effective^{5,6,7}. Mechanical removal with a fine-toothed comb is a useful adjunctive measure⁸. Occlusive agents such as benzyl alcohol 5%, work by clogging the respiratory spiracles and is reportedly successful in 75% when used as two scalp applications a week apart⁹. Severe cases may warrant oral Ivermectin (off label) or rarely the need to resort to complete shaving the scalp¹⁰.

Importantly bedding, clothes and toys need treatment too: suggested measures include laundering in hot water followed by machine drying with the hottest cycle, dry cleaning, and careful sealing fomites in plastic bags for up to a fortnight since the adult lice and their subsequent brood (which hatch in 7-10 days) perish without a blood meal.

Conclusion

Our case is of singular interest primarily on account of presenting as periorbital edema with head louse infestation, an event hitherto unreported. *Pediculus humanus capitis* is a common health concern in the pediatric age group and it can also rarely present as periorbital swelling in humans.

References

1. Dornic DI. Ectoparasitic infestation of the lashes. J Am Optom Assoc. 1985 Sep;56 (9):716-9.
2. Eccher A, Dalfior D, Gobbo S, Martignoni G, Brunelli M, Decaminada W, Bonetti F, Rivasi F, Barbareschi M, Menestrina F. Periorbital subcutaneous tumor like lesion due to Dirofilaria. Int J SurgPathol. 2008 Jan;16 (1):101-3.
3. Gregory AR, Schatz S, Laubach H. Ophthalmomyiasis caused by the sheep blot fly Oestrus ovis in northern Iraq. Optom Vis Sci. 2004 Aug;81(8):586-90.
4. Madke B, Khopkar U. Pediculosis capitis: An update. Indian J Dermatol Venereol Leprol. 2012 Jul;78(4):429-38.
5. Abramowicz. Drugs for head lice. Med Lett Drugs Ther. 1997;39:6-7.
6. Mumcuoglu KY. Effective treatment of head louse with pediculicides. J Drugs Dermatol. 2006 May;5(5):451-2.
7. Elston DM. Drugs used in the treatment of pediculosis. J Drugs Dermatol. 2005 Mar-Apr;4(2):207- 11.

8. Ibarra J, Hall DMB. Head lice in schoolchildren. Arch Dis Child 1996;75: 471-473.
9. Parlman DL. A simple treatment for head lice: dry-on, suffocation-based pediculicide. Pediatrics. 2004;114(3):275-9.
10. Burkhart CG, Burkhart CN, Burkhart KM. An assessment of topical and oral prescription and over-the-counter treatments for head lice. J Am Acad Dermatol 1998;38: 979-982.