



Omental Prolapse Presenting 72 Hours after Delivery. Delayed Manifestation or Delayed Presentation: An Enigma

Authors

Dr Dalia Rafat¹, Dr Zehra Mohsin²

¹Deptt. of Obstetrics & Gynaecology, J N Medical College & Hospital, Faculty of Medicine, Aligarh Muslim University, Aligarh, UP, India-202002

²Deptt. of Obstetrics & Gynaecology, J N Medical College & Hospital, Faculty of Medicine, Aligarh Muslim University, Aligarh, UP, India-202002

Corresponding Author

Dr Dalia Rafat

Deptt. of Obstetrics & Gynaecology, J N Medical College & Hospital, Faculty of Medicine, Aligarh Muslim University, Aligarh, UP, India-202002

Email: drdaliarafat.16@gmail.com

Abstract

Vaginal birth after caesarean section (VBAC) is a safe and effective method to reduce the rate of repeated CS and its associated morbidity and mortality but its success depends on many factors. Omental prolapse secondary to uterine rupture is a rare and dreaded complication in women attempting VBAC and its late presentation is much more rarer. A unique case of uterine rupture was discovered when a woman presented 72 hours after delivery with pain abdomen and on examination omentum was noted protruding through the vagina. Whether the uterine rupture followed by omental prolapse, occurred late or patient presented so late remains unexplained in our case. This case also highlights the importance of the patient education and counselling for institutional delivery and failure of health care professionals in achieving it.

Keywords: *Omentum, Uterine Rupture, Postpartum, Caesarean section*

Introduction

Uterine rupture is a rare but grave complication in obstetrical practice. Prior cesarean section (CS) is the most important predisposing factor for this catastrophic event. Although vaginal birth after cesarean section (VBAC) has a high index of safety and is intended to reduce maternal

morbidity and mortality substantially, the major concern is of uterine rupture. It usually occurs during labor with such a scarred uterus and patient reports either in intrapartum or immediate postpartum period. We here report a case of uterine rupture who presented to us 72 hours post delivery.

Case Summary

A 23-year-old woman presented to us with complaint of pain abdomen since one day. There was no history of fever, chill, nausea, vomiting, dysuria and inability to pass flatus and faeces. Patient gave history of vaginal delivery three days back at home, by an untrained birth attendant. After difficult delivery she delivered a good sized dead baby. As it was home delivery she cant tell exactly the weight of the baby and cause of death. According to her she was apparently well two days post delivery when she developed pain abdomen which gradually increased in severity over 24 hours and so patient presented to us with severe pain abdomen. Her past medical and surgical history was uneventful except for a caesarean section one year back for fetal distress. On examination she was pale, had a blood pressure of 114/80mmHg and a pulse of 96 beats per minute. On per abdomen examination she had supra pubic tenderness with guarding. A cloth was found inserted into vagina, after removal of which we were appalled to see the omentum protruding into the vagina[Figure1]. A piece of cloth was also seen alongwith omentum. A diagnosis of uterine rupture was made and the patient was prepared for laparotomy. Half a litre of haemoperitoneum was encountered. A full thickness tear along the lower segment transverse scar was found which was repaired in layers [Figure 2]. A part of omentum was found necrosed and so removed. An intraperitoneal drain was inserted and the rest operation was uneventful. One unit blood was transfused and patient was put on broad spectrum

antibiotics. Patient recovered well in postoperative period and was discharged 8 days after surgery in good health.

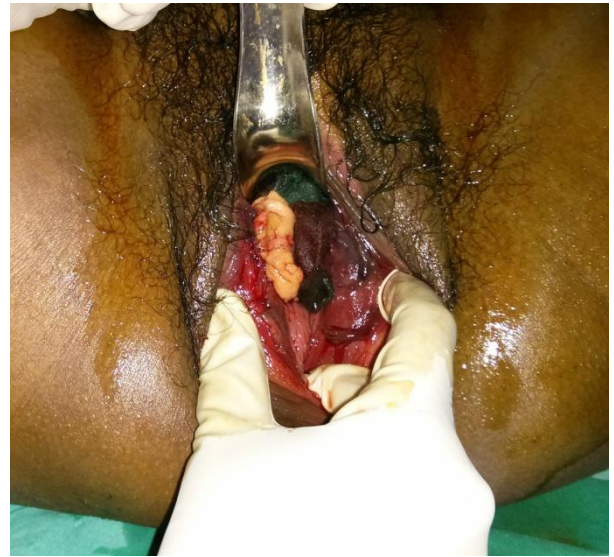

Figure 1: Omentum prolapsed through vagina along with piece of cloth.

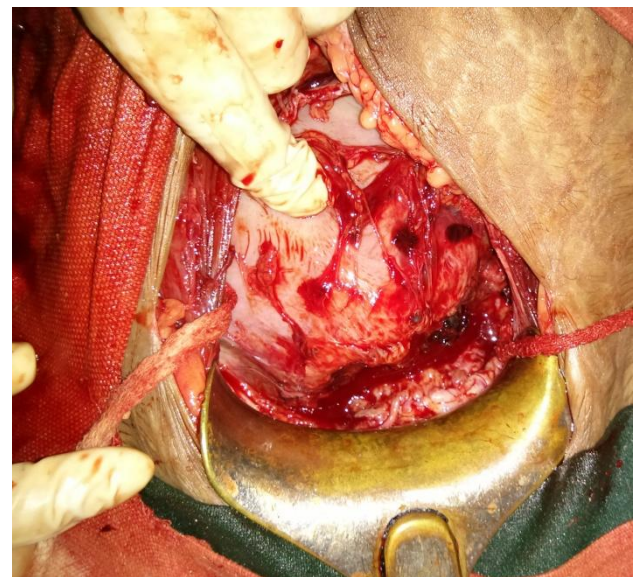


Figure 2. Transverse tear along the previous scar.

Discussion

CS is the most common surgery performed by obstetricians and its rate is progressively rising throughout the world [1]. Because of the substantially higher maternal morbidity associated with a recurrent CS than that with vaginal

delivery^[2], VBAC has gained popularity in the past two decades. It had been regarded as a safe and effective method to reduce the rate of repeated CS and its associated morbidity and mortality. However, studies demonstrating higher maternal and fetal complications in patients undergoing a trial of labor after CS than in those delivered by an elective repeat CS have been reported in literature^[3,4]. Uterine rupture is the most serious complication of VBAC and is reported in 0.5%–0.7% of women who underwent a trial of labor^[5]. It usually presents in intrapartum period when it occurs due to uterine contractions and manifests as changes in fetal heart rate patterns and/or vaginal bleeding, prompting an emergency CS. It may also present in the immediate postpartum after placental extraction or uterine exploration and patient then presents with brisk hemorrhage and/or abdominal pain or tenderness. The uniqueness of our case lies in its presentation. Patient presented to us 72 hours post delivery with vitals maintained and no complain of hemorrhage. Uterine rupture manifesting as omental prolapse is itself very rare with only few cases being reported in literature^[6-8]. Late presentation of this manifestation ie 72 hours postpartum is extremely rare and to the best of our knowledge, this is the first report in the English literature of its kind. What is the cause of this unusual presentation in our case? We can think of several possibilities. Since both prior deliveries did not occur in our hospital, it was not possible to cross check her medical records. Neither was it possible to establish what pattern of labour patient underwent.

The first possibility is that as the woman gave history of delivering a dead baby means that the rupture could have occurred earlier whence foetal life was lost. If this would have been the case with our patient than foetus would have been expelled through the tear into the peritoneal cavity and than vaginal delivery was not feasible. Second possibility is that the shoulder dystocia could have led to the uterine rupture, as patient gave history of difficult delivery of a good sized baby but in such case there would be history of brisk hemorrhage and then the cause of foetal demise remains unknown. Third possibility is of uterine rupture occurring during management of third stage either during placental delivery or overzealous uterine and scar exploration but again in such case patient would have presented in immediate postpartum period with pain and/or brisk hemorrhage. One remote possibility is of late rupture and a case presenting upto three weeks postpartum has been reported^[9] but this scenario again doesn't fits into our case as if rupture didn't occurred at the time of delivery than why was the cloth inserted into the vagina though it might be inserted just for hemorrhage. So none of the possibilities completely fits into our scenario and the condition which answers most of the queries is ignorance. In this part of the world, it is not uncommon for women delivering at home and labor being mismanaged by untrained birth attendant as is the case with our patient. But they usually send patient to some institution in case of complication. In our patient either she was not able to detect omental prolapse or prolapse

occurred later from the ruptured scar. The other mystery is absence of history of hemorrhage which can to some degree be explained by speculating that the edges of previous scar were fibrosed so didn't bleed much.

Conclusion

In conclusion whether VBAC is a boon or bane depends on many factors and a safe and beneficial procedure can lead to catastrophe in inexperienced and illequipped hands. Also, uterine rupture should be considered in the differential diagnosis of pain even without much bleeding in the late postpartum. Prompt identification of this condition, helps in decreasing its associated morbidity and mortality. Here also lies the importance of patient education and counselling. Had the patient been properly sensitized about these consequences at the time of first CS she might not have attempted delivering at home this time.

References

1. Martin JA, Hamilton BE, Sutton PD, Ventura SJ, Menacker F, Kirmeyer S. Births: final data for 2004. Natl Vital Stat Rep 2006;55(1):1–101.
2. Allen VM, OConnell CM, Baskett TF. Maternal morbidity associated with cesarean delivery without labor compared with induction of labor at term. Obstet Gynecol 2006;108(2):286–294.
3. Flamm BL, Goings JR, Liu Y, Wolde-Tsadik G. Elective repeat cesarean delivery versus trial of labor: a prospective multicenter study. Obstet Gynecol.1994;83(6):927–932.
4. McMahon MJ, Luther ER, Bowes WA Jr, Olshan AF. Comparison of a trial of labor with an elective second cesarean section. N Engl J Med1996;335(10):689–695.
5. Landon MB, Hauth JC, Leveno KJ, et al; National Institute of Child Health and Human Development Maternal-Fetal Medicine Units Network. Maternal and perinatal outcomes associated with a trial of labor after prior cesarean delivery. N Engl J Med 2004;351(25):2581–2589.
6. Singhal SR, Singhal SK, Gupta P: Bowel and omentum prolapse into the vagina after third stage: an unusual presentation of ruptured uterus. Acta Obstetrica et Gynecologica 2008, 87:577–581.
7. Mwenda AS: 4th Stage Transvaginal omental herniation during VBAC complicated by shoulder dystocia: a unique presentation of uterine rupture. BMC Pregnancy and Childbirth 2013, 13:76.
8. Guasch E, Millan MJ, Gilsanz F, González A: Omentum through the vulva as the first sign of uterine rupture. Anesth Analg 2004, 99:1871–1882.
9. El-Kheddy GI, Ghanem JK, El-Rahi CC, Nakad TI: Rupture of uterine scar 3 weeks after vaginal birth after caesarean section (VBAC). Matern Fetal Neonatal Med 2006, 19(6):371–373.