



Study of Functional Outcome of Arthroscopic Bankart Repair using Caspari Technique in Recurrent Anterior Shoulder dislocation

Authors

**Ramprasad Rallapalli^{1*}, Vidyasagar J.V.S², Ankur Mittal¹, Anil Kumar D²,
Subrahmanyam B², Bhartah Reddy², Praveen Kumar²**

¹Dept. of Orthopaedics, Narayana Medical College and Hospitals, Nellore, Andhrapradesh, INDIA

²Dept. of Orthopaedics and Sports Medicine, Aware Global Hospitals, Hyderabad, Telangana State, INDIA

Corresponding Author

Dr. Ramprasad R

Assistant Professor, Dept. of Orthopaedics, Narayana Medical College and Hospitals, Nellore-524003,
Andhrapradesh, INDIA

Email: research.nmch@rediffmail.com

Abstract

Objective: *The purpose of this study is to evaluate functional outcome of arthroscopic bankart repair using caspari technique in recurrent anterior shoulder dislocation.*

Methods: *A prospective study was done which include 20 patients of shoulder instability to evaluate the results of arthroscopic repair of the Bankart lesion of shoulder with Trans Glenoid suture technique with reference to results of Rehabilitation program and final Surgical and Functional outcome.*

Results: *None of the 20 patients had episode of recurrent dislocation or anterior translation or apprehension. Range of movement-external rotation in 90° of abduction improved in 17 patients (85%). There is complication of wound infection in only 1 patient.*

Conclusions: *We conclude that Arthroscopic Bankart repair with caspari technique in recurrent anterior shoulder dislocation is a reliable and cost effective procedure with respect to shoulder function, recurrence rate and range of movement.*

Keywords: *Anterior shoulder instability ; Arthroscopic translgenoid suture; Caspari technique.*

INTRODUCTION

Shoulder, by virtue of its anatomy and biomechanics, is one of the most unstable and frequently dislocated joints in the body.¹ Bankart² (1920) published a paper stating that in acute dislocations the humeral head is forced anteriorly out of the glenoid cavity and tears not only the

fibrocartilaginous labrum from almost the entire anterior half of the rim of glenoid cavity, but also the capsule and periosteum from anterior surface of the neck of scapula. This traumatic detachment of glenoid labrum has been called the Bankart lesion. The Bankart lesion represents the most common form of labro-ligamentous injury in

patients with traumatic dislocations of the shoulder. Surgical treatment is by reattachment of the labro-ligamentous complex to the glenoid either arthroscopically or during an open procedure (Bankart repair).³

Several open and arthroscopic techniques have been described to address anterior shoulder instability. These procedures address both capsulo-ligamentous laxity and labral pathologies via a variety of instruments, suture passages, knot-tying techniques, and fixation devices. With the debate continuing regarding the indications for arthroscopic shoulder stabilization, several studies have shown favorable outcomes with regard to the arthroscopic method.⁴⁻⁶ Moreover, with continuing criticisms with regard to the wide dissection, loss of external rotation, and postoperative pain associated with the open repair, the demand for arthroscopic surgery has increased over the past two decades. Arthroscopic Bankart repair for the treatment of instability of the shoulder has become increasingly popular as it has less morbidity, shorter time of surgery, improved range of motion, improved cosmesis, and less post operative pain.⁶

The purpose of present study is to verify functional outcome of the patients with recurrent dislocation of shoulder with Bankart lesion, treated with arthroscopic stabilization with Trans glenoid sutures Caspari technique

MATERIAL AND METHOD

A prospective study was taken in the Department of Orthopedics, Arthroscopy and Sports Medicine at Aware Global Hospital, Hyderabad between July

2014 to September 2014. A sample of 20 patients of shoulder instability which met our inclusion criteria were included in the study. The present study was undertaken to evaluate the results of arthroscopic repair of the Bankart lesion of shoulder with Trans Glenoid suture technique with reference to:

1. Results of Rehabilitation program
2. Final Surgical and Functional outcome.

The principal author of this work, who is working as Asst. Professor in Department of Orthopaedics, Narayana Medical College & Hospitals has been posted to complete his fellowship at Aware Global Hospitals, Hyderabad. Therefore, this study has been taken ethical clearance by Aware Global Hospital Ethics Committee, Hyderabad, Telangana State.

Inclusion and Exclusion criteria:

Inclusion criteria:

- All patients above 18 years of age with recurrent dislocation of the shoulder with Bankart lesion.

Exclusion criteria:

- Other shoulder pathologies such as
 - Biceps rupture
 - Bony Bankart
 - Rotator cuff tear
- Significant defects of the humeral head (greater than 30%) requiring bone graft or rotational osteotomy of proximal humerus.
- Multidirectional instability and posterior instability of shoulder.
- Arthritis of shoulder.

Surgical technique used- Caspari technique

Anterior attachment of avulsed glenoid labrum (Bankart's lesion) and capsule with trans osseous Ethibond (no 5) sutures.

Anesthesia:

A regional anesthesia with interscalene block combined with general anesthesia with an LMA tube taped securely on the site opposite to the side of surgery.

Patient Positioning:

Lateral decubitus position.

Procedure:

Posterior portal was developed first and evaluation of shoulder was done and findings noted.

The joint inspected for evidence of

- Substantial articular injury
- Concomitant injury to biceps origin,
- Humeral avulsion of the glenohumeral ligament or a rotator cuff tear.
- The antero-inferior aspect of the labrum was evaluated.
- Presence of a Bankart lesion noted in all patients.

Then anterior portal by outside in mechanism was established under arthroscopic guidance and then maintained with green cannula is introduced for instrumentation purpose. (Figure 1). Then beth pin is introduced through anterior portal (Figure 2). Introduced beth pin is directed towards anterior part of avulsed labrum where beth pin lifts the labrum and brings back the labrum to its native place (Figure 2).

Placing beth pin at slope of glenoid along with labrum, beth pin is attached to man-man and drilled for one second and stopped for one second

to make sure it does not slip and stays on bone. This rule is followed until both pierce glenoid completely. As both pin is introduced the labrum comes back to its native place (Figure 3). Usually 2 or 3 beth pins are required spacing at least 5mm depending on the extent of labral tear and both pins are directed away from the vertebral column (Figure 3). Once both pins are introduced Ethibond no 5 is passed between them. Then both pins are pulled out posteriorly along with Ethibond with the help of a T-handle. Ethibond threads are held tightly to see the formation of anterior bumper. Once anterior bumper is confirmed shoulder is deflated and arthroscope is removed, so that there won't be any laxity of capsule while tightening Ethibond. Ethibond threads are brought out through a single hole under the posterior musculature with help of 90 degree hemostat. Surgical knots are tied posteriorly. Ethibond tags are cut and skin is checked for any puckering. Sterile dressing applied and patient is shifted in shoulder arm pouch.

Pre operative evaluation**General principle:**

Overall evaluation of musculoskeletal system through a systematic approach of inspection, palpation, range of motion analysis, strength testing, neurological evaluation, shoulder stability assessment and specialized testing.

Visual inspection:

Deltoid atrophy and weakness evaluation to rule out injury to axillary nerve.

The Sulcus Sign

Winging of scapula

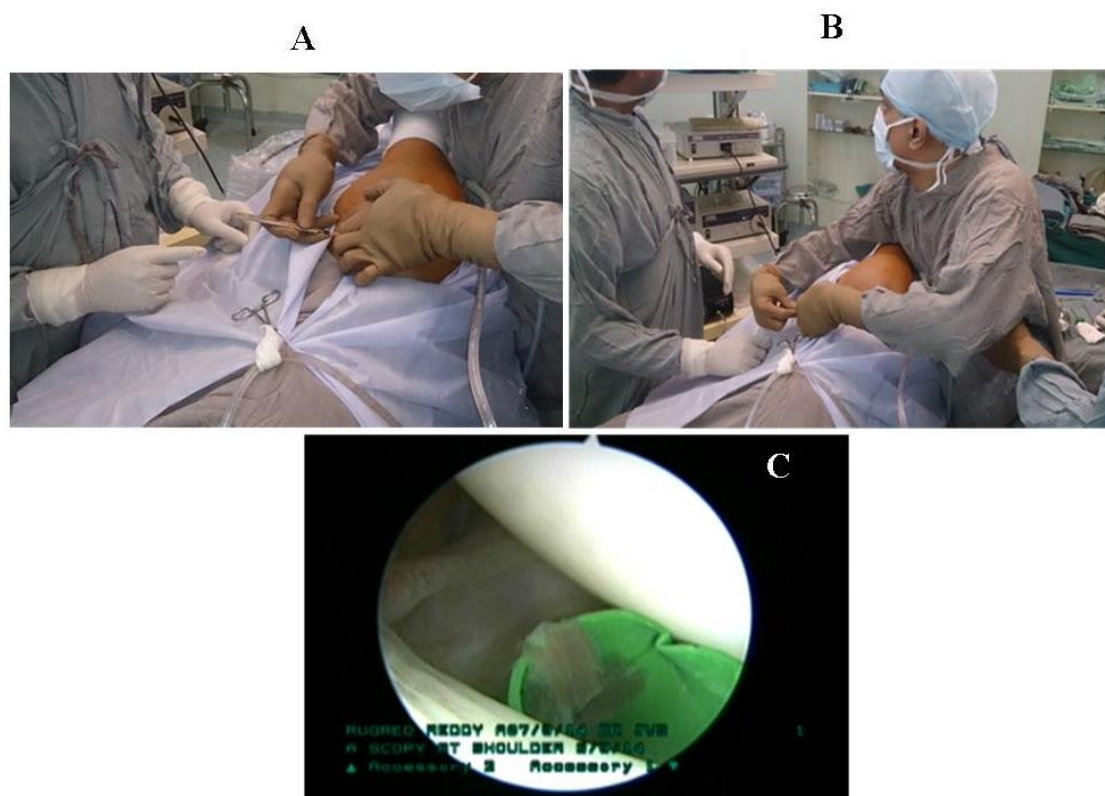


Figure 1. Establishing anterior portal and Introducing green cannula to maintain anterior portal

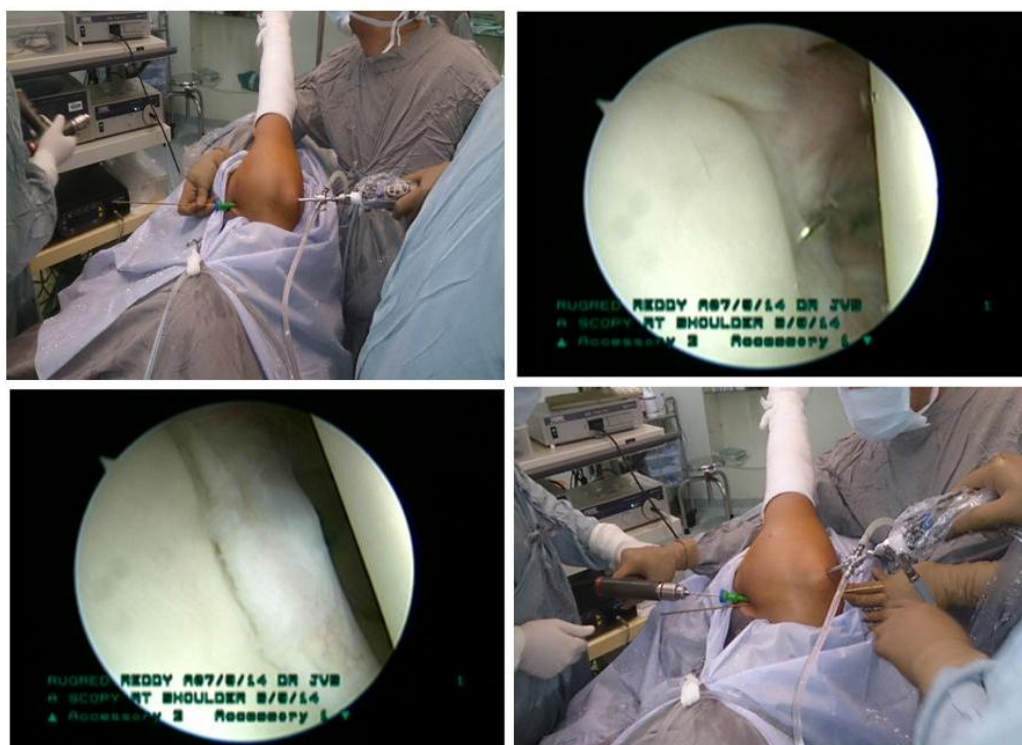

Figure 2. both pin introduction through anterior portal at level of anterior labrum; Anterior labrum comes back and both pin is passed posteriorly.

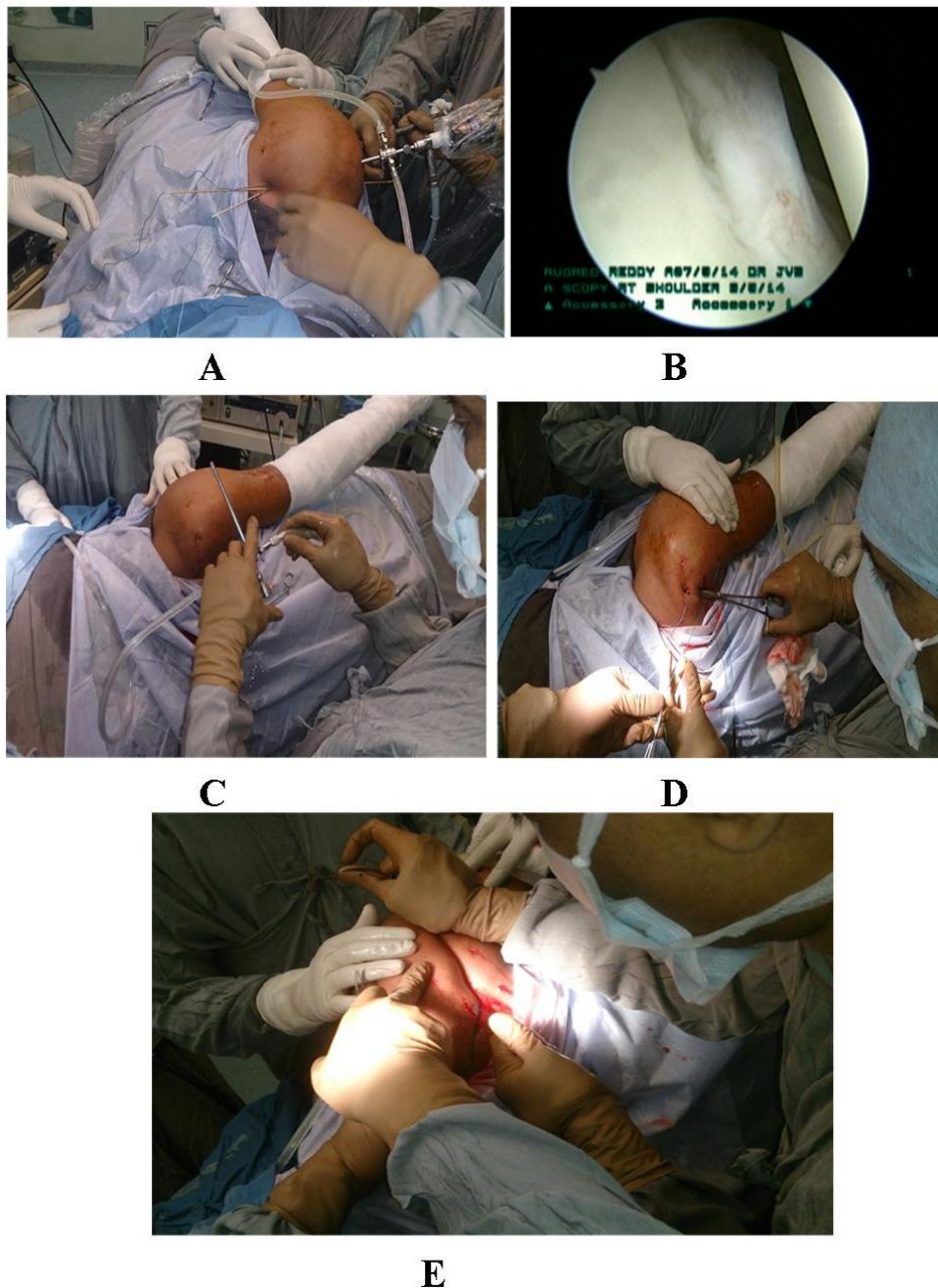


Figure 3. 2nd and 3rd both pins are passed in a similar way and ethibond is passed through them. All both pins are extracted posteriorly. Anterior labral bumper is created and ethibond knots are tied posteriorly.

Palpation:

Local tenderness

Muscle tone.

Range of Motion:

Both active and passive range of motion recorded.

Dyskinesia and accessory muscles acting noted.

Crepitations occurring on Range of Motion testing

recorded. While assessing the Range of motion, strength of the muscles bringing about pain-free range of motion recorded. The results are compared with normal side. Generalized ligamentous laxity may be associated with shoulder instability; this is assessed by Bighten score.

Specific tests:

The examination should first be initiated on the unaffected shoulder to obtain baseline data for each subsequent test and also to make patient comfortable with each maneuver. Two components are considered when assessing the stability of the glenohumeral joint.

1. The amount of passive translation of the humeral head and glenoid fossa on stress testing

2. Attempts to reproduce the symptoms of subluxation and apprehension by provocative testing of the shoulder in positions of compromise.

- **Sulcus Sign test:**
- **Inspectory sulcus sign:**
- **Translation tests (Load and Shift):**
- **Apprehension test:**
- **Relocation test:**
- **Release test:**
- **Examination under Anesthesia:**

Cofield and Irving²⁹ noted that examination under anesthesia is the most definitive accurate, noninvasive test of shoulder instability. Examination under anesthesia produces sufficient muscle relaxation and pain free hence the diagnostic tests can be performed effectively. The sensitivity and specificity of examination under anesthesia improved by examining the shoulder in various positions of shoulder elevation and rotation.

Investigations**Radiographic evaluation:**

Routine radiological examination are essential to exclude the associated bone or soft tissue calcification adjacent to anterior and antero-

inferior rim of glenoid. Initial plain film evaluation of the shoulder include A true Antero-Posterior (AP) view Axial view.

Magnetic Resonance Imaging:**Magnetic Resonance Imaging defines**

- Labral and Capsuloligamentous pathology
- Additional shoulder pathology such as rotator cuff tear can be demonstrated
- Congenital and age related variations in the anterior labrum
- Complex labral tears, capsular stripping from the glenoid
- Muscle atrophy caused by Suprascapular and axillary nerve injury.
- Bony lesions such as Hill-Sachs lesion.

Post operative regimen and rehabilitation program***1-3 weeks post-operation***

Main emphasis is on regaining flexion range of movement. External rotation is restricted.

- a. Wean out of sling
- b. Mobility exercises – mainly flexion
- c. Progress to active assisted
- d. Start isometric cuff work in neutral (pain- free & scapula stable)
- e. Avoid passive stretch external rotation beyond 20°
- f. Avoid combined abduction & external rotation

If appears to be regaining full range of movement very quickly – stop mobility work and concentrate on cuff rehabilitation.

3-6 weeks post-operation

Main emphasis is on increasing muscle activity (cuff and scapula) with optimal movement patterning.

- a. Range of movement should be approx 75% flexion contra lateral side.
- b. External rotation should be restricted still (50% contra lateral shoulder).
- c. Progress cuff activity.
- d. Progress scapula muscle activity.
- e. Do not work or stretch into combined abduction/lateral rotation.
- f. Proprioceptive muscle work.

6-12 weeks post-operation

Main emphasis is on power, endurance & Proprioceptive muscle work aiming towards functional activities.

- a. Progress resistance through range.
- b. Stretches if necessary for functional activities, but external rotation range should remain tighter.
- c. Function specific training.

Guidelines for returning to activities

- Driving at four to six weeks
- Return to non contact sport at twelve weeks.
- No contact sport for six months minimum.

Results

This is a study of surgical and functional outcome of Arthroscopic Bankart Repair in Recurrent Anterior Shoulder Dislocation with trans glenoid suture caspari technique.

- Most patients are in the age group between 25-45 years
- 85% of the patient were males
- 65% of the patients were involved in significant occupation and most of them are traumatic in origin due to sports activity
- Majority of patients had symptoms for a period ranging from 1 to 5 years (70%)

- 14(70%) patients had their Right shoulder involved
- 18(90%) patients had pain and discomfort pre operatively
- 13(65%) patients had very unstable shoulder joint pre operatively
- 10(50%) patients had more than 5 recurrent dislocation episodes preoperatively
- 19 (95%) patients had anterior translation, of which 14(70%) patients with mild anterior translation and 5(25%) with moderate grade.
- 18(90%) patients had apprehension test positive pre operatively
- 18(90%) patients had atrophy of muscles around shoulder pre operatively
- 13(65%) patients had limitation of external rotation on 90° abduction preoperatively
- In 15(75%) patients 2 beth pins were used and in 5(25%) patients 3 beth pins used intra operatively.

Post operative follow up:

- Mean follow up period 12 months
- One patient out 20 patients complained of pain and discomfort
- None of the 20 patients had episode of recurrent dislocation
- None of the 20 patient had anterior translation or apprehension
- Range of movement-external rotation in 90° of abduction improved in 17 patients (85%)
- One patient (5%) had complication in the form of discharge from wound 7 months after surgery for which debridement was done and ethibond sutres removed. Then, patient has no complications and there is no evidence of instability.

DISCUSSION

Anterior glenohumeral instability is the most common form of instability around the shoulder joint.^{11,12} It usually affects young adults and most of the cases arise secondary to traumatic dislocations. Rowe and Zarins reported a rate of 95.6% traumatic origin to anterior dislocation in their study that included 500 patients.¹³ Similarly, all patients in our study had recurrent anterior glenohumeral instability following initial traumatic anterior dislocation.

Detachment of the antero-inferior labrum (the Bankart lesion) facilitates recurrent anterior instability. The socket-deepening effect of the glenoid labrum has been proved to be an important factor in maintaining stability.^{14,15}

Reattaching the labrum onto the articular surface restores its socket-deepening bumper effect. This is accomplished using sutures and suture anchors, which can be done either open or arthroscopically.^{15,16} Capsular laxity is the other reason for glenohumeral instability. Lack of diagnosing and treating variable capsular laxity accompanying Bankart lesions may cause failure of repair.^{17,18} For a perfect shoulder instability repair result, all the facts causing instability must be understood and treated appropriately.

Historically, arthroscopic repair for the treatment of the Bankart lesion had been less satisfactory than the open technique.⁵ Arthroscopic techniques described are using transglenoid sutures or bio-absorbable tacks.¹⁹

Open method of Bankart repair has several limiting factors, which renders it a less favorable option. It causes an increased blood loss during

surgery, a prolonged period of stay in the hospital and a significant loss of range of motion. In the classic open Bankart repair there is disruption of the subscapularis tendon, which may result in postoperative subscapularis insufficiency;²⁰ in addition, there have been reported cases of postoperative subscapularis tendon rupture.^{20,21} The arthroscopic Bankart repair offers minimally invasive approach with less surgical trauma and blood loss, with improvements in operating time, perioperative morbidity, narcotic use, hospital stay, time loss from work, and decrease number of complications together with a lower cost of surgery.²²⁻²⁴ Postoperative recovery and rehabilitation is faster than open surgical techniques. Postoperative range of motion is also not sacrificed for the sake of stability. Patients are able to have a good range of motion functionally, especially external rotation, which allows them to return to their sports or high-demand jobs.²⁵⁻²⁷ We have also shown that postoperative range of motion is not sacrificed for the sake of stability.

Gartsman *et al.* performed arthroscopic Bankart repair, capsular plication, and if necessary thermal capsuloraphy in 53 patients with antero-inferior shoulder instability. After 2 years followup good and excellent results were 92%, and 7.5% of them had recurrence.²⁷ Mishra and Fanton reported a failure rate of 7% with arthroscopic Bankart repair combined with thermal treatment.³⁵ Sedek *et al.* reached at a 92.5% successful rate after arthroscopic treatment of 40 shoulders. In our study there is no reoccurrence and failure.

In a prospective study by Karlsson *et al.* comparing arthroscopic and open methods, after a

mean duration of 28 months, external rotation was 80° in open group and 90° in arthroscopic group postoperatively.³⁶ Gartsman *et al.*²⁶ and Synder *et al.*³⁷ both reported a 5° degree decrease in external rotation and Kim *et al.*²⁴ reported 4° in their series. Similarly external rotation improved in 85% of our patients postoperatively.

This study has some limitations. Full details of the events in the postoperative period and the period of supervised physiotherapy were not always available. The study population was small and also the study did not take up any comparison between the open and the arthroscopic procedure.

CONCLUSION

We conclude that Arthroscopic Bankart repair with caspari technique in recurrent anterior shoulder dislocation is a reliable and cost effective procedure with respect to shoulder function, recurrence rate and range of movement.

Conflict of interest

None of the authors has any conflict of interest.

Acknowledgements

The authors did not receive any funds for the preparation of this manuscript.

REFERENCES

1. Erkoçak ÖF, Yel M. The functional results of arthroscopic bankart repair with knotless anchors for anterior glenohumeral instability. *Eur J Gen Med.* 2010;7:179–86.
2. Bankart AS. Recurrent or habitual dislocation of the shoulder. *BMJ.* 1920; 1:1132–3.
3. Sedeek SM, Tey IK, Tan AH. Arthroscopic bankart repair for traumatic anterior shoulder instability with the use of suture anchors. 2008;49:676-81. *Singapore Med J.* 2008;49:676–81.
4. Sperling JW, Smith AM, Cofield RH, Barnes S. Patient perceptions of open and arthroscopic shoulder surgery. *Arthroscopy.* 2007;23:361–6.
5. Fabbriani C, Milano G, Demontis A, Fadda S, Ziranu F, Mulas PD. Arthroscopic versus open treatment of Bankart lesion of the shoulder: A prospective randomized study. *Arthroscopy.* 2004;20:456–62.
6. Ee GW, Mohamed S, Tan AH. Long term results of arthroscopic bankart repair for traumatic anterior shoulder instability. *J OrthopSurg Res.* 2011;6:28.
7. Amstutz HC, Sew Hoy AL, Clarke IC. UCLA anatomic total shoulder arthroplasty. *Clin OrthopRelat Res.* 1981; 155:7–20.
8. Ellman H, Hanker G, Bayer M. Repair of rotator cuff. End-result study of factors influencing reconstruction. *J Bone Joint Surg Am.* 1986;68:1113–44.
9. Ellman H. Arthroscopic subacromial decompression: Analysis of one- to three-year results. *Arthroscopy.* 1987;3:173–81.

10. Baumgarten KM, Wright RW. Ease of tying arthroscopic knots. *J Shoulder Elbow Surg.* 2007;14:438–42.
11. Baker CL, Uribe JN, Whitman C. Arthroscopic evaluation of acute initial anterior shoulder dislocation. *Am J Sports Med.* 1990;18:25–8.
12. Liu SH, Henry MH. Anterior shoulder instability. Current review. *ClinOrthop.* 1996;323:327–37.
13. Rowe CR, Zarins B. Recurrent transient subluxation of the shoulder. *J Bone Joint Surg.* 1981;63A:863–72.
14. Cooper DE, Arnoczky SP, O'Brien SJ, Warren RF, DiCarlo E, Allen AA. Anatomy histology and vascularity of the glenoid labrum. *J Bone Joint Surgery Am.* 1992;74:46–51.
15. Lippitt SB, Vanderhooft JE, Harris SL, Sidles JA, Harryman DT, 2nd, Matsen FA., 3rd Glenohumeral stability from concavity compression: A quantitative analysis. *J Shoulder Elbow Surg.* 1993;2:27–35.
16. Kirkley A, Griffin S, Richards C, Miniaci A, Mohtadi N. Prospective randomized clinical trial comparing the effectiveness of immediate arthroscopic stabilization versus immobilization and rehabilitation in first traumatic anterior dislocation of the shoulder. *Arthroscopy.* 1999;15:507–14.
17. Levine WN, Arroyo JS, Pollock RG, Flatow EL, Bigliani LU. Open revision stabilization surgery for recurrent anterior glenohumeral instability. *Am J Sports Med.* 2000;28:156–60.
18. Zabinski SJ, Callaway GH, Cohen S, Warren RF. Revision shoulder stabilization: 2 to 10 year results. *J Shoulder Elbow Surg.* 1999;8:58–65.
19. Freedman KB, Smith AP, Romeo AA, Cole BJ, Bach BR., Jr Open bankart repair versus arthroscopic repair with transglenoid sutures or bioabsorbable tacks for recurrent anterior instability of the shoulder. *Am J Sports Med.* 2004;32:1520–7.
20. Scheibel M, Tsynman A, Magosch P, Schroeder RJ, Habermeyer P. Postoperative subscapularis muscle insufficiency after primary and revision open shoulder stabilization. *Am J Sports Med.* 2006;34:1586–93.
21. Bottoni CR, Smith EL, Berkowitz MJ, Towle RB, Moore JH. Arthroscopic versus open shoulder stabilization for recurrent anterior instability. *Am J Sports Med.* 2006;34:1730–7.
22. Wang C, Ghalambor N, Zarins B, Warner JJ. Arthroscopic versus open bankart repair: Analysis of patient subjective outcome and cost arthroscopy. *Arthroscopy.* 2005;21:1219–22.
23. O'Neill BD. Arthroscopic Bankart repair of anterior detachments of the glenoid labrum. A prospective study. *Arthroscopy.* 2002;18:755–63.
24. Kim SH, Ha KI, Cho YB, Ryu BD, Oh I. Arthroscopic anterior stabilization of the

- shoulder: Two to six year followup. *J Bone Joint Surg Am.* 2003;85:1511–8.
25. McIntyre LF, Caspari RB, Savoie FH., 3rd
The arthroscopic treatment of multidirectional shoulder instability: Two-year results of a multiple suture anchor. *Arthroscopy.* 1997;13:418–25.
26. Savoie FH, 3rd, Miller CD, Field LD.
Arthroscopic reconstruction of traumatic anterior instability of the shoulder. The Caspari technique. *Arthroscopy.* 1997; 13:201–9.
27. Gartsman GM, Roddey TS, Hammerman SM. Arthroscopic treatment of anterior-inferior glenohumeral instability. Two to five-year followup. *J Bone Joint Surg Am.* 2000;82:991–1003.
28. Plancher KD, Lipnick SL. Analysis of evidence-based medicine for shoulder instability, arthroscopy. *Arthroscopy.* 2009;25:897–908.
29. Wright RW, Baumgarten KM. Shoulder outcomes measures. *J Am Acad Orthop Surg.* 2010;18:436–44.
30. Godfrey J, Hamman R, Lowenstein S, Briggs K, Kocher M. Reliability, validity, and responsiveness of the simple shoulder test: Psychometric properties by age and injury type. *J Shoulder Singapore Med J.* 2008;49:681.
31. Mahmoud TA El-Aziz, Moinstafa MS, Sokker SM, El-Adawy M. Evaluation of the functional results of management of traumatic anterior glenohumeral instability by arthroscopic capsular shift using suture anchors. *Suez Canal Univ Med J.* 2008;11:103–14.
32. Barber FA. Arthroscopic management of shoulder instability: Bio anchor. In: Chow James CY, editor. *Advanced Arthroscopy.* New York: Springer; 2001. pp. 73–80.
33. Nho SJ, Provencher MT, Seroyer ST, Romeo AA. Bioabsorbable anchors in glenohumeral shoulder surgery. *Arthroscopy.* 2009;25:788–93.
34. Cole BJ, Provencher MT. Safety profile of bioabsorbable shoulder anchors. *Arthroscopy.* 2007;23:912–3.
35. Mishra DK, Fanton GS. Two-years outcome of arthroscopic Bankart repair and electrothermal-assisted capsulorrhaphy for recurrent traumatic anterior shoulder instability. *Arthroscopy.* 2001;17:844–9.
36. Karlsson J, Magnusson L, Ejerhed L, Hultenheim I, Lundin O, Kartus J. Comparison of open and arthroscopic stabilization for recurrent shoulder dislocation in patients with a bankart lesion. *Am J Sports Med.* 2001;29:538–42.
37. Synder SJ, Banas MP, Belzer JP. Arthroscopic treatment of anterior shoulder instability using threaded suture anchors and nonabsorbable sutures. *Instr Course Lect.* 1996;45:71–81.