



## Avulsion Fracture of Anterior Superior Iliac Spine with Meralgia Paraesthetica: A Case Report

Authors

**Dr. Vinay Kumar Akka<sup>1</sup>, Dr. Mishil S. Parikh<sup>2</sup>, Dr. Sunil H. Shetty<sup>3</sup>**

<sup>1</sup>Junior Resident, Department of Orthopaedics, D Y Patil School of Medicine, Navi Mumbai  
Email: [Vinay3433@gmail.com](mailto:Vinay3433@gmail.com)

<sup>2</sup>Senior Resident, Department of Orthopaedics, D Y Patil School of Medicine, Navi Mumbai  
Email: [Mishil7@gmail.com](mailto:Mishil7@gmail.com)

<sup>3</sup>Prof. & Head, Department of Orthopaedics, D Y Patil School of Medicine, Navi Mumbai  
Email: [Dr\\_sunilshetty@yahoo.co.in](mailto:Dr_sunilshetty@yahoo.co.in)

### Abstract

*Avulsion fracture of the anterior superior iliac spine is a rare entity which may or may not be associated with meralgia paraesthetica. It is commonly seen in the adolescent age group. Avulsion fractures results due to sudden or repetitive contraction or pull by the muscle or tendon attached to the bone. Treatment is mainly conservative depending on the displacement of the fragment, depending on the displacement surgery may be required. We present a 18 yr old boy with acute post traumatic avulsion fracture of anterior superior iliac spine with meralgia paraesthetica treated conservatively with a pelvic brace.*

**Key words:** *Meralgia Paraesthetica, ASIS Avulsion Fracture, Conservative Management*

### Introduction

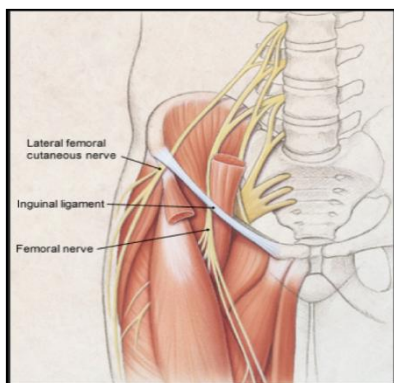
Avulsion fracture of the anterior superior iliac spine are a rare type of injury occurring as a result of sudden forceful contraction or due to repetitive pull by the muscle or tendon attached to it.

Anterior superior iliac spine which arises from the anterior apophysis of the iliac crest gives origin site for the Sartorius muscle and part of the tensor fasciae latae. Contraction or sudden pull of these

muscles which lead to the avulsion fracture of the anterior superior iliac spine.<sup>6,7</sup>

Avulsion fracture have also been reported following apophysitis.<sup>2</sup> Associated loss of sensation over the antero lateral aspect of the thigh have been reported in few cases because of close proximity of lateral femoral cutaneous nerve to the anterior superior iliac spine<sup>1</sup>. (Fig. 1)

We present a case of an 18 year old soccer player with sensory loss over the lateral aspect of the thigh following injury which was treated conservatively.



**Figure 1 :** Antomy of Lateral Cutaneous Femoral Nerve

### Case report

A 18 year old boy came to us with 5 day old pain around the right anterior superior iliac spine and pain and hyposthesia over the right antero lateral aspect of the thigh following a history of sudden twisting injury (external rotaion of the hip) while playing soccer. His presenting complaints were severe pain while walking and associated limp. On examination patient had localised tenderness over the right anterior superior iliac spine with painful movements of the ipsilateral hip joint, patient also had sensory loss (hyposthesia) over the antero lateral aspect of the right mid thigh region. Tinel's sign was positive on tapping the avulsed bony fragment.

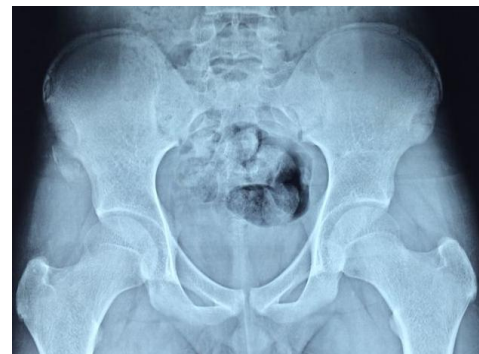Following the patients presentation we conducted the undermined investigations :

1. Plain radiograph of the Pelvis which showed the avulsion fracture of the right ASIS.(Figure 2)

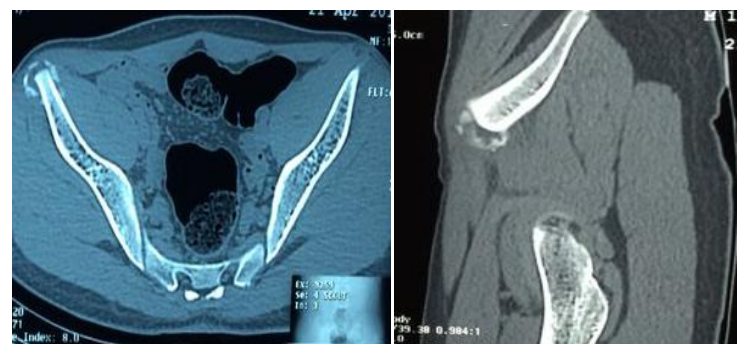2. We further investigated him with CT Scan to look for the displacement.(Figure 3)
3. Finally we conducted an EMG / NCS study to check for the nerve conduction.Which came out to be Normal.

After the thorough investigations we concluded that the nerve wasn't entrapped and there was no displacement of the fragment more than 3 mm. Hence we decided to manage the patient conservatively in the form of rest, analgesics ,anti-inflammatories and pelvic brace in the form of pelvic binder.

After 6 weeks the hyosthesia had disappeared and the pateint was advised weight bearing and hip range of motion exercises. At weeks the patient was back to playing soccer with no functional deficit.



**Figure 2:** Plain radiograph of pelvis with both hip showing Right ASIS Avulsion fracture



**Figure 3:** CT Scan

## Discussion

Avulsion fractures of the anterior superior iliac spine are a rare entity and are found commonly in young patients involving vigorous activity. More common in boys than, girls due to the activity levels. This injury usually occurs as a result of sudden, vigorous or repetitive contraction of the sartorius muscle and tensor fasciae latae.<sup>2,3</sup>

Meralgia paraesthetica due to the stretch of lateral femoral cutaneous nerve may be an associated sign with the ASIS avulsion fractures.<sup>1</sup>

Diagnosis of ASIS avulsion fracture is done by complete history, the nature of injury or the activity during injury with clinical radiographs of pelvis with both hip, CT scans ,MRI imaging and EMG/NCS studies can be conducted to rule out any nerve injury in case of meralgia paraesthetica.<sup>8</sup>

If the nerve is entrapped, surgery is the only option. The nerve should be freed and open reduction with internal fixation with screws should be done to fix the avulsion and treat the hyothesia.<sup>4,5</sup>

In an undisplaced fracture with normal EMG/NCS, treatment usually involves conservative in the form of rest, analgesics, anti inflammatories and pelvic braces. surgical management is indicated in case of displacement of the fragment of more than 3cms.

## References

1. Buch K, Campbell J. Acute onset meralgia paraesthetica after fracture of the anterior superior iliac spine. *Injury*1993;24:569–70.

2. Lambert MJ, Fligner DJF. Avulsion of the iliac crest apophysis: a rare fracture in adolescent athletes. *Ann Emerg Med*1993; 22:1218–20.
3. Thanikachalam M, Petros JG, O'Donnell S. Avulsion fracture of the anterior superior iliac spine presenting as acute-onset meralgia paraesthetica. *Ann Emerg Med*1995;27:515–17.
4. Rosenberg N, Noiman M, Edelson G. Avulsion fractures of the anterior superior iliac spine in adolescents. *J Orthop Trauma*1996;10:440–3.
5. H Pointinger, P Munk, G P Poeschl. Avulsion fracture of the anterior superior iliac spine following apophysitis *Br J Sports Med* 2003;37:361-362 doi:10.1136/bjism.37.4.361
6. White KK, Williams SK, Mubarak SJ. Definition of two types of anterior superior iliac spine avulsion fractures. *J Pediatr Orthop*. 2002;22:578–582. doi: 10.1097/00004694-200209000-00003.
7. Tuzuner T, Ozturan KE, Karaca E, Ulgur M (2003) Avulsion fracture of the anterior superior iliac spine in a volleyball player. *Acta Orthop Traumatolog* 37:340–343
8. B. S. Dhinsa, Azal Jalgaonkar, Bhupinder Mann, Sajid Butt, and Rob Pollock: Avulsion fracture of the anterior superior iliac spine: misdiagnosis of a bone tumour. *J Orthop Traumatol*. Sep 2011; 12(3): 173–176