



## Is Surgical Exposure of Scapula Through Direct Lateral Approach Preferable ?

Authors

**Dr. Dibakar Ray<sup>1</sup>, Dr. Ashoke Kumar Chanda<sup>2</sup>, Dr. Somnath Trikey<sup>3</sup>, Dr. Asik Iqbal<sup>4</sup>,  
Dr. Wriddik Porel<sup>5</sup>, Dr. P.K. Mandal<sup>6</sup>**

<sup>1</sup>Associate Professor, BSMCH

<sup>2</sup>Clinical Tutor, C.N.M.C.H

<sup>3</sup>Senior Resident, BSMCH

<sup>4,5</sup>Junior Resident, BSMCH

<sup>6</sup>Associate Professor, BSMCH

### Abstract

*Fractures of the scapula are very uncommon (account for 3% to 5% of all fractures about the shoulder) and most of the scapula fractures do well with conservative treatment<sup>[1]</sup>. Operative treatment of scapula fractures is indicated for significantly displaced fractures or intra-articular fractures. There are several surgical approaches for exposure of scapula. In this article we are discussing about direct lateral approach and its advantages and disadvantages. This approach ensures adequate exposure of scapula for internal fixation. It causes minimal trauma to soft tissue. It ensures protection of the major neurologic structures i.e. suprascapular nerve superior and axillary nerve laterally. This approach has minimum chance injury to axillary artery as there is no subperiosteal dissection of deltoid.*

*The main advantage of the exposure is minimum soft tissue dissection, which can potentially improve rehabilitation and limit morbidity of the operation.*

**Key Words:** *scapula, fracture, approach, fixation*

### INTRODUCTION

Fractures of the scapula account for 3% to 5% of all fractures about the shoulder, are most often caused by high-energy trauma, and are frequently associated with multiple trauma (approximately

90% of patients with scapular fractures have associated injuries)<sup>[1]</sup>. Treatment of scapular fractures has traditionally been described as “benign neglect” and, like clavicular fractures, most scapular fractures do well with conservative

management<sup>[2]</sup>. Although outcomes are generally good, not all scapular fractures heal uneventfully and there has been a resurgence of interest in determining which patients would benefit from operative treatment. In their systematic review of the literature concerning scapular fractures, Zlowodzki et al. found that of the total 520 fractures reported, 82% had good-to-excellent functional results<sup>[3]</sup>. Almost all scapular body fractures were treated non operatively, with 86% good-to-excellent results; scapular neck and isolated glenoid fractures were most often treated operatively (83%), with good-to-excellent results in 76% and 82%, respectively. Although the numbers of specific fractures were small, the overall results after operative treatment were better than those after non operative treatment in all types.

Lantry et al. also reported a systematic review of operative treatment of scapular fractures in which good-to-excellent functional results were found in approximately 85% of patients<sup>[4]</sup>. Although the literature is still lacking in sufficient evidence to formulate concrete treatment guidelines, these two reviews emphasize that most scapular fractures do well, but criteria for deciding which fractures are at risk for poor outcomes are still evolving.

Cole et al. listed several criteria for operative treatment<sup>[5]</sup> of scapular fractures:

- A 2-cm lateral border offset (lateralization)
- Forty-five degrees of scapular body angulation, as measured on a scapular-Y view
- Glenopolar angle of 22 degrees or less  
[This angle is formed by a line drawn from

the inferior pole of the glenoid fossa up to the superior pole and a second line drawn from the superior pole of the glenoid fossa down through the inferiormost angle of the scapular body. The normal glenopolar angle ranges from 30 to 45 degrees.]

- Scapular body fracture with injury to the clavicle or clavicle-acromion complex.

### **SURGICAL EXPOSURES FOR SCAPULA: MODIFIED JUDET APPROACH**

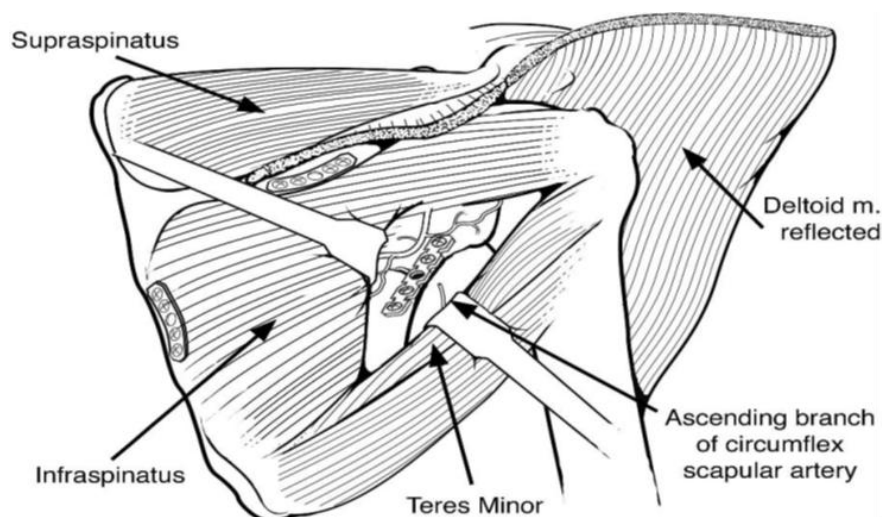
One of the most common and practical surgical approaches to the scapula is the posterior (Judet) approach, which involves dissection of the infraspinatus muscle from the infraspinatus fossa to facilitate fracture reduction and fixation.

The patient is placed in a prone position with the ipsilateral arm draped free and a small bump under the anterior chest.

The extensile skin incision as described by Judet is based on the subcutaneous border of the scapular spine and angled sharply at the superomedial angle of the scapula and follows the medial border inferiorly to the inferior angle. Sharp dissection to the fascia is performed. A large skin flap and associated subcutaneous fat is elevated off the fascia, exposing the infraspinatus, teres minor, teres major, and posterior deltoid muscles of the scapula. Scissor dissection with a curved Mayo in the areolar tissue plane facilitates this exposure better than electrocautery. Bleeding of fascial perforators is controlled with electrocautery. The skin flap then is extended laterally beyond the lateral scapular border. The superomedial border of the latissimus is

encountered inferiorly. The plane between the posterior deltoid and the infraspinatus should be developed using blunt dissection. The fascia of the posterior deltoid is then dissected off of the spine of the scapula, releasing the origin of the posterior deltoid. The posterior deltoid origin with the overlying fascia is tagged and retracted

superolaterally. Laterally, the plane between the teres minor and infraspinatus is developed and allows exposure of the ascending branch of the circumflex scapular artery, which is ligated. If this vessel is inadvertently cut, it may be a source of rapid bleeding, and vascular clips should be readily available.



Infraspinatus and teres minor interval dissection and fracture exposure and fixation.

Careful retraction of the lateral portion of the teres minor and infraspinatus muscles allows exposure of the lateral border of the scapula. From this position, mobilization and reduction of the fragments may indirectly reduce a fracture of the glenoid surface and the glenoid neck.

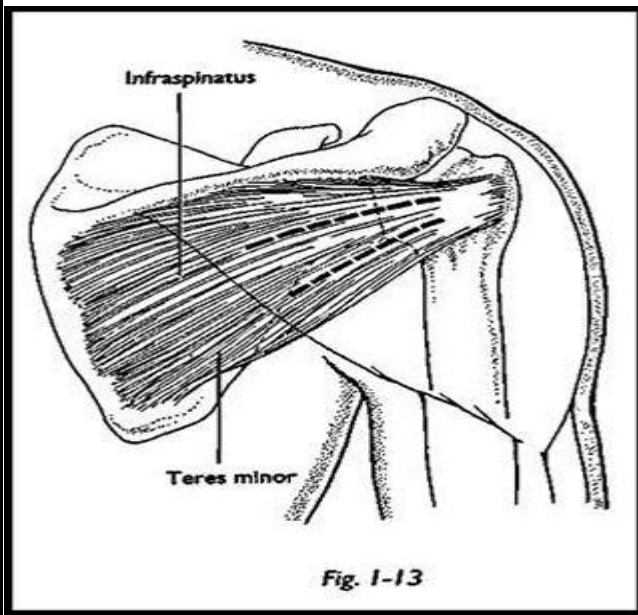
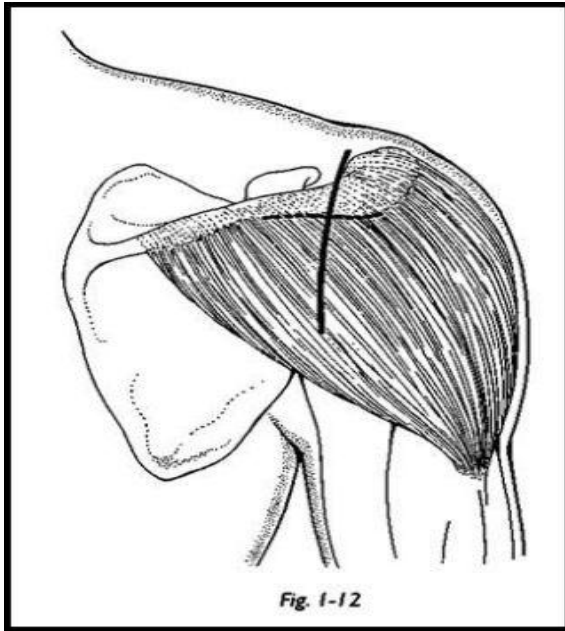
### **DIRECT LATERAL APPROACH**

Hardegger et al <sup>[12]</sup> and Kavanagh et al <sup>[13]</sup> used a vertical incision from the acromion to the inferior scapular angle. We have modified this approach.

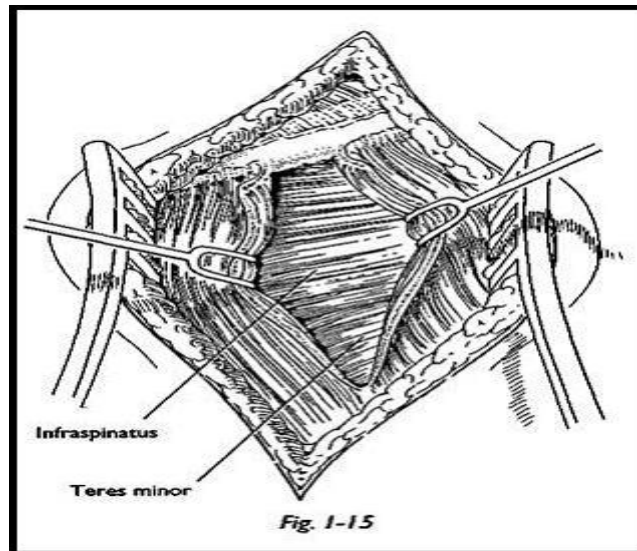
The patient is placed in a prone position with the ipsilateral arm draped free and a small bump under the anterior chest.

In this approach a vertical incision is given along the lateral border of scapula starting from

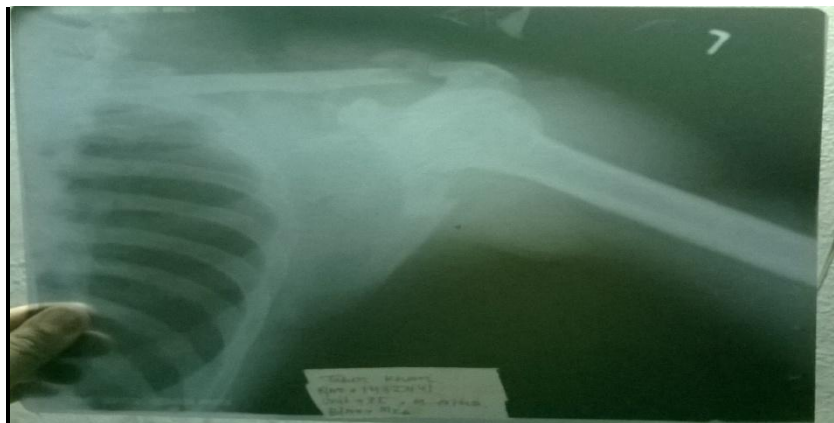acromion. After a vertical skin incision, the inferior border of the spinal part of the deltoid is identified and mobilized by blunt dissection. The interval between the infraspinatus and teres minor muscles is entered with the infraspinatus muscle retracted cranially and the teres minor muscle laterally. This avoids any injury to the suprascapular nerve supplying the infraspinatus muscle as well as to the axillary nerve supplying the teres minor muscle. The lateral border of the scapula and the glenoid joint are then displayed, with the possibility of open reduction and internal fixation of scapular neck fractures and posterior glenoid fractures.



Incision line

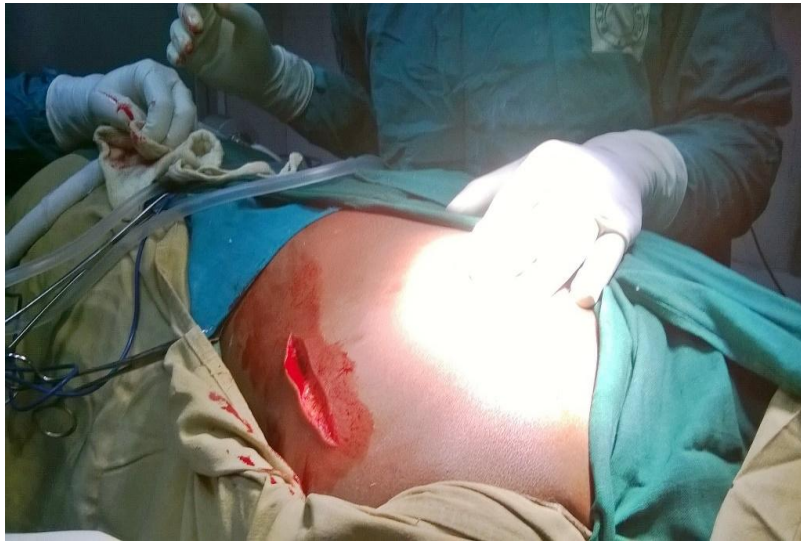

internervous plane between teres minor [supplied by axillary nerve] and infraspinatus [supplied by suprascapular nerve].

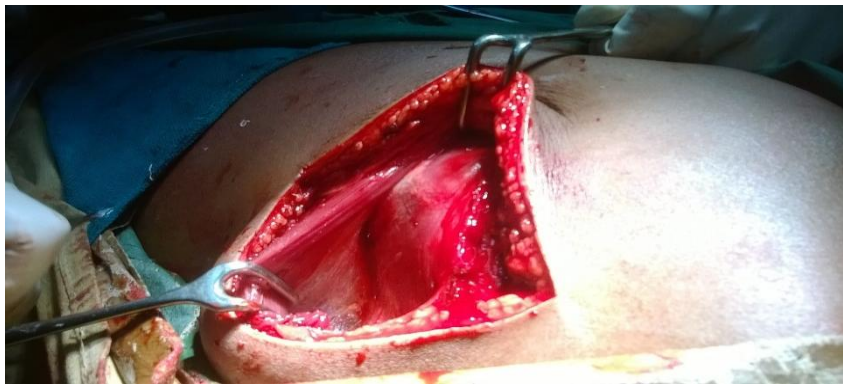

x-ray showing fracture scapula .

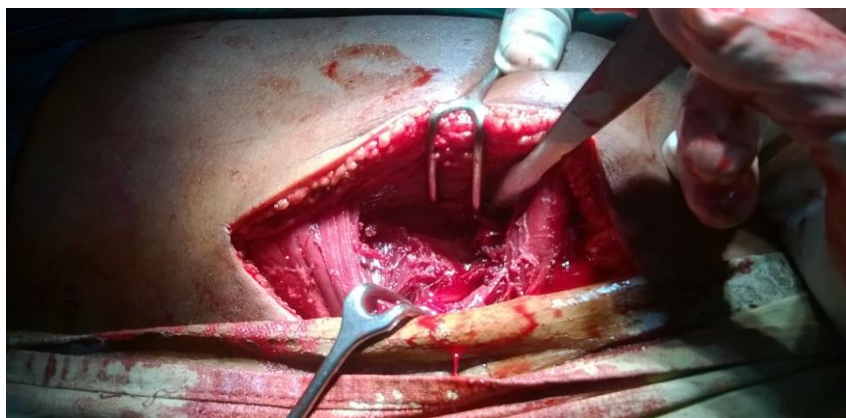



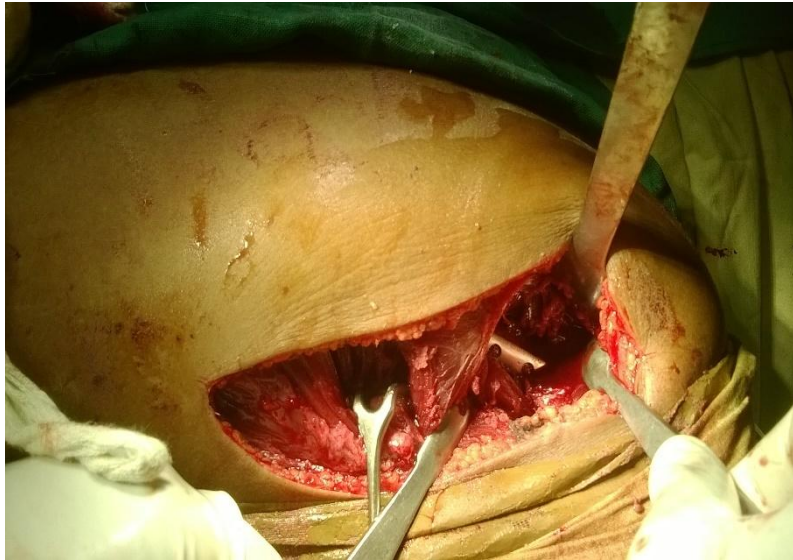
Incision



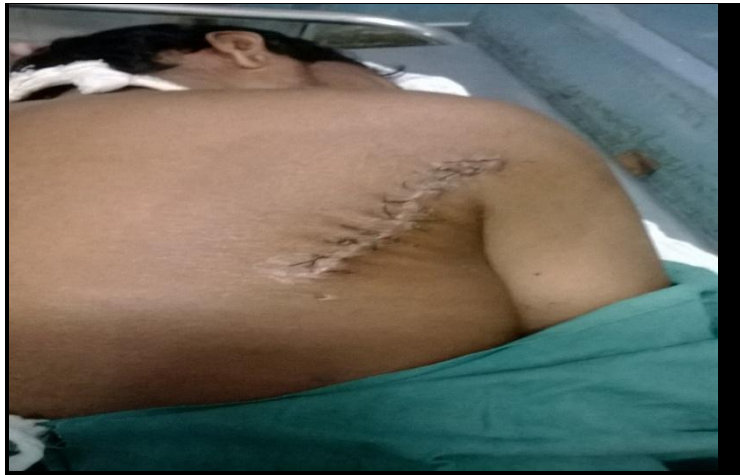Deep fascia dissection



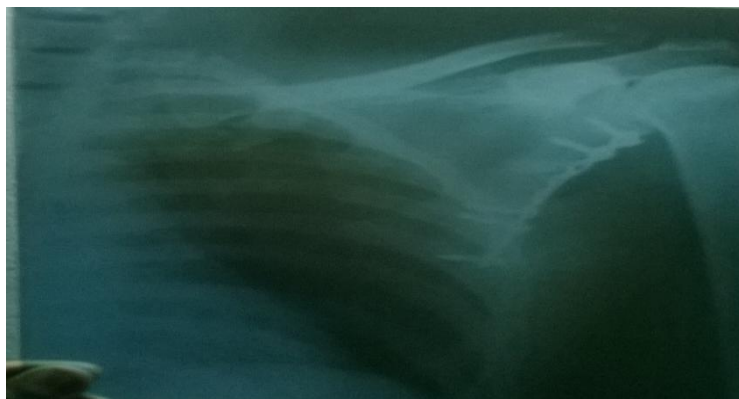Internervous plane



fracture fixation



On 10 th post op day



post operative x- ray

## DISCUSSION

Fractures of the scapula occur infrequently and are most commonly associated with high-energy trauma. The majority of scapula fractures can be treated nonoperatively<sup>[6, 7,8]</sup> Ten percent to 44% of scapula fractures involve the glenoid and scapular neck<sup>[9,10,11]</sup> Associated thoracic and vascular injuries are infrequent but should not be overlooked. Debate remains regarding the best treatment of intraarticular and significantly displaced scapula fractures. Although some authors have reported good results following non operative treatment, other authors have reported less than uniformly favorable outcomes. Goals of surgical management of these injuries should include prevention of degenerative joint disease, pain, and instability. Hardegger<sup>[12]</sup> et al reported 79% good to excellent results at an average of 6.5 years with internal fixation of intra-articular fractures or fractures that had glenohumeral or neck instability.

The Judet approach has been the standard approach for the operative treatment of scapular fractures. In modified Judet approach the infraspinatus muscle is not dissected out of the scapular fossa. This modified approach has all the advantages of the classic approach with visualization of all fracture patterns and fracture lines as well as the ability to address intra-articular and glenoid fractures without the morbidity of the extensive dissection. Potential complications would be bleeding, seroma, or nerve injury. Excessive bleeding from the ascending branch of the circumflex scapular artery is usually present at the inferior edge of a glenoid

neck fracture. A postoperative seroma can also develop due to the large subcutaneous flap. There is also increase chance of injury of axillary nerve and vessel especially during subperiosteal dissection of deltoid.

In direct lateral approach we have exposed the scapula with very minimum soft tissue dissection.

This approach has the advantage of

1. Minimum chance of axillary and suprascapular nerve injury as in this approach we use an internervous plane for the exposure of scapula [axillary nerve supplying teres minor and suprascapular nerve supplying infraspinatus].
2. Minimum chance injury to axillary artery as there is no subperiosteal dissection of deltoid.
3. Minimum chance of seroma as no large subcutaneous flap is formed.
4. Early post operative rehabilitation can be done as minimum injury to deltoid and rotator cuff musculature.
5. Easy learning curve.

However, the posterior deltoid cannot be freed or released from this approach and this could make visualization of intra-articular fracture difficult. Additionally, one would not have access to the entire scapular spine and medial scapula for fixation of bony fractures.

## CONCLUSION

With the advantage of minimum soft tissue dissection, minimum chance of neurovascular injury and early post operative rehabilitation we can use direct lateral approach for surgical exposure

and fracture fixation of scapula specially for scapular lateral border fractures, posterior glenoid fractures and scapular neck fractures .

## REFERENCES

1. Ideberg R, Grevsten S, Larsson S. Epidemiology of scapular fractures. Incidence and classification of 338 fractures. *ActaOrthop Scand.* 1995; 66:395–397.
2. Bozkurt M, Can F, Kridemir V, et al: Conservative treatment of scapular neckfracture: the effect of stability and glenopolar angle on clinical outcome, *Injury* 36:1176, 2005.
3. Zlowodzki M, Bhandari M, Zelle BA, et al: Treatment of scapula fractures: systematic review of 520 fractures in 22 case series, *J Orthop Trauma* 20:230, 2006.
4. Lantry JM, Roberts CS, Giannoudis PV: Operative treatment of scapular fractures: a systematic review, *Injury* 39:271, 2008.
5. Cole PA, Gauger EM, Schroder LK: Management of scapular fractures, *J Am AcadOrthoSurg* 20:130, 2012.
6. Nordqvist A, Petersson C. Fracture of the body, neck, or spine of the scapula. A long-term follow-up study. *ClinOrthop.* 1992:139–144.
7. Edwards SG, Whittle AP, Wood GW 2nd. Nonoperative treatment of ipsilateral fractures of the scapula and clavicle. *J Bone Joint Surg Am.* 2000; 82:774–780.
8. Egol KA, Connor PM, Karunakar MA, et al. The floating shoulder: clinical and functional results. *J Bone Joint Surg Am.* 2001;83A:1188–1194.
9. Goss TP. Scapular fractures and dislocations: diagnosis and treatment. *J Am AcadOrthop Surg.* 1995;3:22–33.
10. Scavenius M, Sloth C. Fractures of the scapula. *ActaOrthop Belg.* 1996;62:129–132.
11. Goss TP. Fractures of the glenoid cavity. *J Bone Joint Surg Am.* 1992;74: 299–305.
12. Hardegger FH, Simpson LA, Weber BG. The operative treatment of scapular fractures. *J Bone Joint Surg Br.* 1984;66:725–731.
13. Kavanagh BF, Bradway JK, Cofield RH. Open reduction and internal fixation of displaced intra-articular fractures of the glenoid fossa. *J Bone Joint Surg Am.* 1993;75:479–484.