



## Incidence and Management of Ocular Complications/Manifestations in Leprosy Patients Who Are Attending To a Tertiary Care Hospital

Authors

**Dr. R. Sudha<sup>1</sup>, Dr. N. Suneel<sup>2</sup>, Dr. O. Gopala Krishna<sup>3</sup>, Dr. G.Chandrasekhar<sup>4</sup>**

<sup>1,2,3,4</sup> Dept of Ophthalmology, Narayana Medical College & Hospitals, Nellore

Corresponding Author

**Dr. R. Sudha**

Asst. Professor, Dept of Ophthalmology, Narayana Medical College & Hospitals, Nellore

Email: [research.nmch@rediffmail.com](mailto:research.nmch@rediffmail.com)

### ABSTRACT

*A prospective and descriptive study on ocular manifestations of leprosy and its management was conducted at Department of ophthalmology, Narayana Medical College & Hospital, Nellore, Andhra Pradesh. This study was conducted with 46 leprosy patients with ocular manifestations were analyzed. The ocular manifestations were predominantly (91.66%) seen after treatment. Ocular involvement is bilateral in greater number (79.16%) of cases except in some cases (lagophthalmos, scleritis, episcleritis), where unilateral involvement is more common. Madrosis is the most common adnexal manifestation observed. Lagophthalmos is most common sight threatening adnexal condition. Decreased corneal sensations are observed in (45.83%) nearly half of cases. Exposure keratitis is most common (20.83%) corneal condition. Acute and chronic anterior uveitis are seen equally, which are granulomatous uveitis in all cases. Corneal involvement is seen in 29.16% of patients. Uveal involvement is seen in 20.83% of patients. Majority of the patients had normal fundus. At the time first presentation, most of the cases (62.50%) are having normal vision according to WHO gradings. 70% of various ocular inflammations are responded well to medical treatment. 33.33% of cases came for no follow up .45.83% of cases came for 1 -2 follow ups. Only 20.83% of cases came for 3 -5 follow ups. Treatment response was considered in patients who came for at least 3 follow ups.*

## INTRODUCTION

Hansen's disease is a chronic granulomatous infectious disease caused by *Mycobacterium leprae*. It affects mainly the peripheral nerves but it can also affect skin, muscles, eyes, bones, testes and internal organs<sup>(1)</sup>. The skin lesions and deformities were historically responsible for the stigma attached to the disease. The introduction of MDT in the early 1980s has started to have an impact on the transmission of the disease and the severity of its attending complications. The year 2012-13 started with 0.83 lakh leprosy cases on record as on 1st April 2012, with PR 0.68/10,000, Annual New Case Detection Rate (ANCDR) of 10.78 per 100,000 populations (78). Eye involvement in leprosy is quite common and its complications, particularly potentially sight threatening lesions, if neglected, will lead to blindness<sup>(2)</sup>. Good vision is required not only for the performance of routine activities but also for the care of anaesthetic hands and feet. Loss of eyesight in a person who already have anaesthesia in hands and feet is a disaster<sup>(3)</sup>. The ocular lesions in leprosy can give rise to symptoms and disability ranging from chronic irritation of eyes upto blindness<sup>(4)</sup>. The incidence of eye involvement in leprosy is stated to be anywhere from 15% (tuberculoid) to 100% in long standing lepromatous leprosy<sup>(5)</sup>.

Ocular involvement has been seen even in patient who have completed the MDT. Every year, approximately 5.6% of patients with MB leprosy, who have completed MDT can be expected to develop new ocular complications of leprosy, which often (3.9%) are potentially vision

threatening<sup>(6)</sup>. Similarly complications can occur during MDT therapy and during relapse of the disease.

A worldwide study on ocular complications of leprosy has revealed blindness caused by leprosy in 3.2% and grade 2 visual disability in 7.1% of the sample analyzed<sup>(7)</sup>.

The ocular adenexa and the anterior segment of the eye offer an ideal site for *M.leprae* to proliferate. The cooler temperatures, the presence of a rich neurovascular network and the possibility of ocular immunologic compartmentalization may all be incriminated as contributing to ocular complication during leprosy<sup>(7)</sup>. Ocular complications are seen in 1/3 rd of leprosy patients. For simplicity, ocular lesions can be classified into two groups. The first group includes potentially sight threatening lesions and the second group includes academic lesions. Potentially sight threatening (PST) lesions comprise lagophthalmos and its sequelae, corneal hypo aesthesia and its sequelae, chronic iridocyclitis and its sequelae and scleritis. Academic lesions, such as loss of eyebrows and eyelashes, have no visual significance but contribute to the stigma which these patients endure<sup>(8)</sup>.

## MATERIALS AND METHODS

A prospective and descriptive study on ocular manifestations of leprosy and its management was conducted at Department of ophthalmology, Narayana Medical College & Hospital, Nellore, Andhra Pradesh. This study was conducted from July 2011-August 2013 during which 46 leprosy

patients with ocular manifestations were analyzed. In this study, all the patients with systemic leprosy, who presented to the Department of Dermatology outpatient were referred to the Department of Ophthalmology and screened for ocular manifestations of leprosy. Leprosy patients who are having eye problems are referred from local leprosy hospitals and colonies.

#### **Inclusion Criteria:**

All leprosy patients who attended department of Ophthalmology, Narayana Medical College & Hospital during the period of July 2011 – August 2013.

#### **Exclusion Criteria:**

Patients with comorbid condition like HIV, Tuberculosis were excluded from the study.

#### **Clinical Evaluation**

In all these patients, demographic data like age, sex and place of residence were documented. A details regarding systemic leprosy were obtained from records and history given by patient. Ocular symptoms of leprosy like defective vision, redness, pain, loss of eye lashes, inability to close the eye lids were documented. History of lepra reaction including the number of episodes, time of occurrence in relation to treatment, precipitating factors and treatment taken was also elicited. Treatment history including review of patients' medical records, time of initiation of treatment, type of treatment, duration and compliance was also documented. Based on these details the type of leprosy was determined and documented.

Systemic evaluation was done to assess the skin lesion, neuropathies and deformities. Detailed external ocular examination was done with the

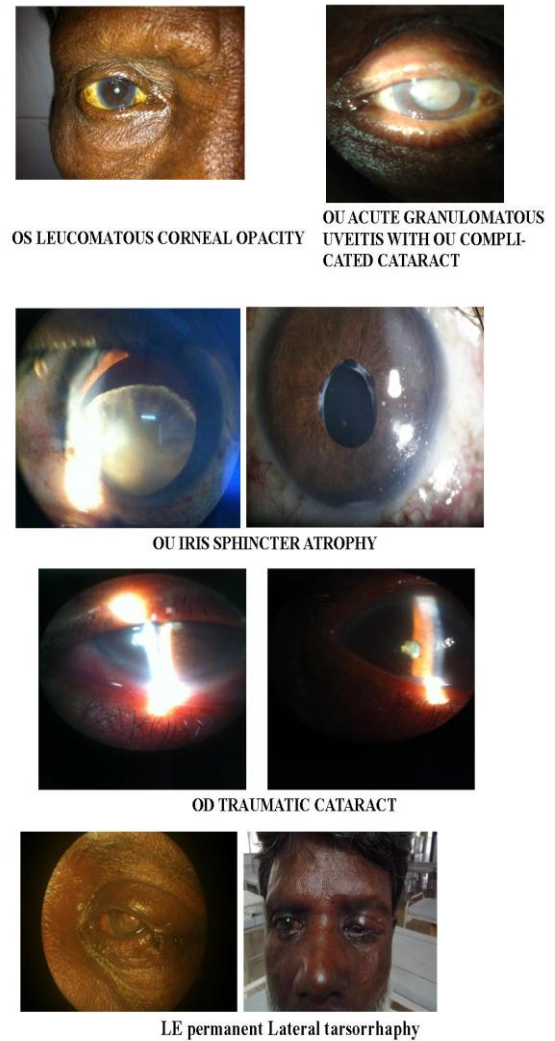
help of a torch light to look for madarosis, lagophthalmos and lid abnormalities like nodules. Detailed anterior segment evaluation was done with slit lamp biomicroscopy to look for episcleritis, scleritis, keratitis, exposure keratopathy, uveitis and cataract. Cataract was classified into senile and complicated cataract. Corneal sensation was tested by asking the patient to look up and applying the tail end of a wisp of cotton on the cornea 2 mm from the limbus at the 6'o clock position and categorizing the sensation as normal if the patient responded by retracting the head or closing the eyelids and impaired if the patient did not.

Dilated posterior segment evaluation was done with slit lamp +90D and indirect ophthalmoscope. Visual acuity (with and without correction) was tested with snellen chart or illiterate E chart at 6 meters distance. Based on this patients were grouped according to WHO classification of visual impairment and blindness.

Intra ocular pressure was recorded in all patients above 40 years of age and in suspected cases below 40 years of age by schiotz tonometer. In selected cases applanaton tonometry was done with Goldmann applanation tonometer. Gonioscopy with Goldmann gonioscopes was done in suspected cases of narrow angles and graded according to Schaffer's classification. Fields were done using Humphrey perimeter in selected cases. All these patients were treated according to the type of ocular involvement. Patient with acute granulomatous or non granulomatous uveitis were treated with topical steroids like 1% prednisolone acetate and mydriatics like homatropine and

atropine. Patients with episcleritis and scleritis were treated with topical steroids like 1% prednisone acetate. Patients with severe or recurrent intra ocular inflammation suspected to be due to active leprosy were started on anti leprosy treatment and systemic steroid after consulting dermatologists. Anti glaucoma medications were started in patients with raised intra ocular pressure and secondary angle closure glaucoma. Patients with cataract underwent cataract extraction with intraocular lens implantation after the ocular inflammation is controlled with topical steroid or systemic steroids. Lateral tarsorrhaphy was done in patients with lagophthalmos with exposure keratopathy. Patients with dacryocystitis underwent dacryocystectomy / dacryocystorhinostomy. Patients were followed over subsequent visits. During each visit BCVA, ocular status were assessed.

At the end of the study period, all the data were analyzed. The pattern of ocular involvement in these patients were analyzed. The correlation between treatment status and ocular involvement was also analyzed. The outcome of the treatment were analyzed for those patients who had at least three follow ups during the study period.



**Figure.1** Ocular Manifestations and Complications of Various Leprosy Patients

## RESULTS

In this study 48 patients, with ocular leprosy were analyzed. Patients demographic characteristics are shown in table 1. Most of these patients were in the 50 to 69 years age group. Majority (79.16%) of these patients were males. Type of leprosy is shown in table 2. Majority (89.58%) of the patients had lepromatous type of leprosy. The four patients who had history of lepra reactions belonged to the lepromatous type of leprosy. The time of occurrence of ocular manifestations in

leprosy is shown in table 3. The ocular manifestations were predominantly (91.66%) seen after treatment. In the lepra reaction positive group, three patients developed ocular symptoms after treatment. Ocular involvement is bilateral in greater number (79.16%) of cases except in some cases (Eg:lagophthalmos, scleritis, episcleritis) , where unilateral involvement is more common .(Table 4)

**Table 1:** Age Distribution

Age Group	No. of Leprosy Patients
30 – 39	1
40 – 49	8
50 – 59	20
60 – 69	16
70 – 79	3
Total	48

**Table 2:** Type of Leprosy

Type of leprosy	No.of leprosy patients	Percentage
Tuberculoid	5	10.41%
Lepromatous	43	89.58%
Total	48	100%

**Table 3:** Time of Occurrence of Ocular Symptoms of Leprosy

Time	No.of Leprosy patients	Percentage
During treatment	4	8.3%
After treatment	44	91.66%
Total	48	100%

**Table 4:** Laterality

Laterality	No.of cases	Percentage
Unilateral	10	20.83%
Bilateral	38	79.16%
Total	48	100%

**Table 5 :** Ocular Adnexal Manifestations

Clinical sign	No.of cases
Madarosis	28 (58.33%)
Lagophthalmos	7 (14.50%)
Chronic dacryocystitis	2 (4.16%)
Ectropion	1 (2.08%)
Trichiasis	1 (2.08%)

Madrosis is the most common adnexal manifestation observed. Lagophthalmos is most common sight threatening adnexal condition.(Table 5)

## OCULAR MANIFESTATIONS

Corneal involvement is seen more commonly than uveal involvement. Decreased corneal sensations are observed in (45.83%) nearly half of cases. Exposure keratitis is most common (20.83%) corneal condition. Acute and chronic anterior uveitis are seen equally, which are granulomatous uveitis in all cases. (Table 6) Corneal involvement is seen in 29.16% of patients. Uveal involvement is seen in 20.83% of patients.(Table 7) Compared to complicated cataract , senile cataract observed more frequently.Among these patients 7 patients underwent SICS with PCIOL implantation under local anaesthesia , all of them got normal vision post operatively.(Table 8) Majority of the patients had normal fundus (Table 9). At the time first presentation, most of the cases (62.50%) are having normal vision according to WHO gradings. 70% of various ocular inflammations are responded well to medical treatment. 33.33% of cases came for no follow up .45.83% of cases came for 1 -2 follow ups. Only 20.83% of cases came for 3 -5 follow ups. Treatment response was



considered in patients who came for at least 3 follow ups.

**Table 6 :** Sclera and cornea :

Clinical sign	No. of cases
Episcleritis	4(8.32%)
Scleritis	1(2.08%)
Decreased corneal sensations	22 (45.83%)
Superficial punctuate keratitis	10(20.83%)
Corneal ulcer	1(2.08%)
Corneal opacity	3(6.25%)

**Table 7 :** UVEA

Clinical sign	No.of cases
Acute anterior uveitis	4 (8.33%)
Chronic anterior uveitis	4 (8.33%)
Iris atrophy	7(14.58%)

**Table 8 :** Cataract

Type of cataract	No.of cases	Percentage
Senile	24	50%
Complicated	6	12.5%
Nil and Pseudophakia	18	37.5%
Total	48	100%

**Table 9 :** Fundus

Clinical sign	No. of cases
Normal	35
No view	13

**Table 10:** Grading Of Visual Impairment

Visual acuity	No. of cases
Normal vision (6/6 - 6/18)	30 (62.5%)
Low vision (6/18 -3/60)	15 (31.25%)
Blindness(3/60 – noPL )	3 (6.25%)

**Table 11:** Ocular inflammations response to treatment

Response	No. of cases
Improved	7
Static	3
Worsen	0

## DISCUSSION

Leprosy is a disease which is still endemic in 120 developing countries and also continues to be a significant cause of blindness. Most of this blindness is avoidable and could have been prevented by early diagnosis of ocular leprosy, early systemic anti-leprosy treatment, timely treatment of the immune reactions and prompt treatment of the eye complications. According to Longitudinal study on ocular leprosy (Ethiopia, India, and the Philippines), 2.8% are blind at the time of diagnosis and 11% have potentially blinding complication.

The demographic profile of these 48 patients in the current study is consistent with published reports. The age group of presentation in our study is 30-79 years, majority of them are in 50-69 years age group. This is similar to the findings of previous reports<sup>(3,4,9-13)</sup>. Males comprises 72.91% of total which is comparable to other studies in literature<sup>(3,4,9-11)</sup>. The preponderance of male patients is because males in general expose themselves to greater risks of infection as a result of their lifestyle. On the other hand women may not tend to seek medical help even when it is required.

91.66% of patients had developed ocular lesion even after completing treatment. Hence completion of systemic anti-leprosy therapy would not ensure that the eyes are protected. These results are consistent with that obtained by Daniel et al and Bhagavat et al.<sup>(6,14)</sup>.

Systemic evaluation of these patients revealed that majority had no active skin lesions at the time of presentation for ocular involvement and the most

common neuropathy was ulnar nerve followed by deep peroneal in both the subgroup of patients. Deformities of the extremities and depressed nasal bridge were found to be more common in lepromatous type. This is comparable to the results of Sehgal et al<sup>(15)</sup>.

Ocular evaluation of these patients revealed that majority had bilateral involvement. Madrosis was the most common ocular adnexal manifestation seen in our study. These findings are, therefore, consistent with that of previous reports. Lagophthalmos was seen in 14.50% patients which is second most common adnexal finding, but other lid abnormalities, ectropion seen in only one patient. This is comparable with previous studies.

In our study acute and chronic anterior granulomatous uveitis are seen equally. This is in contrast to the known fact that the most common type of leprosy uveitis is chronic granulomatous uveitis. This could be for the reason that this study is done in a eye hospital in contrast to other studies which were mostly done in a leprasorium, hence patients with acute uveitis who are more symptomatic are more likely to seek medical care from an ophthalmologist than patients with chronic uveitis. In contrast in chronic uveitis the disease is relatively asymptomatic until later stage of the disease, by which time the patient may also develop deformities which may prevent him to seek medical care either because of stigma or because of the disability itself.

Episcleritis and scleritis was seen in 10.41% patients. According to a study done by Ebenezer et al<sup>(16)</sup> it was found that iris atrophy continues to

develop in 3% of patients with MB leprosy every year after they complete a 2-year course of MDT, and is associated with age, increasing loads of mycobacteria, subclinical inflammation, cataract and corneal opacity. In our study iris atrophy was seen in 12.5% of cases, which is more compared to previous study like Ebenezer et al<sup>(16)</sup>.

Cataract is the leading cause of blindness in leprosy affected persons, probably responsible for over 75% of incident blindness. It is found by Ebenezer et al<sup>(16)</sup> that cataract develops at the rate of 7% per person year in lepromatous patients over 40 years of age. Cataract in leprosy can be either senile, steroid induced or complicated cataract. Senile cataracts are usually more common than complicated cataract. In our study the incidence of senile cataract (50%) was found to be higher than complicated cataract (12.5%). Cataract extraction with intraocular lens implantation in these patients resulted in good visual outcome.

The visual improvement was comparable with that of normal cases. This good result after ocular surgery in Hansen's patients confirms the findings of other authors like Lamba et al<sup>(17)</sup> and Gnanadoss et al<sup>(18)</sup>.

6.25% patients met with the World Health Organization guidelines for blindness. 31.25% patients having low vision. The percentage of visual impairment in this study is comparable to results of Akbar et al<sup>(19)</sup> and Malla et al<sup>(20)</sup>.

The incidence of visual impairment found in our study group in which majority of them had completed the treatment indicates that ocular involvement can occur in spite of anti-leprotic

treatment. Thus this emphasis the importance of screening all leprosy patients even after completing the treatment.

Most of these patients were treated with steroids and responded well. Patients with good follow up and drug compliance had good visual outcome.

## CONCLUSION

Leprosy should be regarded as a potentially blinding disease with blindness rate increasing with severity and duration of disease.

Ocular adnexal involvement is more common than corneal and uveal involvement.

Eye involvement could results not only from disease but also from drug reaction.

Many patients present with more than one type of ocular pathology.

Lepromatous leprosy patients tend to have more ocular involvement than tuberculoid leprosy patient.

Leprosy is an important cause of ocular morbidity and blindness so early diagnosis and treatment is must.

Lagophthalmos should be considered one of the primary indicator for monitoring ocular disability.

Apart from leprosy related lesions, senile cataract was found to be major cause of visual impairment.

Most of these patients are not undergoing cataract surgery till late stages because of many reasons.

Regular screening and outreach by eye care providers should be incorporated into leprosy care programs.

## REFERENCES

1. Gelber RH, Braunwale E, et al (eds):

Harrison's Principles of Internal Medicine-1, 15th ed. McGraw-Hill, New York 2001: 1035.

2. Akbar MK, Baig MA & Khan MA: Ocular involvement in various types of leprosy. Pak Armed Forces, Med. J. 1998; 48(1): 11-14.
3. Tajamul Khan, Abdul Aziz Awan, Hasan Sajid Kazmi, Ashfaq Ali Shah, Sardar Muhammad & Shad Muhammad: Frequency of ocular complications of leprosy in institutionalized patients in NWFP Pakistan. Pakistan J. Med. Res . Vol. 42; 2003; No .1 .
4. Gnanadoss A Samuel & Dr. Srinivasa Rao: Ocular lesions in leprosy-a study. TNOA , 2001; 42:25-29.
5. Allen JH & Bysers JL: Pathology of ocular leprosy. Arch. Ophthalmol. 1960; 64:216 - 225.
6. E Daniel, T J ffytche, J H Kempen , PSS Sundar Rao, M Diener-West & P Courtright: Incidence of ocular complications in patients with multibacillary leprosy after completion of a 2 year course of multidrug therapy. Br. J. of Ophthalmol. 2006; 90:949-954.
7. Schwab IR, Ostler HB & Dawson CR: Hansen's disease of the Eye. In: Tasman W, Jaeger EA eds. Duane's Clinical Ophthalmology, Philadelphia, Lippincott JB;1994.
8. Lamba PA, Santoshkumar D & Arthariswaran R. Ocular Leprosy-a new perspective. Indian J. Lepr. 1983; 55: 490-



- 5.
9. Junaid S, Wani MS, Sabia Rashid MS, Muzaffar Sherwani MS, AR Nasti MS: Ocular Manifestations of leprosy. A Clinical Study. JKPractitioner 2005; 12(1):14-17.
10. Gnanadoss AS & Rajendran N: Ocular lesions in Hansen's (leprosy). Indian J. Ophthalmol. 1986; 34:19-23.
11. Reddy SC, Raju BD & Achary NR. Survey of eye complications in leprosy in Prakasam District (Andhra Pradesh). Lepr. India. 1981 Apr;53(2):231-7.
12. Mithal Sandeep, Pratap VK & Gupta Alka: Rajiv Clinico histopathological study of the eye in leprosy: Indian J. Ophthalmol. 1988; 36(3): 135-139.
13. Sanjiv Desai, Rajiv Desai, Desai NC, Shoba Lohiya & Kumar K : School of Eye Health. Ocular findings in the inmates of a leprosy rehabilitation centre. Indian J. Ophthalmol.1989; 37(2): 96-97.
14. Bhagavat P. Nepal FRCS, & Ujjowala D. Shrestha : Ocular findings in leprosy patients in nepal in the era of multidrug therapy, Am. J. of Ophthalmol. Vol.(137), Issue 5, May 2004; pages 888-892.
15. Sehgal VN, Rige VL & Mascarenas MF: Pattern of reactions in leprosy. Leprosy in India 1977; 49(2): 221 -233.
16. Ebenezer Daniel, PSS Sundar Rao, Timothy J ffytche, Shirley Chacko, Hannah Ranjee Prasanth & Paul Courtright: Iris atrophy in patients with newly diagnosed multibacillary leprosy: at diagnosis, during and after completion of multidrug treatment. Br. J. of Ophthal. 2007; 91:1019- 1022.
17. Lamba PA, Santoshkumar D & Arthariswaran R. Ocular Leprosy-a new perspective. Indian J. Lepr. 1983; 55: 490-5.
18. Gnanadoss AS & Rajendran N: Ocular lesions in Hansen's (leprosy). Indian J. Ophthalmol. 1986; 34:19-23..
19. Akbar MK, Baig MA & Khan MA.: Ocular involvement in various types of leprosy. Pak Armed Forces. Med. J. 1998; 48(1): 11-14.
20. Malla OK, Brandt F & Anten JGF: Ocular findings in leprosy patients in an institution in Nepal (Khokana). Br. J. Ophthalmol. 1981; 65:226- 230.