

www.jmscr.igmpublication.org

Impact Factor-1.1147

ISSN (e)-2347-176x



Journal Of Medical Science And Clinical Research

An Official Publication Of IGM Publication

Pregnancy in Head Injury: Friend or Foe? A Proposed Guideline for the Management of Head Injury in Pregnancy

Author

Asra Al Fauzi

Department of Neurosurgery University of Airlangga – School of Medicine Neurotrauma Center - Soetomo General Hospital Surabaya – Indonesia

Corresponding Author

ASRA AL FAUZI, MD

(NeuroSurgeon)

Department of Neurosurgery, Airlangga University School of Medicine
Dr. Soetomo General Hospital, Jl. Karangmenjangan 12, Surabaya - Indonesia

Phone: +6231-5501325, +6231-5501304

Fax: +6231-5025188

Mobile Phone: +6281-333934999

Abstract

Objectives:-

Even mild, head injury during pregnancy can threaten either the maternal or the fetal life. The risk is associated with systemic and cerebral consequences of rapid expanding mass lesion, high intracranial pressure, hypotension, anoxia or anemia. But recent studies also show that hormonal status contribute to better outcome after traumatic brain injury, and progesterone is a potent neuroprotector. This phenomena leads to different and specific management than usual case.

Key Words : Pregnancy, head injury, specific management, outcome

Introduction

Trauma is rapidly becoming the most frequent cause of maternal mortality in the developed countries, where other cause of maternal death such as infection, hemorrhage, hypertension and

thromboembolism has declined over the years by improved obstetric care. Head injury is the main cause of the maternal death^{1,2,3,4}.

Even mild, head injury during pregnancy can threaten either the maternal or the fetal life. The risk is associated with systemic and cerebral consequences of rapid expanding mass lesion, high intracranial pressure, hypotension, anoxia or anemia. Moreover, diagnostic procedure and medications can add their noxious secondary effects, contributing more or less to poor fetal outcome ^{1,2}.

Although the initial assessment and management priorities for resuscitation of the injured pregnant patient are the same as those for other traumatized patients, the specific anatomic and physiologic changes that occur during pregnancy may alter the response to injury and hence necessitate a modified approach to the resuscitation process. The main principle guiding therapy must be that resuscitating the mother will resuscitate the fetus ¹.

Epidemiology

It is very difficult to estimate the incidence of head trauma occurring in pregnancy. In many instances, especially those of minor head trauma, records or documentation are lacking. In cases involving early pregnancy, these may have either not been noted or disregarded. Recent studies demonstrate that trauma overall has emerged as the leading cause of maternal death than any other medical complication of pregnancy. It is estimated that approximately 7 % of women are injured during their pregnancy, but the true incidence is still unknown ⁵.

Review of the medical records of the Cook County Medical Examiner (1986-1989) showed that trauma caused maternal deaths in 46,5% of the 95 cases, and, of these traumatic death case, 9 % were due to traumatic head injury. The following describes the percentage of traumatic maternal deaths caused by each mechanism of injury ⁶.

Table 1 Mechanism of injury in traumatic maternal death

Mechanism of Injury	Percentage
Gunshot wounds	23 %
Motor vehicle accident	21 %
Stab wounds	14 %
Strangulation	14 %
Blunt head injury	9 %
Burns	7 %
Falls	4 %
Toxic exposure	4 %
Drowning	2 %
Iatrogenic injury	2 %

Important Physiologic Changes in Pregnancy

Maternal Physiology

Increases in cardiac output and blood volume begin early in the first trimester and are 30-40% above the nonpregnant state by 28 weeks. This relative hypervolemic state and hemodilution is protective for the mother because fewer red blood cells are lost during hemorrhage. The hypervolemia prepares the mother for the blood loss that accompanies vaginal delivery (500 ml) or cesarean section (1000 ml). However, almost 40% of maternal blood volume may be lost prior to the manifestation of signs of maternal shock^{1,2}.

Despite the increase in blood volume and cardiac output, the parturient is susceptible to hypotension from aortocaval compression in the supine position. Only about 10% of pregnant patients at term develop symptoms of shock in the supine position, but fetal compromise can be occurring even in the asymptomatic mother. Left urine displacement increases cardiac output by 30% and restores circulation. Uterine displacement must be maintained at all times during resuscitation, transport and perioperatively for nonobstetrical surgery^{1,2}.

As the uterus enlarges, the diaphragm rises about 4 cm and the diameter of the chest enlarges by 2 cm, increasing the substernal angle by 50%. Care should be taken to consider these anatomic changes when thoracic procedures such as thoracostomies are being performed. The most important respiratory change during pregnancy is the decrease in functional residual capacity (FRC). Beginning in the second trimester, there is

a 20% decrease in FRC coupled with a 20% increase in oxygen consumption. In addition, 30% of parturients have airway closure during normal tidal ventilation in the supine position. All these changes predispose to rapid falls in PaO₂ during periods of apnea or airway obstruction, thus it could damage the brain that already injured. Hence, supplemental oxygen is always indicated for these patients in the resuscitation room. Minute ventilation increases at term by 50% due to an increase in tidal volume, so normal PaCO₂ falls to 30-32 mmHg with a slight compensatory decrease in plasma bicarbonate levels^{1,2,6}.

Increased levels of progesterone and estrogen inhibit gastrointestinal motility. In addition, there is a decrease competency of the gastroesophageal sphincter, which increases the potential for aspiration. As the uterus enlarges, it displaces the intestines upward and laterally, stretching the peritoneum and making the abdominal physical examination unreliable^{1,2}.

To accommodate both maternal and fetal metabolic and circulatory requirements, renal blood flow increases by 25 to 50% during gestation. Blood urea nitrogen (BUN) and serum creatinine are reduced. Also, the kidneys enlarge by hypertrophy and hyperemia as early as the 10th week of gestation secondary to hormonal and mechanical factors¹.

The neurologic changes of pregnancy include a 25 to 40% decrease in anesthetic requirements. This means that loss of consciousness can occur even at sedative doses^{1,6}.

Fetal Physiology

The effect of trauma on pregnancy depends on the gestational age of the fetus, the type and severity of the trauma, and the extent of disruption of normal uterine and fetal physiology. The survival of the fetus depends on adequate uterine perfusion and delivery of oxygen. The uterine circulation has no autoregulation which implies that uterine blood flow is related directly to maternal systemic blood pressure, at least until the mother approaches hypovolemic shock. At that point, peripheral vasoconstriction will further compromise uterine perfusion. Once obvious shock develops in the mother, the chances of saving the fetus are about 20% ¹.

If fetal oxygenation or perfusion are compromised by trauma, the response of the fetus may include bradycardia or tachycardia, a decrease in the baseline variability of the heart rate, the absence of normal accelerations in the heart rate or recurrent decelerations. It should be noted that an abnormal fetal heart rate may be the first indication of an important disruption in fetal homeostasis. During trauma resuscitation,

evaluation of the fetus should begin with auscultation of heart tones and continuous recording of the heart rate ¹.

The finding that head injury alone is associated with loss of pregnancy is relatively novel. One explanation for this finding might be an alteration in the function of the hypothalamic-pituitary-adrenal axis after severe head injury. Clinical studies in the neurosurgical literature have demonstrated hormonal derangements in head-injured patients. Kelley and colleagues examined the function of both the anterior and posterior pituitary of 22 head-injured patients. The authors demonstrated some degree of hypopituitarism in 40% of patients with moderate-to-severe head injury, with growth hormone and gonadotrophic deficiencies being the most common. Further study on the role of the function of the hypothalamic-pituitary-adrenal axis after head injury in pregnant trauma patients is warranted, as it may be necessary to provide supplemental hormonal support to optimize pregnancy outcomes ³.

Table 2 Physiologic alterations of pregnancy and their effect ⁵

System	Alteration	Effect
Cardiovascular	Rise in C.O. by 40% at term	Supine position may decrease C.O. through reduced venous return
Respiratory	Reduced tidal volume Reduced functional residual capacity	Persistent compensated respiratory alkalosis and reduced blood buffer capacity Altered response to inhalation anesthetic

Hematologic	Reduced hematocrit Elevated leucocyte count Hypercoaguability	Dilutional Anemia Laboratory results may be misinterpreted Elevated risk of thrombosis and emboli
GI Tract	Hypomotility Compartmentalization of abdominal contents	Increased risk of aspiration dangers Elevated risk of upper abdominal-penetrating injury
Uterus and placenta	20-30% shunts Marked increases in uterine size Placental high flow and low resistance circuit	Potential rapid blood loss Abdominal organ displaced Supine hypotension

General approach to the head injured pregnant patient

The primary initial goal in treating a pregnant trauma victim is to stabilize the mother condition. The priorities for treatment of an injured pregnant patient remain the same as those for the nonpregnant patient ¹.

Primary Survey

As with any other injured patient, the primary survey of the injured pregnant patient addresses the airway/cervical spine control, breathing and circulation (ABC ; volume replacement/hemorrhage control), with the mother receiving treatment priority. Supplemental oxygen is essential to prevent maternal and fetal hypoxia. Severe trauma stimulates maternal catecholamine release, which causes uteroplacental vasoconstriction and compromised fetal circulation. Prevention of aortocaval compression is also essential to optimize maternal and fetal

hemodynamics. Pregnant patients beyond 20 weeks' gestation should not be left supine during the initial assessment. Left uterine displacement should be used by tilting the backboard to the left or as a final measure, the uterus can be manually displaced ¹.

Hypovolemia should be suspected before it becomes apparent because of the relative pregnancy induced hypervolemia and hemodilution that may mask significant blood losses. Aggressive volume resuscitation is encouraged even for normotensive patients.

Hypotension and hypoxia are the principal enemies of head-injured patient. If the patient is hypotensive, it is vital to restore normal blood volume as soon as possible. Hypotension in pregnant patient usually is not due to the brain injury itself, except in the terminal stages, when medullary failure supervenes. Hypotension on admission in patients with a severe head injury is

associated with more than double the mortality seen in patients with no hypotension (60 versus 27%). The presence of hypoxia in addition to hypotension is associated with a mortality of approximately 75%. Therefore, it is imperative that cardiopulmonary stabilization be achieved rapidly in pregnant patients with severe head injury^{1,7}.

Secondary Survey

The secondary survey consists of obtaining a complete history, including an obstetrical history, performing a physical examination, and evaluating and monitoring the fetus. The obstetrical history is important because the identification of comorbid factors may alter management decisions. The obstetrical history should include the date of the last menstruation, expected date of delivery and any problems or complications of the current and previous pregnancies. The neurosurgical history include the time and mechanism of injury, evidence of post traumatic seizure and pre hospital care medication. Determination of the uterine size provides an approximation of gestational age, i.e. measurement of fundal height is a rapid method for estimating fetal age. Determination of fetal age and hence of fetal maturity is an important factor in the decision approach regarding early delivery or decision to do simultaneously surgery¹.

The fetus is usually considered viable when it has a 50% chance of extrauterine survival. If neonatal facilities are available, this usually means at 25 to 26 weeks' gestation or an estimated weight of 750 gr. More aggressive institutions use 24 weeks' gestation or an estimated weight of 500-600

gr as the cut-off point, although chances of survival are then reduced to 20 to 30%. Decision on fetal viability are made on the basis of the best gestational age available. When estimating the fetal age in the resuscitation area, a rough guide might be that when the fundus of the uterus extends beyond the umbilicus, the fetus is potentially viable¹.

Fetal assessment

Fetal evaluation begins with checking fetal heart rate and noting fetal movement. Fetal heart tones can be detected by auscultation or Doppler probe. This should be done early in the secondary survey and repeated frequently. The normal range for the fetal heart rate is 120 to 160 beats/minute. Continuous electronic fetal heart-rate monitoring (EFM) remains the most widely used modality for evaluation of the fetus, and is an adjunct to the monitoring of the maternal condition. The use of EFM permits prompt identification of the fetus at great risk for asphyxia and fetal death. Any viable fetus of 24 or more weeks' gestation requires monitoring after a trauma event¹.

Controversy exists concerning the duration of fetal monitoring following a traumatic event to identify potential trauma-related fetal problems. The objective of the monitoring period is to identify premature labor and fetal distress. The combination of high-resolution real-time ultrasonography and cardiotocographic monitoring seems to have the highest sensitivity and specificity. They should both be instituted as soon as feasible without interfering with maternal resuscitation efforts¹.

The most common obstetric problem in head injured patient is uterine contraction, that it can cause an elevation of intracranial pressure, so it can be a potential damage to the mother¹.

Blood should be obtained and sent for electrolytes, complete blood count, platelet count, coagulation profile, typing and cross-matching, arterial blood gas, hepatic enzymes, amylase and a pregnancy test. A urynalisis also should be obtained. Because they often take time to be completed and interpreted, radiographs of the cervical spine,

chest, and pelvis should be called for immediately. Similarly, any other obvious or suspected injuries to bone or joints require radiographs of the involved area. Complete evaluation af all suspected injuries may require more complex radiographic procedures, such as head CT scan or one shoot IVP, which can be performed only in the radiology department¹.

Table 3. Suggested Laboratory Studies for Pregnant Trauma Patients

- Complete blood count
- Comprehensive metabolic panel
- Urynalis
- Blood type and screen
- Fibrinogen/disseminated intravascular coagulopathy panel
- Basic obstetric ultrasound/USG for fetal evaluation

Neurological Examination

As soon as the patient's cardiopulmonary status has been stabilized, a rapid and directed neurological examination is performed. In the acutely head injured patient, the neurological examination is necessarily abbreviated and should focus on the level of consciousness, the papillary light reflexes, extraocular eye movement, the motor examination, and lower brainstem reflexes for patients in deep coma. As part of this initial survey, the head should be carefully palpated to detect bony step-offs, and all scalp lacerations should be gently probed to assess for depressed

fractures and foreign bodies. Signs of a basal skull fracture also should be sought, including hemotympanum, cerebrospinal fluid otorrhea or rhinorrhea, and retromastoid or periorbital ecchymosis and tenderness. This initial assessment, along with inspection of the neck and thoracolumbar spine, should take no longer than 5 to 10 minutes⁷.

The triad of a deteriorating level of consciousness, papillary dilatation, and an associated hemiparesis has long been recognized as highly suggestive of a hemispheric mass lesion causing transtentorial herniation. However, any one of these findings in

a patient after head injury may be a manifestation of a traumatic hematoma and when noted should heighten the urgency of evaluation. Other etiologies of diminished consciousness also

should be considered in the patient who appears to have sustained a head injury, including seizure activity, the postictal state, drug overdose and severe hypoglycemia⁷.

Table 4 The Rapid Assessment and Evaluation of Pregnant Trauma Patients (ABCDEF format)

A-Airway	Consider placing laryngeal mask airway or endotracheal tube if necessary
B-Breathing	Supplemental oxygen in most cases
C-Circulation	Assess hemodynamic stability. Establish two large bore IV lines and replete blood loss with isotonic crystalloid solution
D-Disability	Assign an injury severity score (ISS) and Glasgow Coma Scale (GCS)
E-Expose the patient	Remove all clothing and inspect the entire body
F-Fetal basic assessment	Measure fundal height, fetal heart monitoring and gestational age determination

Diagnostic Modalities/Radiation Exposure

Following maternal stabilization and assessment, and fetal evaluation, the extent of maternal and fetal injury is determined with the help of specific diagnostic modalities. A head CT scan is always indicated in all head-injured patients with a depressed level of consciousness, including those who are heavily inebriated. An axial CT without contrast rapidly defines intracranial lesions and determines whether urgent neurosurgical interventions is required. Obtaining both brain and bone windows will help determine the etiology and the significance of focal neurological findings and whether a skull fracture is present^{1,5}.

Sensitivity to radiation is greater during intrauterine development than at any other time of life. Although there is much concern about radiation exposure, a diagnostic modality deemed necessary for maternal evaluation should not be withheld on the basis of its potential hazard to the fetus. The fetal dose of radiation received in individual cases may vary by a factor of 50 or more, depending on the equipment used, technique used, number of radiographs done in a complete study, maternal size, and fetal/uterine size. In general, x-ray beams aimed more than 10 cm away from the fetus are not dangerous¹.

Studies show that exposure of the fetus to less than 5 to 10 rad causes no significant increase in

the risk of congenital malformations, intrauterine growth retardation, or miscarriage. Although this does not mean that there are definitely no risks in exposures less than 5 rad, it does mean that this level of radiation carries little risk for the fetus when compared to spontaneous risk. At a radiation dose of 15 rad, there is approximately a 6% chance that the child could develop severe mental retardation, a less than 3% chance of developing childhood cancer, and a 15% chance of having a small head size ¹.

When performing radiographic evaluation of the mother, fetal irradiation should be minimized by shielding the abdomen when feasible with a lead apron. As a guide to physician, report from studies indicate that the radiation dose from a plain AP chest x-ray is in general below 0,005 rad, a pelvic film below 0,4 rad and CT-scan of the head (1-cm slices) 0,05 rad ¹.

Specific Management and Neurointensive Care

Technically, in head injury and pregnancy cases, there are no substantial differences with what is usually done in a similar case without pregnancy. Neurosurgical indications follow the usual rules, except in some extraordinary cases that involving the obstetric rules, the neurosurgical interventions should be limited or delayed for a while ^{1,2}.

7.

Intensive care of the patient with traumatic brain injury and pregnancy has two primary and interrelated goals : maintenance or reestablishment of maternal neurologic and systemic homeostasis and early detection of neurological deterioration. Of principal importance ICP as well as minimizing or preventing additional secondary insults resulting from hypotension, hypoxia, seizures, hyperthermia, electrolyte disturbances, coagulopathy, and infection. The secondary goal is to save the fetus if possible ^{2,7}.

Measures to control intracranial hypertension should begin prior to obtaining a CT in individuals who arrive in coma, have a precipitous decline in level of consciousness, or develop pupillary asymmetry or hemiparesis, given the likelihood that a traumatic mass lesion is responsible for the patient's deterioration. Such interventions include intubation and assisted ventilation, sedation, bolus mannitol therapy, and administration of prophylactic phenytoin. Prevention of hypotension by establishing euvolemia and in some cases vasopressor therapy also is critical to maintain adequate CPP and to help control ICP. Rapid implementation of these maneuvers will generally "buy time" and allow for precise CT diagnosis to be made

Emergent Management of Intracranial Hypertension
- Intubation
- Controlled ventilation to PaCO ₂ 30-35 mmHg
- Volume resuscitation
- Establishment of normotension

- Narcotic sedation/neuromuscular blockade
- Bolus mannitol 1 gram/kg
- Prophylactic anticonvulsant therapy

Once a secure airway is established, narcotic sedation should be achieved, a neuromuscular blocking agent can be added when agitation or abnormal posturing persist. Mild hyperventilation to achieve a PaCO₂ of 30-35 mmHg should be instituted and a 0,5 to 1,0 g/kg intravenous bolus mannitol administered. In head injured pregnant patient care, there were some issues about these kind of therapy. The management of raised intracranial pressure using osmotic diuretics (e.g. mannitol) and hyperventilation has been studied. Normal plasma osmolarity in pregnancy is slightly reduced to about 280 mOsmol. Mannitol has been administered to rabbits and shown to increase fetal plasma osmotic pressure. In this study it was demonstrated that water was drawn from the fetus to the mother resulting in severe fetal dehydration. The results of this are somewhat unclear since the osmotic pressure was increased to > 400mOsm. The other study, 200 g of mannitol were administered to pregnant women volunteers at term, one hour prior to delivery. This had the effect of raising their serum osmotic pressure from 290 to 320 mOsmol. When the fetal levels were determined it showed a fetal osmotic pressure of 312 mOsmol. In clinical usage, 100 gr mannitol has been safely administered to a pregnant neurosurgical patient^{2,7}.

Hyperventilation, while controversial, is a mainstay of the treatment of raised intracranial

pressure. The normal arterial PCO₂ is 32 mmHg thus hyperventilation may require levels of CO₂ that are extremely low. It has been suggested that extreme hypocapnia causes direct uterine vasoconstriction possibly leading to fetal hypoxia. It is likely not so simple. In an elegant study it was demonstrated that mechanical ventilation did indeed lead to a reduction in uterine blood flow. However, if the inspired CO₂ was increased to maintain normocapnia the same degree of reduction in uterine blood flow occurred. Thus the hyperventilation rather than the hypocapnia lead to a reduction in uterine blood flow, likely through mechanical reduction in venous return and subsequent decrease in cardiac output. While it is nice to understand the mechanism for the reduction, it remains that the effective range for hyperventilation is reduced in pregnancy and caution must be exercised when approaching levels of arterial CO₂ of 24 mmHg or less².

Prophylactic anticonvulsant therapy with phenytoin should be administered as an additional preemptive measure against intracranial hypertension given that generalized seizures in a patient with an intracranial mass lesion can have devastating consequences⁷.

A significant percentage of head-injured patients harbor traumatic intracranial hematomas that require surgical evacuation. These patients must be taken to surgery without delay. Some reports

have demonstrated that prompt evacuation of acute subdural hematomas can immediately and dramatically improve cerebral blood flow. Unfortunately, even with prompt surgical intervention, some patients still have a poor outcome. In these cases, underlying diffuse axonal injury, ischemia, or other pathological processes are probably present in conjunction with the mass lesion⁸.

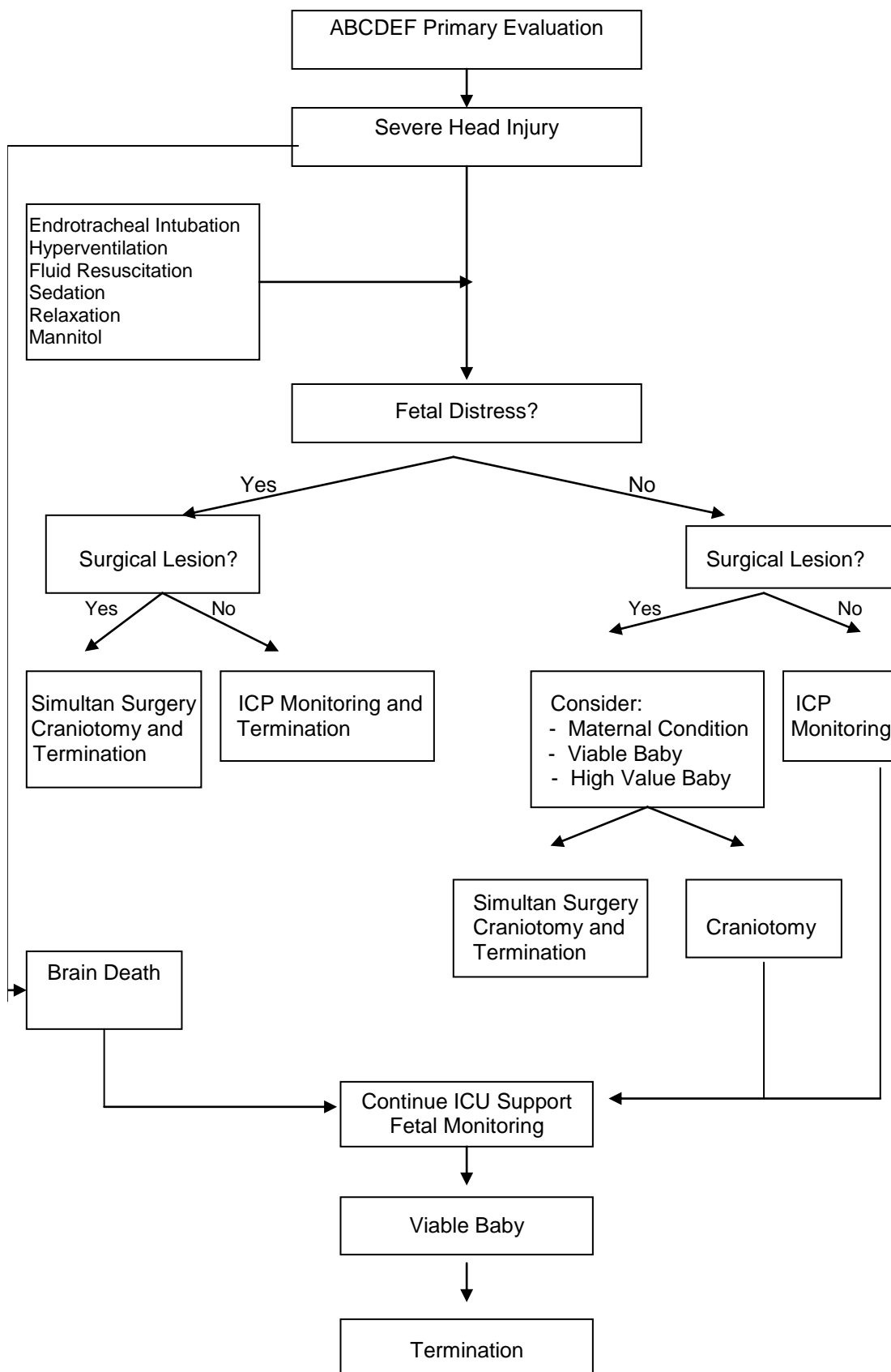
In some cases of severe head injured patient with pregnancy, we have to perform surgery simultaneously with obstetrician. Termination of pregnancy is indicated in order to save the mother, because pregnant condition will make the maternal condition worst. And in another cases, we have to do limited intervention such extraventricular drainage. This maneuver perform if the condition of maternal was not good, and obstetrician have to do delivery pervaginam, that can raised the ICP.

During neurosurgical operative procedure, osmotic diuresis, controlled hypotension, hypothermia and hypocarbia are commonly induced to decline the intracranial pressure (ICP). In the pregnant patients, those may adversely

affect the fetus. In addition to the monitors used during neurosurgical interventions monitorization of the fetus and uterus should be used if possible. An external Doppler fetal heart rate monitor will be useful. Close observation of maternal blood pressure and prompt treatment of hypotension and hypoxia are essential for a well fetus. Postoperatively, the patient should placed in a lateral position with her head slightly elevated. Fetal heart rate and uterine tone should be monitored at least 24-48 hours.¹⁰

The concept that progesterone is a strong neuroprotective agent is still debatable. Laboratory evidence indicates that this agent has it's effect on brain damage. The first clinical trail was conducted at Atlanta, Georgia, 2007 (ProTECT study), this is the only randomized clinical trail of progesterone effect in traumatic brain injury in human until now. The result showed that progesterone caused no discernible harm, and showed possible signs of benefit. And survivors after moderate head injury who received progesterone were more likely to have a moderate to good outcome than placebo.¹¹

Algorithm Management of Severe Head Injured Pregnant Patient



Note : Neurosurgical operative indications follow the usual rule, viable baby means 30 weeks gestation and 1000 gr estimated baby weight

RESUME OF CASES

NO	AGE	GESTATION	GCS	NEUROLOGIC DEFICIT	PATHOLOGY	TREATMENT	OUTCOME
1	21	32 Weeks	113	Unequal Pupil And Hemiparesis	SDH	Craniotomy and Cesarean Section	GOS 5, the Baby alive
2	30	32 Weeks	113	Unequal pupil	SDH	Craniotomy and SC	Death, the baby alive
3	21	28 weeks	356	-	SDH	Conservative Treatment	GOS 5
4	29	30 weeks	345	-	ICH	Cesarean Section	GOS 5, IUFD
5	27	28 weeks	345	-	SDH and ICH	Conservative Treatment	GOS 5
6	21	21 weeks	356	-	SDH	Conservative Treatment	GOS 5
7	24	24 weeks	346	-	ICH	Craniotomy	GOS 5
8	24	18 weeks	112	Unequal Pupil And Hemiparesis	EDH and ICH	Craniotomy and SC	GOS 5
9	25	28 weeks	115	-	SDH	Craniotomy and SC	GOS 5, the Baby alive
10	29	30 weeks	113	-	ICH	Craniotomy and SC	Mother and the baby died
11	23	32 weeks	335	Left Hemiparesis	ICH	Cesarean Section	GOS 5, the Baby alive
12	30	16 weeks	325	Unequal Pupil	SDH and ICH	Craniotomy	Death with the baby
13	21	20 weeks	326	-	SDH	Conservative Treatment	GOS 5

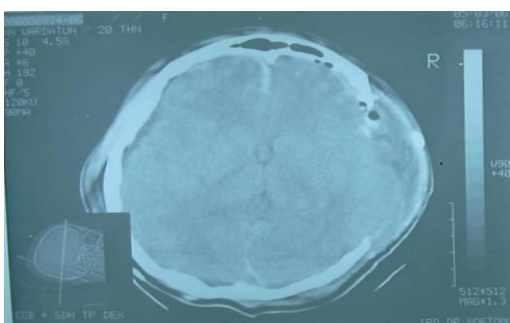
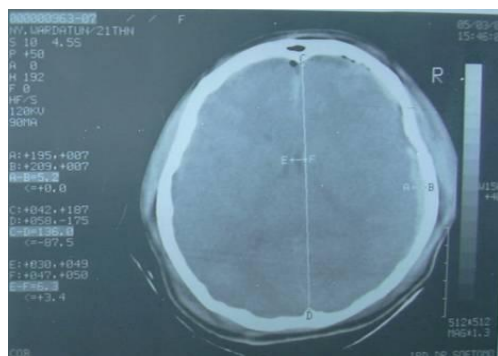
Review of Cases :

1. Case No. 1 ; A 21-year-old woman with 32 weeks gestation sustained a severe head injury

after fall from motorbike. She never conscious since the accident. And there was a history of seizure after the accident. This patient arrive in

neurosurgery emergency care about six hours after the accident. After resuscitation, on neurologic examination, GCS score was 113, Her pupils were unequal, dilatation on right side and nonreactive. Motor examination showed left hemiparesis. Fetal heart monitoring showed a fetal distress condition. She was quickly intubated and a CT scan showed a thin frontotemporoparietal subdural hematoma with an associated midline shift 0,63 cm to the left. She was immediately given mannitol and phenytoin and taken to the operating room. We performed craniotomy decompression and simultaneously the obstetrician did cesarean surgery to terminate the pregnancy.

Figure 1 : CT scan pre and post operation



Repeated CT six hours post operation, showed absence of midline shift, but cerebral edema still persists.

On day 5, her condition improved GCS score 225, equal pupils and slight left hemiparesis. The condition of the baby was good and monitored in the neonatal intensive care unit. On the day of 20, GCS score was 456, motoric function became normal and the patient and the baby discharge from the hospital in good condition.

2. Case No. 2 ; A 30-year-old-woman in 32 weeks gestation, with a history of unconsciousness after traffic accident when the motorbike she was riding went out of control and struck a car. She was promptly transported to the neurosurgical emergency unit. After resuscitation, neurological examination, GCS score was 113, pupil was unequal, dilatation on left side, motoric function seems normal. Vital signs were still in normal limit. Fetal heart monitoring revealed no sign of fetal distress. A CT scan revealed a thin subdural hematoma in left frontotemporoparietal region, with mass effect 0,6 cm midline shift to the right. Simultan surgery was performed, involving neurosurgeon, obstetrician and neuroanesthetist. Neurosurgical procedure contain craniotomy, evacuation of hematoma and decompression. After the operation the condition of the patient was not improved, and in day of 5 she died. The baby alive and the family took him home five days later.

Figure 2 : CT scan pre and post operation

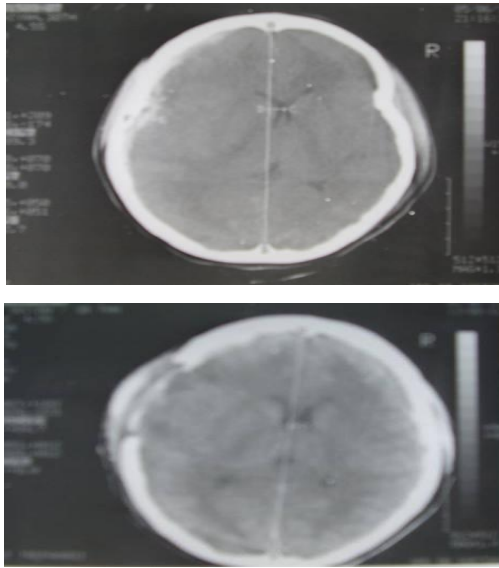
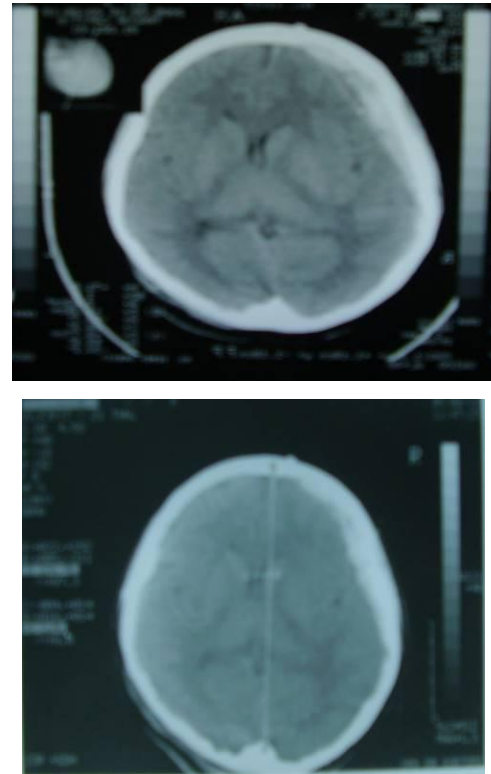


Figure 3 : CT scan initial and repeated CT.

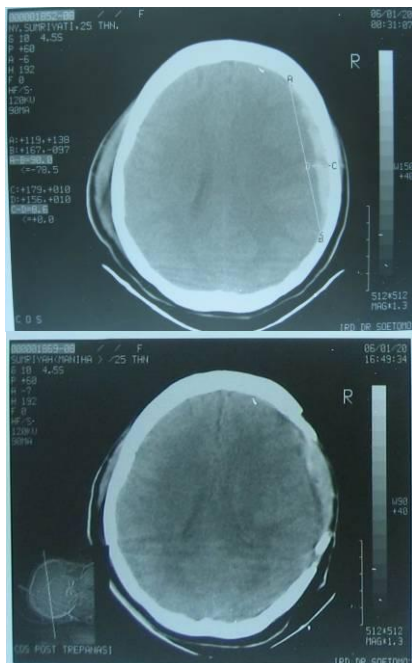


3. Case No. 3 ; A 21-year-old-woman with a history of traffic accident, fall from motorbike. She was referred at 28 weeks' gestation from other district hospital for advice and better management concerning her pregnancy with head injury. On admission in ER unit, GCS score was 356, no neurological deficits only symptoms of moderate to severe headache. The vital sign and extracranial condition was in normal limit. No fetal distress detected. Initial CT showed a 1,3 cm thickness of SDH at right frontotemporoparietal region with midline shift to the left 0,8 cm. We treated this patient conservatively with close observations in Intensive Care Unit. Repeated CT after 24 hours showed no enlargement of the hematoma and no increase of the shift. We continue to manage conservatively, fetal heart monitoring was intermittently performed. After three days treatment, the patient condition improved, GCS 456 and no longer complaint of headache. In the day of 5, the patient discharge from hospital.

4. Case No. 9 ; A 25-year-old-woman with a history of traffic accident, fall from motorbike. She was referred at 28 weeks' gestation from other district hospital. On admission in emergency unit GCS score was 115, no neurological deficits. Fetal heart monitoring revealed no sign of fetal distress. A CT scan revealed a 0,7 cm thickness of subdural hematoma in right frontotemporoparietal region, with mass effect 0,5 cm midline shift to the right. Simultan surgery was performed, involving neurosurgeon, obstetrician and neuroanesthetist.. Neurosurgical procedure contain craniotomy, evacuation of hematoma and decompression. After the operation the condition of the patient was improved, and in day of 12 the GCS score improved 456. The baby alive and after 17 days treatment they

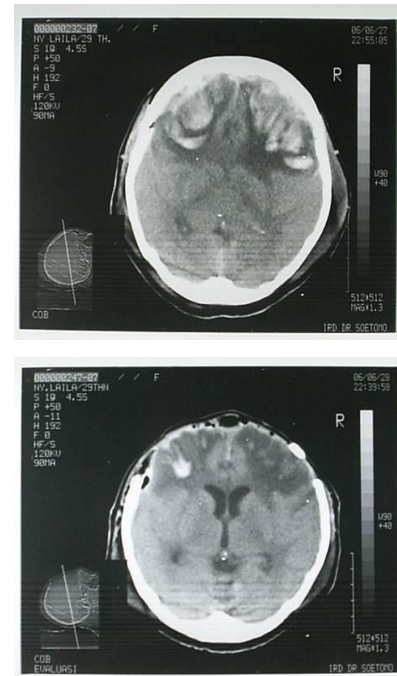
discharge from the hospital. The mother GOS score was 5.

Figure 4. The CT scan pre and post operation



terminate the pregnancy. The baby died in first day treatment because of respiratory distress syndrome. The mother died seven days later because of pulmonary problem.

Figure 5. CT pre and post operation

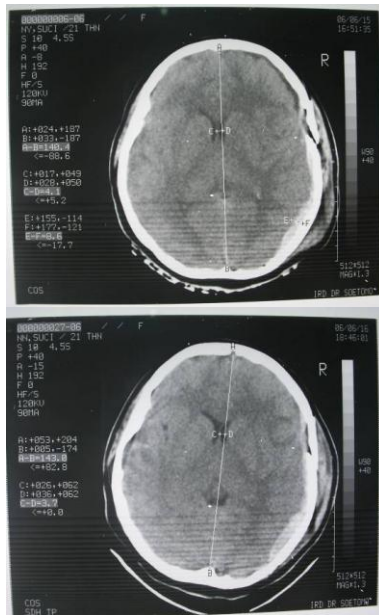


5. Case No. 10 ; A 29-year-old woman with 30 weeks gestation sustained a severe head injury after traffic accident, collision of motorbike against truck. She never conscious since the accident. This patient arrive in neurosurgery emergency care about three days after the accident. This patient had been treated in distric hospital, and then referred because the condition was not improved After resuscitation, on neurologic examination, GCS score was 113, Her pupils were equal,. Motor examination showed no hemiparesis. Fetal heart monitoring showed no fetal distress condition. She was quickly intubated and a CT scan showed a large bifrontal intracerebral hemorraghe. She was immediately given mannitol and taken to the operating room. We performed craniotomy decompression soon after the obstetrician did cesarean surgery to

6. Case No. 13 ; A 21-year-old-woman with a history of traffic accident, fall from motorbike. She was referred at 20 weeks' gestation from other district hospital. On admission in ER unit, GCS score was 326, no neurological deficits.. The vital sign and extracranial condition was in normal limit. No fetal distress detected. Initial CT showed a 0,8 cm thickness of SDH at right temporooccipital region with midline shift to the left 0,4 cm and fragmented linear fracture at temporoparietal region. We treated this patient conservatively with close observations in Intensive Care Unit. Repeated CT after 24 hours showed no enlargement of the hematoma and no increase of the shift. We continue to manage conservatively, fetal heart monitoring

was intermittently performed. After twelve days treatment, the patient condition improved, GCS 4/5 .n the day of 15, the patient discharge from hospital.

Figure 6. Initial and repeated CT.



Discussion

1. Even mild, head injury during pregnancy can threaten either the maternal or the fetal life. The risk is associated with systemic and cerebral consequences of high intracranial pressure.
2. It is estimated that approximately 9 % of maternal traumatic death case were due to traumatic head injury.
3. Technically, in head injury and pregnancy cases, there are no substantial differences with what is usually done in similar case without pregnancy. Neurosurgical indications follow the usual rules, except in some extraordinary cases that involving the obstetric rule, neurosurgical interventions should be limited or delayed for a while.

4. Intensive care of pregnant patient with head injury has two primary goals : maintenance or reestablishment of maternal neurologic and systemic homeostasis and early detection of neurological deterioration. The secondary goal is to save the fetus if possible.
5. We reported 13 cases with different management and outcome. We did simultaneously surgery on 5 cases, conservative treatment on 4 cases and we recommended cesarean section procedure on 2 cases. All patient with conservative treatment were manage with close observation in intensive care unit. There were 3 maternal death, 1 neonatal death and 2 intra uterine fetal death.
6. To the best of the author's knowledge, this is the first specific guideline for the management of severe head injury in pregnancy. It is still needs more research and clinical studies to improve the definitive and better management guidelines for this kind of traumatic head injury.

Conclusion

The pregnant trauma patient presents a unique challenge to emergency physicians because care must be provided for two patients-the mother and the fetus- and sometimes in acute circumstances may demand immediate, simultaneously and multidisciplinary management. Care of pregnant patients with head injury often requires multidisciplinary approach involving an

neurosurgeon, obstetrician, anesthesiologist and neonatologist.

References :

1. Desjardins G. Management of the injured pregnant patient. Trauma Org. Trauma in Pregnancy. 2008.
2. Penning D. Trauma in pregnancy. Canadian Journal of Anesthesia, 2001;48 :R7.
3. Ikoissi DG, Lazar AA, Morabito D, Fildes J, Knudson MM. Profile of mother at risk : An analysis of injury and pregnancy loss in 1,195 trauma patients. Journal of American College of Surgeon, 2005, 49-56.
4. Ekele BA, Nnadi DC, Shehu BB. Pregnancy outcome in women in road traffic accidents in sokoto. Nigerian Journal of Surgical Research, 2004, 6:46-48.
5. Sherer DM, Schenker JG. Accidental injury during pregnancy. Obstetrical and Gynecological Survey, 1989 ;44 :330-338.
6. Newton ER. Trauma and Prergnancy. E Medicine. 2005.
7. Kelly DF, Doberstein C, Becker DP. General principles of head injury management in Narayan RK, Wilberger JE, Povlishock JT Eds : Neurotrauma. New York : Mc Graw-Hill, 1996: 71-101.
8. Valadka AB, Narayan RK. Emergency room management of the head-injured patient. In Narayan RK, Wilberger JE, Povlishock JT Eds : Neurotrauma. New York : Mc Graw-Hill, 1996: 119-135.
9. Harris CM. Trauma and pregnancy. In Foley MR, Strong TH, Garite TJ Eds : Obstetric intensive care manual. New York; Mc Graw-Hill, 2004 :237-248.
10. Cirak B, Kiyman N, Kerman M, Tahta K. Neurosurgical procedures in pregnancy. Acta Cirurgica Brasileira, 2003, Vol.10, No.1.
11. Wriugh DW, Kellerman AL, Hertzberg VS, et al. ProTECT : A randomized clinical trial of progesterone for acute traumatic brain injury. Annals of Emergency Medicine.2007;49:391-402.