

## Embryo Protective Effect of Leaf Extract of *Vitex Negundo* Linn. in Adriamycin Induced Toxicity

Authors

**Hitesh U. Shingadia<sup>1</sup>, Vinayak Dalvie<sup>2</sup>**

Dept. of Zoology, SVKM's Mithibai College of Arts, Chauhan Institute of Science & Amrutben Jivanlal College of Commerce & Economics Vile Parle - West Mumbai 400 056 Maharashtra India

Email: [hiteshshingadia26@gmail.com](mailto:hiteshshingadia26@gmail.com)

### Abstract

Herbal drugs are known to prevent toxicity in general & side effects of certain molecules in particular. Further, they are also being evaluated for their character of protecting embryo against such toxins & molecules. Administration of anticancer drugs such as Adriamycin during embryonic development in animals has been shown to cause foetal malformations. Since there are very few antioxidants and synthetic agents to prevent the toxicity in embryo, present investigation was carried out, in which herbal leaf extract of *Vitex negundo* Linn. was proved to have effect of protecting chick embryo from Adriamycin (ADR). The results of present study clearly reveal the toxicity of drug on the developing chick embryos. A significant decrease in weight of ADR-treated group was due to decreased energy supply as evidenced by the altered properties of macromolecules of yolk-sac & reduction in extra-embryonic vascular network which, in turn, reduced the nutrient transport, hence detrimental to the embryonic growth & damage to vital tissue like kidney when compared with the control. A momentous decrease in the volume of amniotic fluid is believed to be caused due to decrease in the amount of albumin entering the amniotic fluid via sero-amniotic connection that constricts the perforation of sero-amniotic plate.

**Key Words:** Adriamycin; Amniotic fluid; Chick embryo; Kidney; *Vitex negundo* Linn

### INTRODUCTION

Antineoplastic agents produce adverse effects on experimental animals as may be the case also with human embryos. Adriamycin (ADR) also called Doxorubicin is one such broad spectrum

anticancer drug. It is one of the most active antineoplastic agent developed to date for the treatment of soft and solid tumors including acute leukemia's, malignant lymphomas and particularly breast, bladder, endometrial, head and

neck, hepatic and prostate cancers. The morphological effects of Adriamycin on chick, mice and rat embryos in vivo are well recognized (Mortell et al., 2003; Loannides et al., 2002; Beasley et al., 2000). Adriamycin is known to be mutagenic, genotoxic as well as carcinogenic at higher doses. The mechanism of Adriamycin effect as an anticancer drug is redox cycling of ADR semiquinone radical, Intercalation of DNA & interference with the function of enzyme DNA topoisomerase II & inhibition of RNA & protein synthesis. Within cell ADR interacts with several oxidoreductases. Animal and human data suggests that most of the antineoplastic drugs may have deleterious effects on the foetus, including increased incidences of premature births, intrauterine growth retardation, still birth and low birth weight (Matalan et al., 2004). Adriamycin toxicity is of serious concern during pregnancy period. ADR administration during embryonic development is known to cause foetal malformation & teratogenesis.

Animal models have also shown a high risk of congenital anomalies, which in human occur mainly when the drugs are administered during the first trimester (Matalan et al., 2004). Preclinical assays using mammalian models are still time-consuming. Furthermore, limits from ethical and legal points of view for working with those models are already very restrictive and are increasing steadily. The chick embryo is a well-known model, which has been extensively studied from Aristotle's time, who opened hen's eggs daily to examine progressive stages of embryogenesis

until the modern molecular era (Wallis, 1985). An increasing interest in the chick embryo as a model in biological and pharmaceutical research is related to its simplicity and low cost compared with mammalian models. Although chick embryos are not widely used for the evaluation of new drug carriers, the United States Food and Drug Administration has approved products pre-clinically evaluated with chick embryos (Wallis, 1985). A study on amniotic fluid is widely applicable in clinical diagnosis & management; however analysis of amniotic fluid assists in understanding the foetal status.

Today herbal medicines are coming back into prominence because of decreasing efficacy of the modern medicines. Besides, many synthetic drugs are also causing deleterious side effects. In absence of reliable embryo protective drugs to curtail embryo toxicity of modern medicine or otherwise, herbal drugs can be used to prevent the same and are being evaluated for their embryo protective effect. *Vitex negundo* Linn. commonly known as 'nirgundi' belongs to family Verbenaceae (Fig. 1). Heated nirgundi leaves are tied over the affected part, scrotal swelling, sinusitis & rheumatic arthritis. Decoction of leaves is used in endometritis, colitis and orchitis. Gargles with the decoction are useful in pharyngitis, stomatitis and throat inflammation. Smoke of dry leaves is useful in headache, sinusitis and common cold. In vitro and animal studies have shown that the plant has potential anti-inflammatory (Dharmasiri et al., 2003), antibacterial (Raghuramulu et al.,

2003), antifungal (Sathiamoorthy et al., 2007) & analgesic (Gupta and Tandon, 2005) activities. However dearth of literature on embryo protective effect of *Vitex negundo* Linn. led to probe into this aspect of the plant.

## MATERIALS & METHODS

### Preparation of alcoholic leaf extract of *Vitex negundo* Linn.:

The fresh leaves were collected locally from in & around Mumbai & their identity was authenticated (59971) (Fig. 1). The leaves were shade dried for a week & powdered using a mixer grinder. The sieved powder of leaves was subjected to soxhlet extraction using ethanol, which gave high extractive value. The extract was filtered & ethanol was vacuum evaporated at 55°C. The extract was then stored at -20°C until further use. For determination of percentage extractive values method from Trease & Evans (1983) and Wallis (1985) was employed.

### Chemicals:

Adriamycin (Doxorubicin hydrochloride) from Pfizer was used. All other chemicals & reagents were of analytical grade & procured from Merck, Lobachem & Qualigens. The diagnostic kits for biochemical assays were purchased from Span Diagnostics & Biolabs Pvt. Ltd. Mumbai, India.

### Incubation & maintenance of eggs:

Freshly laid zero-day old fertilized eggs were procured from Central Poultry Farm (WR), Government of India, Aarey Milk Colony, Goregaon-Mumbai, India. The eggs were cleaned

with distilled water & 70% alcohol & placed in an incubator set at 37°C with relative humidity of 58-60% maintained by keeping tray filled with water inside the incubator. The eggs were rotated manually & examined through candling every day for the proper growth & viability. The eggs with dead embryos were immediately removed from the incubator. Eggs were candled to locate the injection site for the administration of drug, avoiding membrane bound blood vessels that were marked 2.0 cm below the air space (Schrott et al., 1999).

### Embryo toxicity study:

The 12 days old chick embryos were taken for the toxicity study. These eggs were divided into four groups containing six embryos in each group. Based on the LD<sub>50</sub> values, embryos were administered with Adriamycin (50, 60 & 70 µg) on 12<sup>th</sup> day. Simultaneously sterile normal saline was administered in embryos of control group by injecting into air space. After administration, the injection site was sealed with molten paraffin & eggs were returned to incubator for further incubation. The embryos were scored for morphological changes; change in volume of amniotic fluid & body weight at the end of 48 hours of incubation by comparing ADR treated groups with their respective controls.

### Experimental design:

To study embryo protective effect of alcoholic extract of leaf of *Vitex negundo* Linn. in Adriamycin induced toxicity in chick embryos experimental set up was divided into five groups of six embryos each (Table 1). The leaf extract

was administered into chick embryos 6 hours prior to administration of Adriamycin. The

embryo protective role of leaf extract was assessed after 48 hrs. of incubation.

Table 1 Experimental design

Experimental Groups	Dosage
Group 1	Control (Normal saline)
Group 2	Extract control (200 µg of extract/egg)
Group 3	Adriamycin (70 µg/egg)
Group 4	Dose 1 (100 µg of extract/egg) + Adriamycin (70 µg/egg)
Group 5	Dose 2 (200 µg of extract/egg) + Adriamycin (70 µg/egg)

### Collection of amniotic fluid & embryonic tissues:

After experimental period, 12 days old chick embryos were sacrificed by opening air space. Amniotic fluid & kidney tissue were collected aseptically & stored at -20°C until further use.

### Biochemical analysis of amniotic fluid:

Amniotic fluid was collected from incubated eggs & centrifuged at 3000 rpm for 10 min. to remove cell debris. Clear supernatant was used for biochemical assays. The concentration of Urea (Natelson, 1998), Creatinine (Broad et al., 1948), Uric acid (Mortell et al., 2003), Potassium, Sodium, Calcium (Raghuramulu et al., 2003) & Inorganic Phosphorus (Fiske and Subbarow, 1925) were estimated by standard methods.

### Histopathology of embryonic tissues:

Kidney tissue was immediately washed in chilled saline & fixed in neutral formalin fixative to prevent autolysis and preserve the shape, structure and chemical constituents of the tissue. After 24 hours of fixation the tissues were dehydrated with

alcohol & subjected to the process of infiltration in paraffin wax (M.P. 52-54°C). Paraffin blocks were prepared and sections were cut on the microtome at 4-5 µm thickness. The ribbons were taken on slides and passed through xylene to dewax the tissue. The dewaxed tissues were dehydrated with alcohol. The tissues were stained with Ehrlich's haematoxyline and Eosin Y stains (Gurr, 1956). Finally the sections were mounted in Diether Plasticizer Xylene & photomicrographs were taken using digital camera.

### Statistical analysis:

All the results were expressed as mean  $\pm$  standard error for six embryos in each group & the difference between the groups were considered significant when P-value determined was less than 0.05 & 0.01.

### RESULTS & DISCUSSION

In the present investigation a significant dose versus time dependent decrease in the volume of amniotic fluid as well as weight of the 12 days old chick embryos exposed to Adriamycin were

observed when compared with the control group of chick embryo (Table 2). There is an antioxidant/pro-oxidant balance in tissues during development of chick embryo, which is responsible for normal embryonic development & post-hatch chick viability (Sura, 1999). ADR induces generation of free radicals, which along with reactive metabolite are either detoxified through conjugating with glutathione that is considered to be critical in protection against

embryo toxicants (Sura, 1999) or reacts with tissue macromolecules & initiates its damage. The toxic effect of ADR on chick embryos at higher doses (70 µg) indicates that ADR is converted into toxic metabolites. At higher doses ADR is unable to detoxify for the paucity of glutathione to match the higher doses on one hand while glutathione levels in the tissue depletes on the other hand as the embryonic development advances.

Table 2 Weight of 12 days old chick embryo & volume of amniotic fluid after 48 hrs. of Adriamycin treatment

Parameter	Exposure period (12 <sup>th</sup> day)	Group 1 (Control)	Group 2 (ADR 50µg)	Group 3 (ADR 60µg)	Group 4 (ADR 70µg)
Weight of embryo (G/egg wt.)	48 hrs.	9.28±0.08	8.72±0.03**	7.32±0.04**	6.65±0.11*
Volume of amniotic fluid (mL/embryo)	48 hrs.	5.5±0.15	4.9±0.20*	3.3± 0.12*	3.95±0.09**

(Average values of six observations, mean ± SE)

Statistically significant at \*\*P<0.01, \*P<0.05

Amniotic fluid or 'liquor amnii' is the nourishing and protecting liquid contained by the amnion. The liquid contains proteins, carbohydrates, lipids, phospholipids, urea and electrolytes, all of which aid in the growth of the foetus. The level of these contents can be used as a diagnostic tool in studying the development of the foetus. Hence in the present study the biochemical estimation of

the amniotic fluid was recorded (Chandrakar et al., 2010). Alterations in the volume of amniotic fluid due to various teratogenic agents have been reported by several workers (Gulienetti et al., 1962). A significant decrease in the volume of amniotic fluid is believed to be caused due to decrease in the amount of albumin entering the amniotic fluid via sero-amniotic connection. The

conditions that retard the perforation of sero-amniotic plate also affect the fluctuations in the volume of amniotic fluid.

**Effect of *Vitex negundo* Linn. leaf extract on ADR induced biochemical changes in chick embryos:**

Administration of ADR caused significant biochemical changes in amniotic fluid (Table 3-4). No significant alterations of biochemical parameters were observed in Group 2 embryos that were administered with herbal leaf extract of *Vitex negundo* when compared with control Group 1 chick embryos. In ADR treated Group 3, significant elevation ( $P < 0.01$ ) in levels of cellular & non-protein nitrogen components such as Urea, Uric acid & Creatinine as well as sodium, Potassium & Inorganic Phosphorus levels was

observed. Elevated levels of Urea, Uric acid & Creatinine in ADR treated group might be due to damage caused by ADR to nitrogen metabolism. Uric acid the end product of purine metabolism is a selective antioxidant, capable of reacting with free radicals & hypochlorous acid (Hasugawa and Kuroda, 1989). An elevated level of Creatinine is an evidence of marked impairment of kidney function & its retention is thus an index of glomerular insufficiency in chick embryo (Vargas et al., 2007). All these levels were significantly ( $P < 0.01$ ) normalized, when pretreated (6 hrs. prior to administration of ADR) with leaf extract of *Vitex negundo* Linn. (Group 4 & 5) in a dose-dependent manner at the end of 48 hrs. of incubation, after the treatment of ADR.

Table 3 Concentration of biochemical constituents in amniotic fluid of chick embryo at the end of 48 hrs. treatment of Adriamycin

Groups	Urea (mg/dL)	Uric acid (mg/dL)	Creatinine (mg/dL)
Group 1 (Control)	25.15± 0.12	33.86± 0.07	1.78± 0.05
Group 2 (LE 200 µg)	26.79± 0.06	34.32± 0.09	1.87± 0.07
Group 3 (ADR 70 µg)	48.00± 0.08	52.65± 0.11	3.08± 0.13

Group 4 (LE 100 µg + ADR 70 µg)	35.43± 0.20*	41.82± 0.17*	2.4± 0.02**
Group 5 (LE 200 µg + ADR 70 µg)	33.69± 0.05**	38.2± 0.09**	1.96± 0.11*

(Average values of six observations, mean ± SE)

Statistically significant at \*\*P<0.01, \*P<0.05

Table 4 Concentration of mineral contents in amniotic fluid of chick embryo at the end of 48 hrs. treatment of Adriamycin

Groups	Sodium (mEq/L)	Potassium (mEq/L)	Calcium (mg/dL)	Inorganic Phosphorus (mg/dL)
Group 1 (Control)	131.65± 0.07	10.5± 0.14	12.2± 0.16	1.34± 0.05
Group 2 (LE 200 µg)	132.45± 0.15	11.59± 0.04	11.31± 0.21	1.58± 0.09
Group 3 (ADR 70 µg)	105.36± 0.05	19.19± 0.07	7.26± 0.09	4.72± 0.07
Group 4 (LE 100 µg + ADR 70 µg)	97.82± 0.21*	17.27± 0.10**	10.23± 0.06*	2.34± 0.13**
Group 5 (LE 200 µg + ADR 70 µg)	92.35± 0.16*	16.05± 0.11**	13.67± 0.12*	3.25± 0.22*

(Average values of six observations, mean ± SE)

Statistically significant at \*\*P<0.01, \*P<0.05

**Effect of *Vitex negundo* Linn. leaf extract on ADR induced histopathological changes in chick embryos**

**Group 1 (Control administered with 0.9% Saline):**

The kidney tissue sections of Group 1 showed normal histoarchitectural features (Fig. 2). Kidney showed normal intact renal tubules and glomeruli with intact Bowman capsule. Brush bordered cuboidal epithelium lining the proximal convoluted tubules. Simple cuboidal epithelium lining the distal convoluted tubules

**Group 2 [Extract control group (200 µg of extract/egg)]:**

The histological section of kidney of extract control group showed renal parenchyma without any significant focal changes in tissue histology that implies no significant adverse effect of leaf extract of *Vitex negundo* Linn. (Fig. 4).

**Group 3 [Adriamycin (70 µg/egg)]:**

Photomicrographs showed moderate degree of pathological alterations in Kidney as compared to all other groups (Fig. 3). The kidney from Group 3 showed moderate nephropathic changes that included tubular damage with loss of tubular epithelium, marked tubular basophilia with (Fig. 6).

glomerular changes. Degenerative and necrotic changes with vacuolation of cytoplasm, cellular swelling was also seen in few renal tubules. The nephrotoxic changes could be attributed to the administered Adriamycin.


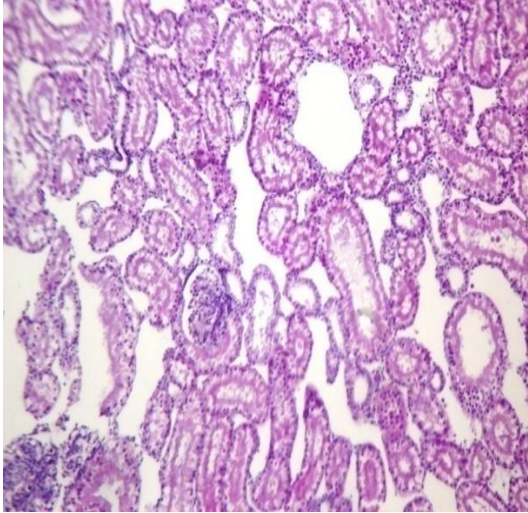
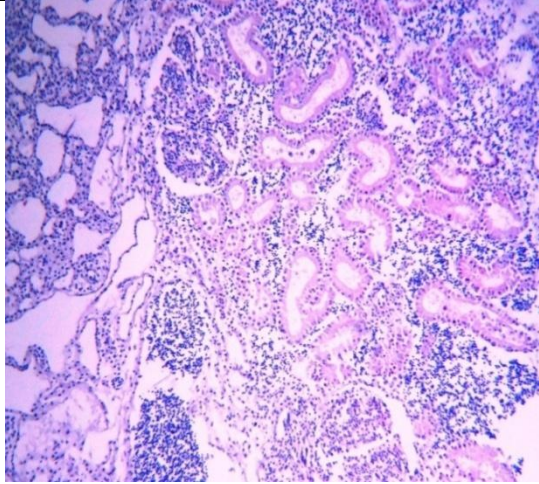
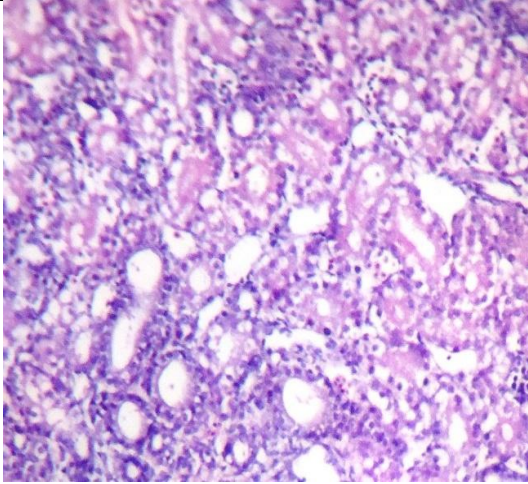
**Group 4 [Dose 1 (100 µg of extract/egg) + Adriamycin (70 µg/egg)]:**

Apparently kidney parenchyma appeared normal in the photomicrograph. Tubular basophilia was observed (suggestive of foetal developmental stage) & reduced effect of Adriamycin induced pathological changes due to protective effect of herbal drug. Focal tubular swelling, granular and vacuolar changes in cytoplasm, mild tubular degeneration, slight glomerular changes (Size, Atrophy, hypercellularity etc.) signify nephropathy (Fig. 5).

**Group 5 [Dose 2 (200 µg of extract/egg) + Adriamycin (70 µg/egg)]:**

The kidney sections in photomicrograph revealed renal parenchyma with focal minimal histological changes in tubular epithelium with minimal degenerative changes signify protective role of herbal drug against ADR



	
<p>Fig. 1 <i>Vitex negundo</i> Linn. Leaf used in the preparation of alcoholic extract.</p>	<p>Fig. 2 Photomicrograph of kidney from Grp. 1 showing normal architecture of tissue. (H&amp;Ex200)</p>
	
<p>Fig. 3 Photomicrograph of Kidney from Grp. 2 showing normal renal parenchyma &amp; intact renal tubule. (H&amp;Ex200)</p>	<p>Fig. 4 Photomicrograph of Kidney from Grp. 3 showing tubular damage, basophilia &amp; vacuolation. (H&amp;Ex200)</p>

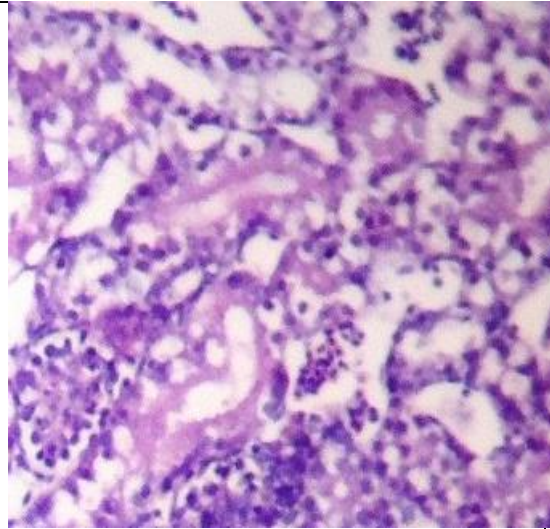


Fig. 5 Photomicrograph of kidney from Grp. 4 showing mild tubular basophilia with nominal glomerular changes. (H&Ex200)

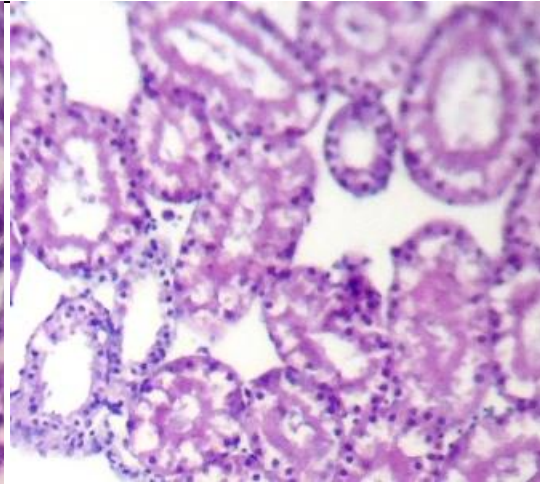


Fig. 6 Photomicrograph of kidney from Grp. 5 showing no degenerative changes in renal parenchyma. (H&Ex200)

## CONCLUSION

There is increase in number of females conceiving during advanced age, which is associated with the carcinomas whose number is increasing by leap & bound. As there are few herbal antioxidants for embryo protection newer and better drugs should be searched for embryo protection against toxic side effects of anticancer drugs. Beneficial effect is minimizing the malformations by maintaining peroxidant/antioxidant balance. The present investigation proves that the adverse effect of ADR is reduced significantly on pretreatment with herbal leaf extract of *Vitex negundo* Linn. by restoring peroxidant/antioxidant balance & biochemical parameters in developing chick embryos.

## Acknowledgement

Authors express their deep sense of gratitude to the University of Mumbai for granting funds to

carry out this project. Thanks are also due to SVKM Management & Principal of Mithibai College for their encouragement & support.

## REFERENCE

1. Beasley, S. W., Diez Pardo, J. Qi, B. Q., Tovar, J. A., Xia, H. M. 2000. The contribution of the Adriamycin-induced rat model of the VATER association to our understanding of congenital abnormalities and their embryogenesis *Pediatr. Surg. Int.* 16, 465-472.
2. Broad, J., Sirota and Renal, J. H. 1948. Clearance of endogenous creatinine in man. *J. Clin. Invest.* 627-645.
3. Chandrakar, M., Raipure, R., Manwar, N., Chandrakar, S. 2010. Effect of ethanol on glucose, protein, cholesterol and calcium level in the amniotic fluid of chick embryo *The Bioscan* 5 (2), 189-191.

4. Dharmasiri, M. G., Jayakody, J. R., Galhena, G., Liyanage, S. S., Ratnasooriya, W. D. 2003. Anti-inflammatory and analgesic activities of mature fresh leaves of *Vitex negundo*. J. Ethnopharmacol. 87 (2-3), 199-206.
5. Fiske, C. H., Subbarow, Y. J. 1925. Biol. Chem. 66, 375-400.
6. Gupta R. K., Tandon V. R. 2005. Antineoplastic activity of *Vitex negundo* Linn. leaf extract. Indian J. Physiol. Pharmacol. 49 (2), 163-170.
7. Gulienetti, R., Kalker, H., Davis, N. C. 1962. Bio. Neonat. 4, 300-309.
8. Gurr, E. 1956. A Practical Manual of medical and biological staining techniques. Leonard Hill (Books) Ltd.
9. Hasugawa, T., Kuroda, M. 1989. J. Clin. Pathol. 37, 1020-1027.
10. Loannides, A. S., Chaudhry, B., Henderson, D. J., Spitz, L., Copp, A. J. 2002. Dorsoventral patterning in oesophageal atretia with tracheo-oesophageal fistula: Evidence from a new mouse model. J. Pediatr. Surg. 37(2), 185-191.
11. Matalan, S. T., Ornoy, A., Lishner, M. 2004. Review of the potential effects of three commonly used antineoplastic and immunosuppressive drugs (Cyclophosphamide, Azathioprine, Doxorubicin on the embryo and placenta). Repr. Toxicol. 18, 219-230.
12. Mortell, A., Giles, J., Bannigan, J., Puri, P. 2003. Adriamycin effects on the chick embryo. Pediatr. Surg. Int. 19(5), 359-364.
13. Natelson, S. 1998. Technique of Clinical Chemistry 3<sup>rd</sup> edition. 606-609.
14. Perumalsamy, R., Ignacimuthu, S., Sen, A. 1998. Screening of 34 Indian medicinal plants for antibacterial properties. J. Ethnopharmacol. 62(2), 173-182.
15. Raghuramulu, N., Nair, K. M., Subdaram, S. K. 2003. Manual of laboratory techniques, 4<sup>th</sup> edition. 176-189.
16. Sathiamoorthy, B., Gupta, P., Kumar, M., Chaturvedi, A. K., Shukla, P. K., Maurya, R. 2007. New antifungal flavonoid glycoside from *Vitex negundo* Bioorg. Med. Chem. Lett. 17(1), 239-242.
17. Schrott, L. M., Sweeney, W., Bodensteiner, K., Sparber, S. B. 1999. Pharmacol. Biochem. Behav. 64, 81-89.
18. Sura, P. F. 1999. Brt. Puol. Sc. 40, 397-405.
19. Trease, A. Evans, T. 1983. Pharmacognosy 12<sup>th</sup> Edition.
20. Wallis, T. E. 1985. Text book of Pharmacognosy, CBS Publishers and Distributors.
21. Wershana, K. Z., Kabeer, A. Y. & Shaban, W. M. 2001. Sciences (1), 157-175.
22. Vargas, A., Zeisser-Labouebe, M., Lange, N., Guny, R., Delie, F. 2007. The chick embryo and its chorio-allantoic membrane (CAM) for the in-vivo evaluation of drug delivery system. Adv. Drug Delivery Reviews 59, 1162-1176.