

Quinacrine Sterilization Induce Cryptomenorrhoea: A Rare Complication

Authors

Brig Kumar Praveen MD (Gynae) *, **Gp Capt JC Sharma MD (Gynae)¹**,
Dr Rupa Talukdar , MD (Gynae)²

*Consultant (Obs & Gynae) Base Hospital Lucknow

¹Associate prof (Obs & Gyn) Army college of medical sciences Delhi Cantt.

² Senior Gynaecologist , cantonment general hospital, Delhi Cantt.

Email: jcsharma47@rediffmail.com

Abstract-

Quinacrine was used as a non-surgical technique for permanent sterilization was been under study several years back . It was used and propagated by several resource poor countries to control population . It was relatively inexpensive and had mass acceptability due to similarity in procedure of IUCD insertion.. The side effects of this sterilization process have been reported to be low as compared to surgical methods. Menstrual abnormalities in the form of menorrhagia and ammenorrhoea have been reported but cryptomenorrhea was very uncommon complication. Here we present a case of quinacrin induced crypyomenorrhoea in a young women.

Keywords: quinacrine, cryptomenorrhoea, trans cervical sterilization, heamatometra.

INTRODUCTION

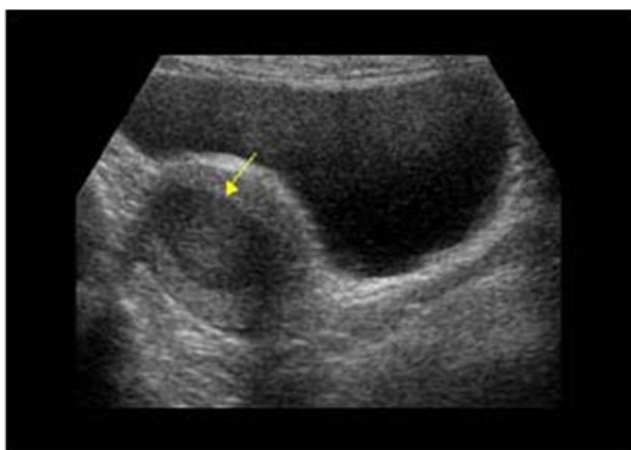
Quinacrine was used as a non-surgical technique for permanent sterilization was been under study several years back . It was used and propagated by several resource poor countries to control

population. It was relatively inexpensive and had mass acceptability due to similarity in procedure of IUCD insertion.. The side effects of this sterilization process have been reported to be low as compared to surgical methods. Menstrual

abnormalities in the form of menorrhagia and amenorrhoea have been reported but cryptomenorrhoea was very uncommon complication. Here we present a case of quinacrin induced cryptomenorrhoea in a young women.

CASE REPORT

A 32 year old para 3 lady had presented with secondary amenorrhea since last 2 years. She gave a history of undergoing sterilization procedure by quinacrine administration by 2 years back . She gave history of cyclical pelvic pain, pressure in the pelvis for the last 6 months. There was no history of difficulty of micturition and defecation or vaginal discharge . Her general and systemic examination findings were normal. On pelvic examination revealed healthy vulva, vagina and normal external cervical os. Uterus was enlarged, 12 weeks in size, soft, regular in shape and freely mobile. Her Hb was 12.5 Gm %. Urine for pregnancy test was negative. Ultrasound pelvis revealed homogenous hypoechoic collection within the uterine cavity of approximately 32 cc with impression given as hematometra.



Ultra sound image of haematometra

The pelvic cavity and adnexa was normal . there was no collection of in the pouch of Douglas . she was evaluated and was managed in the operation room under spinal anesthesia with cervical dilatation and drainage of collected altered blood..

About 100 ml of collected altered blood was drained and sent for culture and sensitivity.(Fig 1).

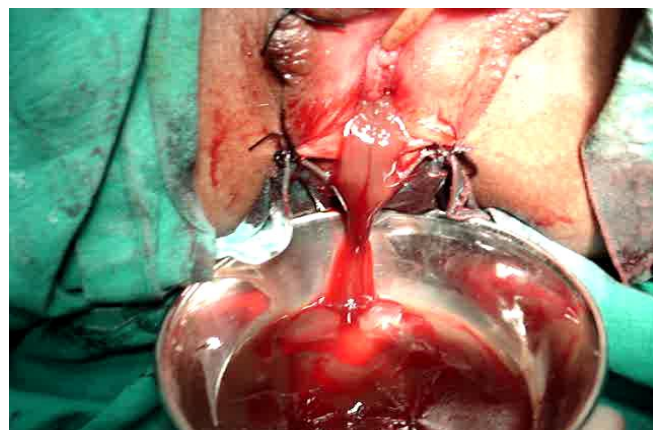


Figure 1 Haematometra draining in OT

Her postoperatively she was managed with antibiotics and analgesics. She had smooth uneventful post operative recovery.

Patient presented with similar history of amenorrhea again after 3 months. On assessment it was revealed that she had developed recurrence of cryptomenorrhoea due to cervical canal occlusion. She underwent similar procedure of cervical dilatation, evacuation of the altered blood followed by insertion of insertion of a Foley's catheter.(fig 2)

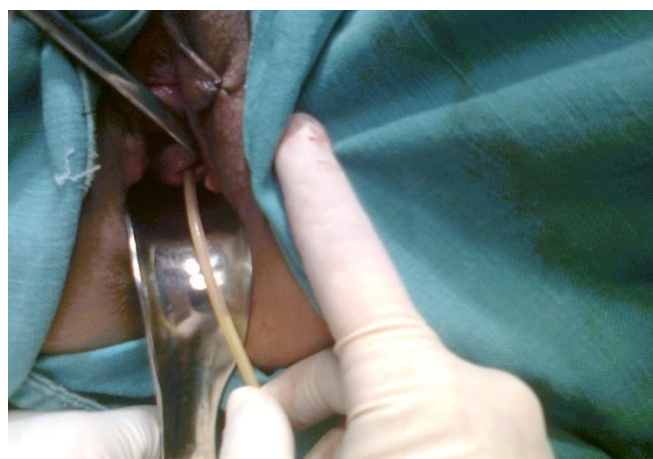
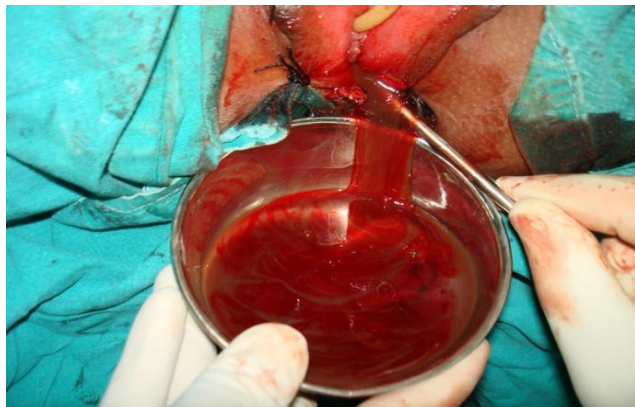

Figure 2 Indwelling Foleys catheter in uterine cavity

She was advised to report during next menstruation for removal of catheter. Catheter was removed following next menstrual cycle

which occurred after 1 month. Subsequently she had remained asymptomatic and had normal regular menstrual cyclical periods. the cyclical pain also subsided.



Repeat draining of haematometra

DISCUSSION

Zipper and colleagues demonstrated in animal study the sclerosing effects of quinacrine due to chelation of DNA forming quinacrine-DNA complexes after intrauterine quinacrine administration causing occlusion of the tubal ostia of rats in 1973 .(1) following early animal experiments and the accepted clinical application of quinacrine for inducing pleural sclerosis, Zipper and associates proceeded to investigate this as a method of sterilization in humans by use of transcervical administration of quinacrine. Initially it was used as slurry liquid, with dilutions of 125 mg/mL and 250 mg/mL. Despite promising early effective results, this method was abandoned after 3 deaths were reported that were attributed to rapid absorption through endometrial capillaries.(2)

In 1977 Zipper and colleagues (3) developed a new pellet-based method in which 7 pellets of 36 mg of quinacrine each (252 mg total) are placed into the uterus and tube using a device similar to a copper T intrauterine device (IUD) inserter for 2 to 3 doses 1 month apart . Quinacrine is a drug with a number of different medical applications. Its main use are as an antiprotozoal, antirheumatic and an intrapleural sclerosing agent. It was used as alternative prophylaxis and

therapeutic antimalarial agent during Second World War when Japan stopped the rout of supply of quinine. In a study of 2592 Chilean women followed over 25 years, quinacrine pellets offered a cumulative pregnancy rate of 4.6%,(4) which was corroborated by findings from Indonesia, where a study of 200 women followed over 10 years revealed a pregnancy rate of 4.3% However, recent 10-year data from Vietnam has questioned these data with reported pregnancy rates of 12.1% . (5)

The use of quinacrine for non-surgical sterilization for women has been under research for many years. This method was first developed by Zipper et al. who reported a first year failure rate of 3.1%(6) . Local application of quinacrine is not reported to cause any major side effects (7,8,9). However there are reports of minor complications like as lower abdominal pain (58%), fever (13.5%), leukorrhoea(7.5%), menorrhagia (3.5%),and ammenorrhoea(1.0%-15%) (10,11) . Hematometra has been reported with quinacrine sterilization in only a few cases(11,12) . The cause might be due to the scarring of the endocervical canal similar to the scarring of the tubal ostia. This may occur particularly when the drug instead of accumulating in the fundus seeps down in the uterine cavity. Hence, the procedure is safe in trained hands and when the necessary precautions have been taken. In 1998 Govt of India ban the quinacrine as sterilizing agent.

REFERENCES

1. Zipper J, Prager R, Medel M. Biological changes induced by unilateral instillations of quinacrine in the rat: reversion through the use of estrogen and progesterone. *Fertil Steril.* 1973;24:48–53.
2. . Zipper J, Medel M, Goldsmith A, et al. The clinical efficacy of the repeated transcervical instillation of quinacrine for female sterilization. *Int J Gynaecol Obstet.* 1976;14:499–502.

3. Zipper J, Cole LP, Goldsmith A, et al. Quinacrine hydrochloride pellets: preliminary data on a nonsurgical method of female sterilization. *Int J Gynaecol Obstet.* 1980;18:275–290.
4. Zipper J, Trujillo V. 25 years of quinacrine sterilization experience in Chile: review of 2,592 cases. *Int J Gynaecol Obstet.* 2003;83(suppl2):S23–S29.
5. Sokal DC, Hieu do T, Loan ND, et al. Contraceptive effectiveness of two insertions of quinacrine: results from 10-year follow-up in Vietnam. *Contraception.* 2008;78:61–65.
6. Zipper J, Cole LP, Goldsmith A, Wheeler R, Rivera M. Quinacrine hydrochloride pellets: preliminary data on a nonsurgical method of female sterilisation. *Int J Gynaecol Obstet* 1980;18:275-90.
7. International Journal of Gynecology and Obstetrics. (October 2003). "Quinacrine Sterilization: Reports on 40,252 cases". London: Elsevier. Vol 83 (Suppl. 2).
8. Sokal, D.C., Kessel. E., Zipper. J. and King. T. "Quinacrine: Clinical experience". A background paper for the WHO consultation on the development of new technologies for female sterilization. 1994.
9. Peterson, H.B., Lubell, L., DeStefano, F., and Ory, H.W. (). "The safety and efficacy of tubal sterilization: an international overview". *Int J. Gynaecol. Obstet.* 1983; 21: 139–144.
10. Suhadia, M. Anwarb, A. Soejoenoes. 10-year follow-up of women who elected quinacrine sterilization (QS) in Wonosobo, Central Java, Indonesia. *International Journal of Gynecology and Obstetrics.* 2003; 83 (2): S137–S139.
11. J. Zipperl, L.P. Colez, M. Rival, E. Brown And R.G. Wheeler Efficacy of two insertions of 100-minute releasing quinacrine hydrochloride pellets for non-surgical female sterilization *Advances in Contraception.* 1987; 3:255-61
References and further reading may be available for this article. To view references and further reading you must purchase this article.
12. Ljiljana Randi , Herman Haller and Silva Sojat Nonsurgical female sterilization: comparison of intrauterine application of quinacrine alone or in combination with ibuprofen. *Fertility and Sterility.* 2001;7(4) 830-831.