



Pott's Spondylodiscitis with Gibbus in a 5 Year Old Child – A Case Report

Authors

Dr. Farah Naaz¹, Dr. R.K.Gulati²

¹PG Resident, Department Paediatrics, Government Medical College, Kota

Address- 122 Deepshree Apartment Flat no 504 Shaktinagar Kota

Email: *nfarah30@gmail.com*

²Professor & Head of department Paediatrics, Government Medical College, Kota

Address: Department of Paediatrics, J.K.LONE Hospital Kota

Email: *rksh_gulati@gmail.com*

ABSTRACT

A 5-year-old boy was referred to us with a 3-month history of swelling and pain on his back. On laboratory evaluation, he only had an elevated erythrocyte sedimentation rate. X-ray showed an extensive lytic lesion of the dorso lumbar spine. Chest roentgenogram was normal. The Mantoux skin test was negative. Histological examination of the biopsy tissue showed granuloma and caseating necrosis of tuberculosis. antituberculous chemotherapy resulted in a good clinical outcome. A high index of suspicion therefore, is the key to timely diagnosis and treatment.

Keywords: *potts spine ,5 year old boy ,att.*

INTRODUCTION

Presentations of tuberculosis are protean and are not limited to the pulmonary disease alone. The spectrum of pediatric tuberculosis includes asymptomatic primary infection, progressive pulmonary TB and extrapulmonary disease including lymphadenitis, meningitis and osteomyelitis. Skeletal TB occurs in about 1-3% and in some studies accounts for 1-6% of the extrapulmonary cases.¹⁻³ Any part of the skeletal

system can be involved but in order of frequency the sites most commonly involved are the spine, femur, tibia and fibula.

Tuberculous spondylitis is the most common form of extrapulmonary TB which is around 50% of cases. This refers to the infection of one or more vertebral bodies by *Mycobacterium tuberculosis* with or without involvement of the spinal canal^{2,3}. It occurs as a result of the hematogenous spread or erosion of adjacent

caseating lymphnodes after a primary pulmonary infection that is not generally evident in children as they are more vulnerable to the occurrence of discitis because of the persistence of the anastomosis between the motor endplate and the spinal disc⁴. The objective of this report is to describe a child case of spondylitis on the lower thoracic spine. And thus show the importance of identifying the disease as soon as possible.

CASE REPORT

A 5 year old boy presented with history of gradual worsening of pain in back, and limping of gait. There was no history of trauma, recurrent infections, or past medical history of any note. Child was developmentally normal. The only

associated symptom was of anorexia. Child was Given BCG vaccination at birth.

On examination child was comfortable at rest. He was afebrile and systemic examination was unremarkable. Regional examination of both hips and lower limbs revealed difficulty in weight bearing .There was ESR of 90 mm/hr, increased CRP of 71mg/dl, WBC COUNT of 15000gd/l. there were no symptoms of pulmonary tb in chest x ray.

Plain xray pelvis and spine reveals collapse of D6 and loss of disc space between S1S2.a tuberculin PPD demonstrated skin reactions with wheal measuring 23 mm after 48 hours of inoculation. This supported diagnosis of spinal tb.MRI dorsal spine demonstrated:

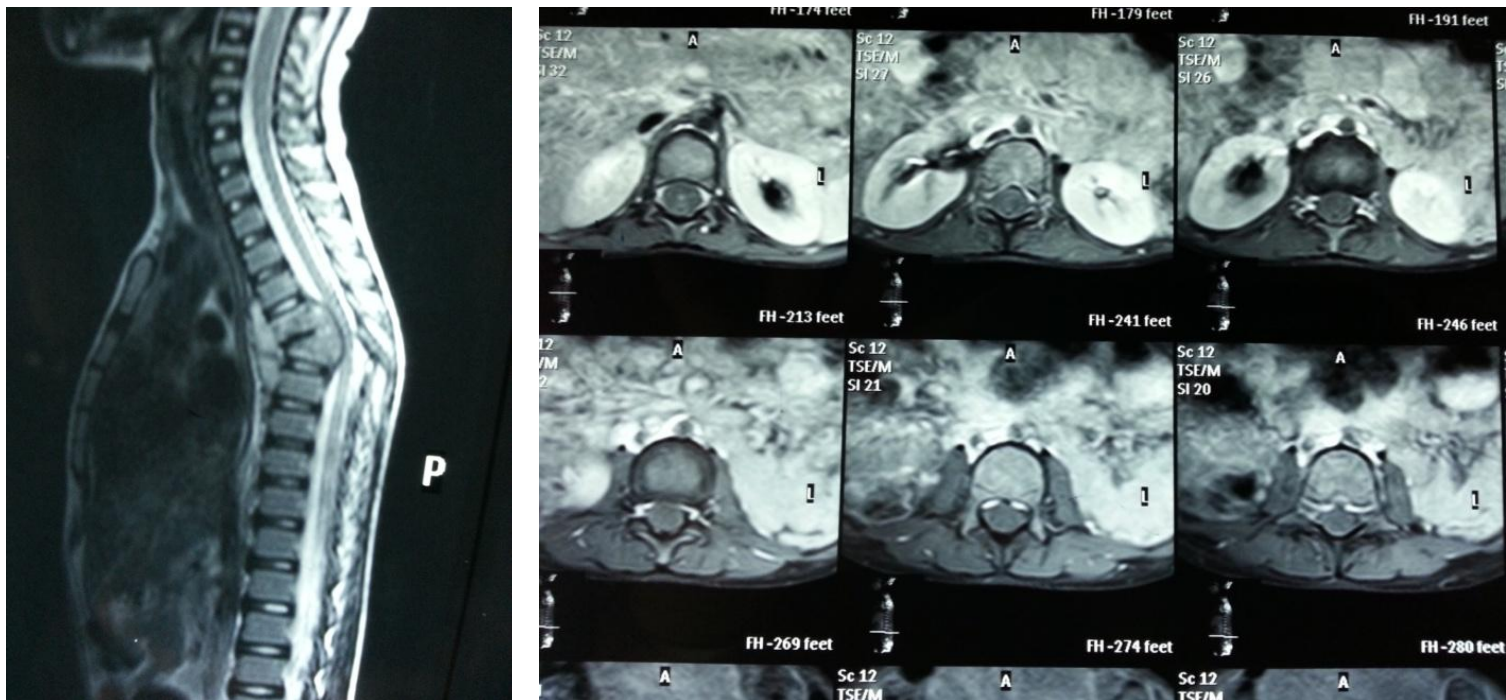


Fig1 and 2: MRI giving evidence of collapse of D6 vertebral body with their posterior displacement.

Following completion of course of anti TB therapy child symptoms resolved completely.

DISCUSSION

Osteoarticular TB currently accounts for 35% of all cases of the extrapulmonary form of the disease, which is more commonly found in children and the in elderly. In vertebrae, the segment most often affected is the thoracic spine

Diagnosis of skeletal tuberculosis should be considered in any child who has a positive Mantoux test, evidence of present or past TB, history of contact with a tuberculous patient and any child having persistent, otherwise unexplained bone or joint lesion.^{5} Radiological changes are not pathognomic. Findings range from soft tissue swelling, periostitis with bone expansion and cortical destruction, diffuse uniform infiltration and localized osteitis. In the early stages, when plain radiographs are normal, CT scan or an MRI may be helpful in localizing the lesion.

No single test of synovial fluid is diagnostic of tuberculosis except for a positive AFB smear or culture. As the disease is paucibacillary, a positive AFB smear is rare, so the diagnosis usually is confirmed by obtaining granulomatous tissue on biopsy.^{6,7} Other investigations should include ESR, X-ray chest, X-ray spine and CSF study to rule out any concomitant extra skeletal lesion.

In the most severe form of Pott's disease, spinal deformation and collapse can compress the spinal cord, thus causing neurological disorders such as paresis and paralyse^{8}. In this case report, the patient did not display neurological signs, despite the compressive effects exerted by the posterior displacement in the T11 and T12 vertebral bodies. Unlike adults, who have a higher incidence of neurological symptoms with more localized

inflammatory signals, in children, the disease is characterized by an extensive and diffused involvement, the formation of abscess and the low incidence of Pott's paraplegias or tetraplegias^{9}. Histological analysis of the lesions, although nonspecific, demonstrated diagnostic value by providing evidence of chronic granulomatous inflammation, as found in most cases.^{10}

As this is a paucibacillary form of TB, it remains a challenge to identify the etiologic agent by routine screening. STNPCR is a variant of PCR, which is currently being used, in CPqAM/FIOCRUZ, and has been giving promising results in non-invasive, clinical samples, collected in outpatient clinics, from patients with paucibacillary TB

Treatment includes both chemotherapy and orthopedic intervention. The orthopedic procedures can be used for several purposes such as diagnosis, evacuation of caseum and necrotic bone, immobilization of joint, and reconstruction or strengthening of damaged bone.^{11}

Antituberculous drugs are the mainstay of treatment.

CONCLUSION

Refinement of existing tools and development and testing of new tools are urgently required to improve diagnosis and treatment of TB in children.. In addition to reducing the burden of adult TB, attention to childhood nutrition and improvement in the socioeconomic and environmental condition of communities is likely to have a significant impact on TB transmission to children. The prognosis for recovery without deformity is significantly good provided a timely

diagnosis is made and proper chemotherapy initiated before the development of complications.{12}.

REFERENCES

1. Shikhare SN, Singh DR, Shimpi TR, Peh WC. Tuberculous osteomyelitis and spondylodiscitis. *Semin Musculoskelet Radiol* 2011; 15:446-458.
2. Medical Research Council Working Party on Tuberculosis of the Spine. Twelfth report of the Medical Research Council Working Party on Tuberculosis of the Spine. Controlled trial of short-course regimens of chemotherapy in the ambulatory treatment of spinal tuberculosis. Results at three years of a study in Korea. *J Bone Joint Surg Br* 1993; 75:240-248.
3. Schettino LC, Carelli LE, Barbosa MO. Tuberculose vertebral: análise descritiva de uma série de casos submetidos a tratamento cirúrgico. *Coluna/ Columna* 2010; 9:119-125
4. Maltezou HC, Spyridis P, Kafetzis DA. Extra-pulmonary tuberculosis in children. *Arch Dis Child* 2000;83:342-6.
5. Rasool MN. Osseous manifestations of tuberculosis in children. *J Pediatr Orthop* 2001;21:749-
6. Dhillon MS, Nagi ON. Tuberculosis of the foot and ankle. *Clin Orthop* 2002;398:107-13
7. Jacobs RF, Starke JR. Tuberculosis in children. *Med Clin North Am* 1993; 77:1335-1351
8. Moreira, CP; Carvalho, MAP. Tuberculose osteoarticular: apresentação de 38 casos. *Rev Bras Reumatol* 1980; 20: 251-259.
9. Arcelis RRM, Marques HHS, Matielo RLB, Sakane PT, Baldacci ER. Tuberculose Ostearticular em crianças. *Pediatria (São Paulo)* 2006; 28:169-174
10. Wessels G, Hesselting PB, Beyers N. Skeletal tuberculosis: dactylitis and involvement of the skull. *Pediatr Radiol* 1998;28:234-6
11. Dhillon MS, Nagi ON. Tuberculosis of the foot and ankle. *Clin Orthop* 2002;398:107-13