

www.jmscr.igmpublication.org

Impact Factor 3.79

ISSN (e)-2347-176x



The Truth About Labial Adhesion

Author

Mahalakshmi.T

M.Sc Nursing, Ph.D Scholar, Associate Professor, Community Health Nursing
Saveetha College of Nursing, Saveetha University, Chennai-105

ABSTRACT

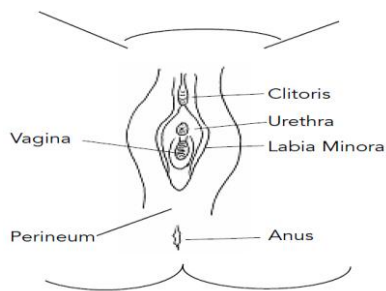
Labial adhesions is a medical condition of the female genital anatomy where the labia minora become fused together. It is generally a pediatric condition. & occurs most frequently in younger pre-pubertal girls ages 3 months to 6 years .It is caused by something that has irritated the vaginal area. & patient may present with symptoms like dysuria, urinary frequency, refusal to urinate, or post-void dribbling.(riding a bicycle, teeter-totter, etc.). A Doctor will be able to diagnose labial adhesions by examination. Labial Adhesions in girls without symptoms therapy may not be needed, but with symptoms estrogen cream or ointment is usually the first medication chosen & this topical cream or ointment is most successful in resolving the adhesions.

INTRODUCTION

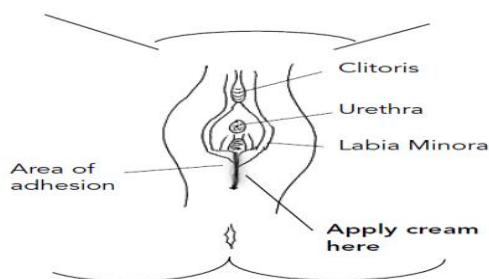
Labial adhesions are very thin pieces of tissue that cause the folds of skin outside the vagina to stick together. It is a medical condition of the female genital anatomy where the labia minora become fused together. It is generally a pediatric condition. The condition is known by a number of names, including labial fusion, labial adhesion, labialsynechia, labial agglutination,

labial adherence, gynatresia, vulvar fusion, and vulvar synechia. Labial fusion is never present at birth, but rather acquired later in infancy, since it is caused by insufficient estrogen exposure and newborns have been exposed to maternal estrogen in utero.

Normal Female Genitalia



Labial Adhesion



EPIDEMIOLOGY

Labial agglutination occurs most frequently in younger pre-pubertal girls ages 3 months to 6 years, though it may begin at any age and persist or reoccur until puberty. This problem is rarely seen after girls begin their pubertal growth (breast development, pubic, and axillary hair) due to production of estrogen by their ovaries. Estrogen, one of the two female hormones produced by the ovaries, provides a protective affect to the genital tissue making adhesions less likely to occur.

ETIOLOGY

Labial adhesions are usually caused by something that has irritated the vaginal area. Because the labia are so close together, when the irritated area heals, the labia sometimes become temporarily stuck together. Some possible irritants were soaps or bubble bath.

SIGNS & SYMPTOMS

The finding may be asymptomatic and noticed at the time of a routine office visit or identified by a health care provider evaluating symptoms of urinary tract (bladder) infection, abnormal urinary emptying (stream of urine), vaginal discharge, or pain in the genital area. Pain may be especially prominent when performing straddle activities (riding a bicycle, teeter-totter, etc.). In other cases, patients may present with associated symptoms of dysuria, urinary frequency, refusal to urinate, or post-void dribbling. Some patients present with vaginal discharge due to pooling of urine in the vulval vestibule or vagina.

DIAGNOSIS

A doctor will be able to diagnose labial adhesions by examination. No further investigations or tests are necessary. The diagnosis of labial adhesions or agglutination is customarily made by close inspection of the external genitalia. A mid-line joining (called a raphe) of the labia minora and vestibule is noted. The adhesions may involve the entire length of the labia minora or only a portion, and below the labia minora, the edges of the vestibule. The area of external anatomy covered by a complete adhesion or agglutination is called the vestibule. When partial occlusion of the vestibule is present, it is usually the lower portion (posterior), and the opening may obscure the entrance to the vagina. When the labia minora and vestibule are completely adhered, the openings to the vagina and to the bladder (urethra) are covered and only a tiny pinpoint opening is usually seen.

In some girls, no opening is clearly visible. The skin over the clitoris is also frequently adhered or agglutinated. This is a normal finding in female children before puberty.

TREATMENT

| Treatment Options | |
|--|---|
| Asymptomatic girls | Symptomatic girls |
| <ul style="list-style-type: none"> No treatment may be needed | <ul style="list-style-type: none"> Topical estrogen Manual separation |

i) A SYMPTOMATIC CHILDREN

Since labial agglutination in girls without symptoms therapy may not be needed. Eventually the child's own estrogen at the time of puberty will assist with spontaneous resolution.

ii) SYMPTOMATIC CHILDREN

Symptomatic children with suspected urinary tract infection, urinary retention, abnormal urinary stream, or recurrent vaginal infection may need to have the agglutination treated in order to resolve the condition or prevent future medical problems. When therapy is indicated an estrogen cream or ointment is usually the first medication chosen. This topical cream or ointment is most successful in resolving the adhesions when applied to the mid-line of the labia with a fingertip or Q-tip. & this therapy is customarily utilized for several weeks in order to provide adequate time for success. Failed medical therapy indicates the need for manual separation of the labia. This should NOT be done forcefully without anesthesia. Separation in the office may be accomplished with

local anesthesia (topical jelly or ointment) or under sedation administered by an anesthesia team in an outpatient surgical setting. At the time of separation, careful inspection for normal anatomy of the vagina and urethra is made.

SIDE EFFECTS OF THERAPY

Estrogen preparations may occasionally cause side effects, especially if used for prolonged periods longer than a few weeks. These are small amounts of breast budding or breast enlargement, local irritation, Vaginal spotting or bleeding after the estrogen is discontinued. Breast budding or local irritation also resolve spontaneously when the medication is discontinued. Following manual separation, use of estrogen cream for 1-2 weeks followed by use of a bland emollient (white petroleum jelly or other diaper rash preparation) for an indefinite period of time is indicated in order to prevent recurrence of the adhesions.

COMPLICATIONS

Labial fusion can lead to urinary tract infection, vulvar vestibulitis and inflammation caused by chronic urine exposure. In severe cases, labial adhesions can cause complete obstruction of the urethra, leading to anuria and urinary retention

RECURRENCE

Recurrent adhesions of the labia minora may occur. Treatment of recurrences is based on the patient's symptoms and findings at the time of recurrence and may not be the same treatment as that required for the original diagnosis.

PREVENTION OF RECURRENCE

Good vulval care includes avoidance of irritants, keep diapers dry& use fragrance free detergents .Don't scrub ,but clean the vulva daily with water , stay away from the bubble bath& wipe from front to back, left the area get some air every day .Apply a lubricant like petroleum jelly to labia at night.

CONCLUSION

Labial adhesions or agglutination are a common event in pre pubertal girls. Their presence may warrant therapy if associated with pain or urinary symptoms. Topical estrogen is most common first line of treatment. Recurrence is possible, but rare after puberty.

REFERENCES

1. "NHS Direct Wales - Encyclopedia: Labial fusion". NHS Direct Wales. Retrieved 2011-09-1
2. Ludwig, Gary R. (2010). Textbook of Pediatric Emergency Medicine. Lippincott Williams & Wilkins. p. 84 ISBN 9781605471594J
3. Broecker, Jane E. D. (2008). "Imperforate hymen". The 5-minute Obstetrics and Gynecology Carolina School of Medicine, Columbia, Sc
4. Zitelli, Basil J.; McIntire, Sara C.; Nowalk, Andrew J. (2012). Zitelli and Davis' Atlas of Pediatric Physical Diagnosis .Elsevier. p. 580. ISBN 9780323091589.
5. Smith, Roger Perry (2008). Netter's Obstetrics and Gynecology. Elsevier. 202. ISBN 9781416056829.
6. Belman, A. Barry; King, Lowell R.; Kramer, Stephen A. (2001). Clinical Pediatric Urology. CRC,Press.pp. 219–220. ISBN 9781901865639
7. Creighton, Sarah (2005). "Pediatric and adolescent gynecology". Pediatric Surgery (2nd ed.). CRC,Press.,pp. 555–556. ISBN 9780340809105.
8. Baskin, Laurence; Swana, Hubert S. (2008). "Genito urinary Tumors". Clinical Problems in Pediatric Urology. John Wiley & Sons. pp. 175–176. ISBN 9781405171854.
9. Mayoglou, Lazarus; Dulabon, Lori; Martin-Alguacil, Nieves; Pfaff, Donald; Schober, Justine (August 2009). "Success of Treatment Modalities for Labial Fusion: A Retrospective Evaluation of Topical and Surgical Treatments". Journal of Pediatric and Adolescent Gynecology 22 (4): 247–250. doi:10.1016/j.jpag.2008.09.003.
10. Dr. Bacon, obstetrics and gynecology. Sout Consult. Lippincott Williams & Wilkins. pp. 122–123. ISBN 9780781769426